

## Topical Tazarotene 0.05% versus Glycolic Acid 70% Treatment in X-linked Ichthyosis due to Extensive Deletion of the *STS* Gene

Claudia Cotellessa<sup>1</sup>, Sergio A. Cuevas-Covarrubias<sup>2</sup>, Patrizia Valeri<sup>1</sup>, Maria Concetta Fagnoli<sup>1</sup> and Ketty Peris<sup>1\*</sup>

<sup>1</sup>Department of Dermatology, University of L'Aquila, L'Aquila, Via Vetoio, Coppito 2, IT-67100 L'Aquila, Italy and <sup>2</sup>Servicio de Genetica, Hospital General de Mexico, Facultad de Medicina, UNAM, Mexico DF, Mexico. \*E-mail: peris@univaq.it  
Accepted October 22, 2005.

Sir,

X-linked ichthyosis (XLI) appears in the immediate neonatal period as a generalized large, slightly adherent, lightly coloured desquamation commonly affecting the scalp, preauricular area and posterior neck (1). In time, large, often dark scales, preferentially located on the trunk and extensor aspect of the extremities, become prominent. The palms, soles and face are generally spared (1). Cutaneous histopathological findings of XLI are not diagnostic, being characterized by orthokeratotic hyperkeratosis and a normal or slightly thickened granular layer. In the dermis, oedema and a slight perivascular inflammatory infiltrate can be observed (1). The most common associated extracutaneous findings include corneal opacities, cryptorchidism, epilepsy and electro-encephalographic changes (1). XLI is caused by deficient activity of the steroid sulphatase (*STS*) enzyme due, in most patients, to complete or partial deletions of the *STS* gene mapped on Xp22.3 (2–5). Therapeutic approaches for the treatment of mild to moderate cutaneous manifestations of XLI include keratolytic agents, moisturizers and topical retinoids, while systemic retinoids have been successfully employed in severe forms (6, 7). We describe a 22-year-old man with XLI associated with epilepsy. A within-patient study comparing topical tazarotene 0.05% and glycolic acid 70%

resulted in almost complete remission of cutaneous lesions, although a longer response durability was achieved with tazarotene.

### CASE REPORT

A 22-year-old man presented with generalized, thick, tightly adherent, grey-brown scales on the neck, abdomen and extensor surface of the upper and lower extremities (Fig. 1A). Face, palms and soles as well as hair and nails were not involved. The patient was an only child and was born by caesarean section. Family history revealed that his mother had an abortion of a female fetus during the 32nd week of her second pregnancy, and one maternal aunt had epilepsy. Ichthyosis was neither disclosed in the proband's parents nor reported in any family member. Cutaneous scaling first occurred on the lower extremities during the second month of life and successively spread to the trunk and scalp. His psychomotor development was slightly retarded with walking at the age of 2, bradylalia (syn. bradylagia or bradyarthria = abnormal slowness or deliberation in speech) and low adaptive behaviour. However, he was a high-school graduate and never underwent standardized intelligence tests. Epilepsy developed at the age of 3 and was currently treated with carbamazepine and valproic acid. EEG showed diffuse abnormalities, mainly in the fronto-temporal area.

Laboratory investigations (blood cell count, protein electrophoresis, liver, kidney and thyroid functional tests, sexual and adrenal hormone serum levels, and urinalysis) were within normal limits. Lipoprotein electrophoresis showed an

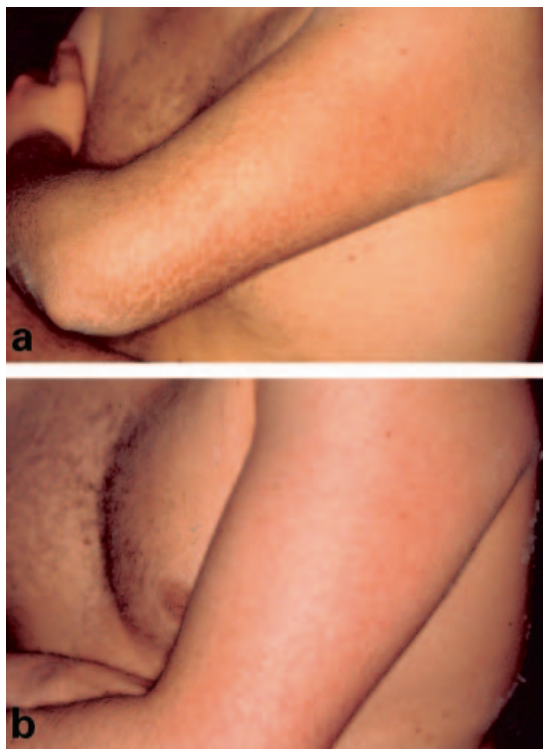


Fig. 1. (A) Thick, tightly adherent, grey-brown scales on the upper left arm before treatment and (B) after 2 weeks of tazarotene treatment.

increased electromobility rate of  $\beta$ -lipoprotein consistent with STS deficiency.

STS enzyme assay was performed in peripheral blood leukocytes as described previously (4), and showed undetectable levels of STS activity in our patient (0.00 pmol/mg protein per hour) as compared with a normal control. DNA extraction and PCR conditions to analyse the *STS* gene and contiguous 5' and 3' flanking markers (DXS89, DXS996, DXS1139, DXS1130, 5'*STS*-3'*STS*, DXS1131, DXS1133, DXS237, DXS1132, DXF22S1, DXS278 and DXS1134) were carried out as described previously (4). PCR analysis showed no amplification of the *STS* gene and of contiguous 5' flanking markers DXS1139, DXS1130 and 3' flanking markers DXS1131, DXS1133, DXS237 (Fig. 2). No alterations were found at exons 1 and 14 of the Kallman gene (data not shown), which is proximal to the *STS* gene.

A within-patient study comparing topical tazarotene 0.05% gel and glycolic acid 70% application was performed to determine efficacy and tolerability of each treatment, and response durability. Reduction of scaling and roughness as well as occurrence of any side effects were evaluated once weekly during treatment and once monthly after treatment discontinuation.

Tazarotene 0.05% gel was applied by the patient's mother once daily in the evening on the left arm, while glycolic acid 70% was applied by a dermatologist once weekly (because in Italy 70% glycolic acid must be applied by a physician) on the right arm for 10 weeks.

An  $\geq 80\%$  reduction of scaling and roughness was observed after 2 weeks of tazarotene treatment (Fig. 1B), and after two topical applications of glycolic acid with no further clinical improvement after an additional 8 weeks of treatment. Clinical benefit (not shown) of tazarotene was still noticed 8 weeks after treatment discontinuation. Side effects were limited to a

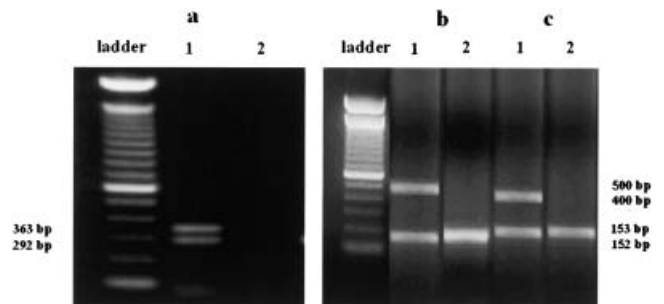


Fig. 2. PCR analysis of the *STS* gene and flanking markers DXS1139, DXS996, DXS237, and DXS1132. (A) Exons 1 and 10 (lower and upper band, respectively); (B) regions DXS1139 (500 bp) and DXS996 (153–171 bp) and (C) regions DXS1132 (152 bp) and DXS237 (400 bp). Lane 1, normal control; lane 2, patient with XLI and deletion of the *STS* gene and regions DXS1139 and DXS237.

slight erythema. Duration of clinical response lasted for 2 weeks after discontinuation of glycolic acid applications. Side effects were limited to a mild pruritus on the treated area immediately after the application.

## DISCUSSION

XLI is a relatively common disorder of keratinization with an estimated worldwide frequency of 1 in every 2000–6000 male births. In a recent study, the frequency of XLI was examined in a large representative sample of the Southern Italian male population and found to be 1.98 per 10,000 males (8).

A deficiency of STS activity in patients with XLI results in cholesterol sulphate accumulation, which in turn might alter the skin barrier function, increasing intercellular cohesion and reducing normal desquamation (9).

Complete deletions of the *STS* gene have been found in 90% of patients affected by XLI (3–5). Partial deletions or point mutations in the nucleotide sequence, which alter the enzymatic activity of STS, have been described in the remaining cases (10). In our patient, we detected an extensive deletion from DXS1139 to DXS237 that includes the *STS* gene and flanking regions. This represents the most common deletion pattern identified in patients with XLI. Specific extracutaneous disorders (e.g. short stature, mental retardation, condrodysplasia punctata and Kallmann's syndrome) have been associated with XLI depending on the length of deletion at the Xp22.3 region (11). The presence of exon 1 and exon 14 of the Kallman gene in our patient ruled out a contiguous gene syndrome. Prenatal molecular diagnosis recently demonstrated microdeletion of the *STS* gene by fluorescence in situ hybridization analysis of cultured amniotic fluid in a case of XLI (12).

A good clinical response to topical tazarotene 0.05% gel has been observed in patients affected by non-erythrodermic autosomal recessive ichthyosis (7). Glycolic acid at

high concentration is a keratolytic agent that induces reduction of corneocyte adhesion at the lower levels of the stratum corneum, and has been proposed for the treatment of cutaneous disorders characterized by abnormal keratinization such as lamellar ichthyosis and XLI (13, 14). In our patient, both tazarotene and glycolic acid led to an almost complete remission of cutaneous scaling but the former treatment resulted in a longer duration – 8 weeks versus 2 weeks – of clinical remission. The different mechanisms of action of the two drugs might explain our results: tazarotene activity might be related to its strong antiproliferative activity and modulation of differentiation on keratinocyte adhesion (15), while glycolic acid activity is essentially due to a reduction of corneocyte adhesion (13, 14). Further studies are needed to confirm the clinical benefit and response durability of tazarotene treatment in randomized controlled trials on patients with XLI.

## REFERENCES

- Hernandez-Martin A, Gonzales-Sarmiento R, Unamuno P. X-linked ichthyosis: an update. *Br J Dermatol* 1999; 141: 617–627.
- Shapiro LJ, Weiss R, Webster D, France JT. X-linked ichthyosis due to a steroid sulphatase deficiency. *Lancet* 1978; 14: 70–72.
- Ballabio A, Carrozzo R, Parenti G, Gil A, Zollo M, Persico MG, et al. Molecular heterogeneity of steroid sulfatase deficiency: a multicenter study on 57 unrelated patients, at DNA and protein levels. *Genomics* 1989; 4: 36–40.
- Jimenez Vaca AL, Valdes-Flores Mdel R, Rivera-Vega MR, Gonzalez-Huerta LM, Kofman-Alfaro SH, Cuevas-Covarrubias SA. Deletion pattern of the STS gene in X-linked ichthyosis in a Mexican population. *Mol Med* 2001; 7: 845–849.
- Saeki H, Kuwata S, Nakagawa H, Shimada S, Tamaki K, Ishibashi Y. Deletion pattern of the steroid sulphatase gene in Japanese patients with X-linked ichthyosis. *Br J Dermatol* 1998; 139: 96–98.
- Blanchet-Bardon CI, Nazarro V, Rognus C. Acitretin in the treatment of severe disorders of keratinization. Results of an open study. *J Am Acad Dermatol* 1991; 24: 982–986.
- Hoffmann B, Stege H, Ruzicka T, Lehmann P. Effect of topical tazarotene in the treatment of congenital ichthyoses. *Br J Dermatol* 1999; 141: 642–646.
- Ingordo V, D'Andria G, Gentile C, Decuzzi M, Mascia E, Naldi L. Frequency of X-linked ichthyosis in coastal southern Italy: a study on a representative sample of a young male population. *Dermatology* 2003; 207: 148–150.
- Zettersten E, Mao-Quang M, Sato J, Denda M, Farrell A, Ghadially R, et al. Recessive X-linked ichthyosis: role of cholesterol-sulphate accumulation in the barrier abnormality. *J Invest Dermatol* 1998; 111: 784–790.
- Morita E, Katoh O, Shinoda S, Hiragun T, Tanaka T, Kameyoshi Y, et al. A novel point mutation in the steroid sulfatase gene in X-linked ichthyosis. *J Invest Dermatol* 1997; 109: 244–245.
- Ballabio A, Bardoni B, Carrozzo R, Andria G, Bick D, Campbell L, et al. Contiguous gene syndromes due to deletions in the distal short arm of the human X chromosome. *Proc Natl Acad Sci* 1989; 86: 10001–10005.
- Watanabe T, Fujimori K, Kato K, Nomura Y, Onogi S, Sato A. Prenatal diagnosis for placental steroid sulfatase deficiency with fluorescence in situ hybridization: a case of X-linked ichthyosis. *J Obstet Gynaecol Res* 2003; 29: 427–430.
- Van Scott EJ, Yu RJ. Hyperkeratinization, corneocyte cohesion and alpha hydroxy acids. *J Am Acad Dermatol* 1984; 11: 867–879.
- Di Nardo J, Grove GL, Moy LS. Clinical and histological effects of glycolic acid at different concentrations and pH levels. *Dermatol Surg* 1996; 22: 421–424.
- Duvic M, Helekar B, Schulz C, Cho M, DiSepio D, Hager C, et al. Expression of a retinoid-inducible tumor suppressor, tazarotene-inducible gene-3, is decreased in psoriasis and skin cancer. *Clin Cancer Res* 2000; 6: 3249–3259.