

CLINICAL REPORT

Paraneoplastic Pemphigus Associated with Non-Hodgkin B-Cell Lymphoma and Good Response to Prednisone

María Isabel MARTÍNEZ DE PABLO¹, Pilar IRANZO¹, José Manuel MASCARÓ¹, Alex LLAMBRICH¹, Manel BARADAD² and Carmen HERRERO¹

¹Department of Dermatology, Clinic Hospital, University of Barcelona, IDIBAPS, Barcelona, and ²Department of Dermatology, Arnau de Vilanova Hospital, Lleida, Spain

Paraneoplastic pemphigus is a life-threatening auto-immune bullous disease associated with neoplasia, generally of lymphoid origin. Immunosuppressive therapy is often disappointing and there are only a few reports of patients surviving more than 2 years. These cases were generally associated with benign neoplasms. We report here the case of a patient with paraneoplastic pemphigus associated with non-Hodgkin B-cell lymphoma who had a surprisingly good response to systemic corticosteroids and remains free of lesions more than 3 years later despite progression of her neoplasm. Key words: lymphoma; bullous disease; paraneoplastic; therapy.

(Accepted September 27, 2004.)

Acta Derm Venereol 2005; 85: 233–235.

M.I. Martínez De Pablo, Servicio de Dermatología, Hospital Clínic, C/ Villarroel 170, ES-08036 Barcelona, Spain. E-mail: 34199mmd@comb.es

Paraneoplastic pemphigus (PNP) was first described in 1990 by Anhalt et al. (1) as a mucocutaneous auto-immune syndrome associated with neoplasms, mostly of lymphoproliferative origin.

Original diagnostic criteria for PNP included clinical and histological criteria (2), direct and indirect immunofluorescence findings (3, 4) and, finally, immunochemical data, i.e. detection of autoantibodies recognizing a group of epidermal antigens by immunoprecipitation (5–7). Currently, the latter criterion is the gold standard for diagnosis but all these criteria must be present in the context of an underlying neoplasm. Most neoplasms are of lymphoid origin, and 80% of cases are associated with non-Hodgkin lymphoma (NHL), chronic lymphocytic leukaemia or Castleman's tumour. Thymomas (8), carcinomas (9) and sarcomas (10) have also been reported. Frequent neoplasms such as adenocarcinomas of the breast or the bowel have rarely (11) been reported in association with this paraneoplastic syndrome.

Pathophysiological mechanisms of PNP are still unclear. Different antigens of the plakine protein family seem to be involved. Both humoral and cellular autoimmunity seem to play a role in its development, and it has been hypothesized that they are generated through a mechanism of antitumour response (12). IgG

autoantibodies have been found not only on the skin but also within the bronchial epithelium, conjunctiva, oesophagus, urinary bladder, renal glomeruli and muscle (12). Bronchiolitis obliterans causing respiratory failure, which seems to be secondary to autoantibody deposition, is a frequent complication leading to death (13). However, overt disease involving other locations has not been encountered, suggesting that autoantibodies do not necessarily mediate the pathological process directly; they may serve as a serological marker of disease instead. Recently, HLA DRB1*03 has been reported to be more prevalent in patients with PNP than in healthy controls or patients with pemphigus vulgaris (14). That finding suggests that the allele may confer susceptibility to the disease.

The clinical course of PNP is characterized by disease progression despite aggressive immunosuppressive therapies. Prognosis is poor and most patients die within 2 years of diagnosis.

CASE REPORT

In 1996, a 70-year-old white woman was diagnosed with follicular B-cell NHL with multiganglionic and bone marrow invasion (stage IV-a). Complete remission was achieved after eight cycles of chemotherapy with cyclophosphamide, adriamycin, vincristine and prednisolone. In 1998, the neoplasm relapsed, and therapy with oral chlorambucil was introduced. In September 2000, with partial remission of the lymphoma, she developed bulbar conjunctival injection and oral and pharyngeal painful erosions with haemorrhagic crusting of the lips (Fig. 1), followed by an eruption of tense blisters on the upper trunk and extremities that also involved the palms and soles (Fig. 2). The Nikolsky sign was negative.

One month later she was admitted to our hospital. Routine laboratory studies showed an abnormal level of liver enzymes, normocytic anaemia and thrombopenia. Histological examination showed an intra-epidermal suprabasal blister with acantholysis. Direct immunofluorescence (DIF) of perilesional unaffected skin revealed intercellular epidermal deposits of IgG and C₃, and granular deposits of IgG along the basement membrane zone. Indirect immunofluorescence (IIF)

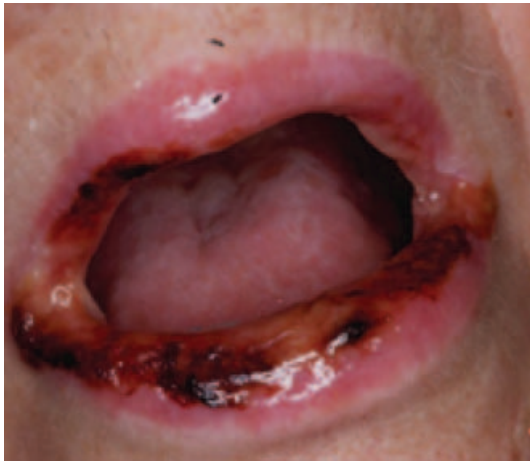

Fig. 1. Oral erosions at time of diagnosis.

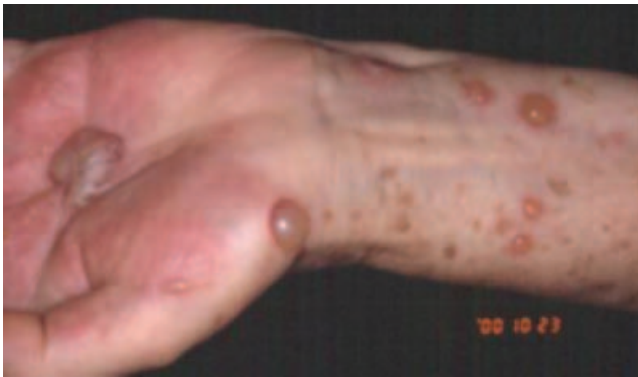

Fig. 2. Tense blisters on palms and forearms.

testing with serum and fluid blister using monkey oesophagus demonstrated circulating IgG antibodies that bound uniformly throughout the squamous epithelium (in a cytoplasmic pattern) interfering with cell surface antibody reactions. IIF with human salt-split skin demonstrated IgG binding to the whole epidermis (cytoplasmic pattern) and the basement membrane zone (Fig. 3). IIF on rat bladder epithelium was also positive (Fig. 4). Immunoprecipitation studies (performed in

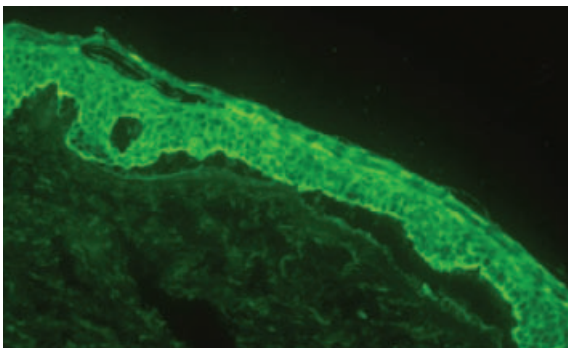


Fig. 3. Indirect immunofluorescence on salt-split skin. IgG autoantibodies in a cytoplasmic pattern and on the basement membrane zone.

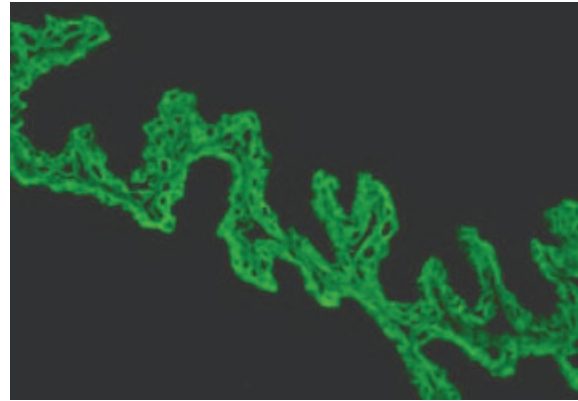


Fig. 4. IgG binding to transitional epithelium of rat bladder.

G.J. Anhalt's laboratory in the USA) revealed that the patient serum reacted with the 210-kd band (envoplakin) and the 190-kd band (periplakin). Her HLA was A*33, B14, BW6, DR*01, DR*04. All these findings were diagnostic of PNP.

Pancytopenia was attributed to bone marrow toxicity by chlorambucil, and it was then suppressed. Treatment was started with prednisone at a dose of 1 mg kg⁻¹ daily. A progressive improvement was achieved: no new cutaneous blisters appeared and there was a slow healing of her stomatitis. Two months after diagnosis her cutaneous lesions had completely cleared while the oral erosions persisted during the next 8 months. Prednisone was slowly tapered and finally stopped. In December 2001 her lymphoma relapsed in the form of a laterocervical mass. Histopathology of the mass showed a marginal lymphoma with areas of transformation into large-cell NHL. Palliative treatment with prednisone and cyclophosphamide was established. Forty months after the initial diagnosis the patient is free of cutaneous and mucosal lesions, while repeated DIF and IIF examinations have been negative, despite progression of her neoplasm.

DISCUSSION

Prognosis of PNP depends upon the associated neoplastic process. With few exceptions, PNP in patients with malignant neoplasms has generally proved to be fatal, with no relation between the course of the mucocutaneous syndrome and tumour activity. Mortality is frequently the result of a complication of immunosuppression (infections) (15) or gastrointestinal bleeding due to high dose of corticosteroids. Bronchiolitis obliterans is the third cause of death (16). Mean survival rate of the original group of cases reported by Anhalt was 9 months (with a maximum of 24 months). Since then, several cases of relatively good responses to combinations of prednisone with azathioprine (15) or with cyclosporine (17) and to high-dose cyclophosphamide (18) have been published. Most were cases of chronic

lymphocytic leukaemia and all were under a maintenance dose of the immunosuppressive therapy during the course of their illness. Heinzmann et al. (19) described a patient with NHL who achieved a partial remission of the neoplasm with rituximab, associated with a complete clearance of the mucocutaneous lesions for at least 1 year. There is only one report describing a good response to steroid treatment exclusively. This was a young patient with Hodgkin's disease in remission when PNP was diagnosed and without mucosal involvement (20). Prednisone at an initial dose of 1 mg kg⁻¹ day⁻¹ was able to clear the lesions in 2 weeks. Eighteen months later the patient was asymptomatic on a dose of 5 mg day⁻¹.

These reports point to the existence of a subgroup of patients with a less aggressive form of PNP. Recently, Beutner et al. (21) suggested that a complement IIF test could help to differentiate fatal from 'benign' PNP cases, but more data are needed to confirm these findings.

To our knowledge this is the first case of PNP associated with many factors of poor prognosis (age, NHL and tumoral stage) with a complete response to monotherapy with steroids. Actually her mucocutaneous illness is in total remission with no maintenance therapy, despite tumour progression.

ACKNOWLEDGEMENTS

This work was partially supported by a grant-in-aid for scientific research from the Clinic Hospital of Barcelona (Grant Emili Letang 2003).

REFERENCES

- Anhalt GJ, Kim SC, Stanley JR, Korman NJ, Jabs DA, Kory M, et al. Paraneoplastic pemphigus: an autoimmune mucocutaneous disease associated with neoplasia. *N Engl J Med* 1990; 323: 1729–1735.
- Horn TD, Anhalt GJ. Histologic features of paraneoplastic pemphigus. *Arch Dermatol* 1991; 128: 1091–1095.
- Liu AY, Valenzuela R, Helm TN, Camisa C, Melton AL, Bergfeld WF. Indirect immunofluorescence on rat bladder transitional epithelium: a test with high specificity for paraneoplastic pemphigus. *J Am Acad Dermatol* 1993; 28: 696–699.
- Helou J, Allbritton J, Anhalt GJ. Accuracy of indirect immunofluorescence testing in the diagnosis of paraneoplastic pemphigus. *J Am Acad Dermatol* 1995; 32: 441–447.
- Joly P, Richard C, Gilbert D, Courville P, Chosidow O, Roujeau JC, et al. Sensitivity and specificity of clinical, histologic, and immunologic features in the diagnosis of paraneoplastic pemphigus. *J Am Acad Dermatol* 2000; 43: 619–626.
- Mahoney MG, Aho S, Uitto J, Stanley JR. The members of the plakins family of proteins recognized by paraneoplastic pemphigus antibodies include periplakin. *J Invest Dermatol* 1998; 111: 308–313.
- Hashimoto T, Amagai M, Watanabe K, Chorzelski TP, Bhogal BS, Black MM, et al. Characterization of paraneoplastic pemphigus autoantigens by immunoblot analysis. *J Invest Dermatol* 1995; 104: 829–834.
- Chiewchanvit S, Hashimoto T, Chaiwun B, Nishikawa T. A pemphigus case with long-term survival, implicating the spectrum between paraneoplastic pemphigus and pemphigus vulgaris. *Int J Dermatol* 1997; 36: 957–958.
- Lam S, Stone MS, Goeken JA. Paraneoplastic pemphigus, cicatricial conjunctivitis, and acanthosis nigricans with pachydermatodactyly in a patient with bronchogenic squamous cell carcinoma. *Ophthalmology* 1992; 20: 1001–1004.
- Krunic AL, Kokai D, Bacetic B, Kesik V, Nickolic MM, Petkovic S, et al. Retroperitoneal round-cell liposarcoma associated with paraneoplastic pemphigus presenting as lichen planus pemphigoides-like eruption. *Int J Dermatol* 1997; 36: 526–529.
- Bowen GM, Peters NT, Fivenson DP, Su LD, Noussari HC, Anhalt GJ, et al. Lichenoid dermatitis in paraneoplastic pemphigus. A pathogenic trigger of epitope spreading? *Arch Dermatol* 2000; 136: 652–656.
- Nguyen VT, Ndoye A, Bassler KD, Shultz LD, Shields MC, Ruben BS, et al. Classification, clinical manifestations, and immunopathological mechanisms of the epithelial variant of paraneoplastic autoimmune multiorgan syndrome. *Arch Dermatol* 2001; 137: 193–207.
- Sun H, Wang R, Bin H, Wang Y, Jiang X, Na J, et al. Localized Castleman disease with paraneoplastic pemphigus and pulmonary involvement: clinical features and histopathology. *Nat Med J China* 2002; 82: 530.
- Martel P, Loiseau P, Joly P, Busson M, Lepage V, Mouquet H, et al. Paraneoplastic pemphigus is associated with the DRB1*03 allele. *J Autoimmunity* 2003; 20: 91–95.
- Camisa C, Helm TN, Liu YC, Valenzuela R, Allen C, Bona S, et al. Paraneoplastic pemphigus: a report of three cases including one long-term survivor. *J Am Acad Dermatol* 1992; 27: 547–553.
- Noussari HC, Deterding R, Wojtczak H, Aho S, Uitto J, Hashimoto T, et al. The mechanism of respiratory failure in paraneoplastic pemphigus. *N Engl J Med* 1999; 340: 1406–1411.
- Perniciaro C, Kuechle MK, Colón-Otero G, Raymond MG, Spear KL, Pittelkow MR. Paraneoplastic pemphigus: a case of prolonged survival. *Mayo Clin Proc* 1994; 69: 851–855.
- Noussari HC, Brodsky RA, Jones RJ, Grever MR, Anhalt GJ. Immunoablative high-dose cyclophosphamide without stem cell rescue in paraneoplastic pemphigus: report of a case and review of this new therapy for severe autoimmune disease. *J Am Acad Dermatol* 1999; 40: 750–754.
- Heinzmann M, Itin P, Wernli M, Borradori L, Bargetzi MJ. Successful treatment of paraneoplastic pemphigus in follicular NHL with rituximab: report of a case and review of treatment for paraneoplastic pemphigus in NHL and CLL. *Am J Hematol* 2001; 66: 142–144.
- Dega H, Laporte JL, Joly P, Gabarre J, André C. Paraneoplastic pemphigus associated with Hodgkins disease. *Br J Dermatol* 1998; 138: 196–198.
- Beutner EH, Pelton S, Hashimoto T, Xu Y, Plunkett RW, Korman NJ, et al. A nonfatal case and 2 fatal cases of paraneoplastic pemphigus: can complement indirect immunofluorescent test help to identify fatal "group A" paraneoplastic pemphigus cases? *J Am Acad Dermatol* 2002; 47: 841–851.