

CLINICAL REPORT

Frequency of IgA Antibodies in Pemphigus, Bullous Pemphigoid and Mucous Membrane Pemphigoid

Emanuele COZZANI¹, Massimo DROSERA¹, Aurora PARODI¹, Marco CARROZZO², Sergio GANDOLFO² and Alfredo REBORA¹

¹*Di.S.E.M. Section of Dermatology, University of Genoa, Genoa and* ²*Department of Biomedical Sciences and Human Oncology Oral Medicine Section, University of Turin, Turin, Italy*

Circulating and bound IgA antibodies can be found in the autoimmune blistering diseases, but their prevalence, clinical relevance and target antigens remain unknown. Thirty-two patients with pemphigus, 73 with bullous pemphigoid and 28 with mucous membrane pemphigoid were studied retrospectively. Direct immunofluorescence (DIF) analysis of IgG, IgA, IgM and C3 was carried out for all cases. Sera were studied by standard indirect immunofluorescence, indirect immunofluorescence on salt-split skin, immunoblotting for bullous pemphigoid and mucous membrane pemphigoid and ELISA for pemphigus. With DIF, we found IgA autoantibodies in 22 of all 133 cases. Circulating IgA antibodies to skin were detected in 2 of 3 IgA-DIF-positive patients with pemphigus, in 3 of 6 with bullous pemphigoid, and in 6 of 13 with mucous membrane pemphigoid. We confirm that the IgA reactivity is more frequently associated with mucous membrane involvement, especially in cases without critical involvement (5/8). The role of IgA and its antigenic specificity in these diseases remain unclear. *Key words: IgA; pemphigus; bullous pemphigoid; mucous membrane pemphigoid.*

(Accepted February 23, 2004.)

Acta Derm Venereol 2004; 84: 381–384.

Aurora Parodi, MD, Clinica Dermatologica, Viale Benedetto XV, IT-716132 Genova, Italy. E-mail: aurora.parodi@unige.it

Pemphigus, bullous pemphigoid (BP) and mucous membrane pemphigoid (MMP) are characterized by the presence of pathogenic autoantibodies of IgG class binding to different target antigens (1). Recently, however, cases of these diseases have been described in which direct immunofluorescence (DIF) revealed deposits of IgA antibodies. In other cases, IgA antibodies were found to circulate together with IgG (2–11); however, their prevalence and clinical relevance as well as their target antigens in the autoimmune blistering diseases are unknown.

The aim of our study was to evaluate the presence and specificity of circulating and bound IgA antibodies

in all cases of pemphigus, BP and MMP seen in our department.

MATERIALS AND METHODS

One hundred and thirty-three patients with autoimmune bullous diseases diagnosed in our department between 1995 and 2002 were studied retrospectively. They included 32 patients with pemphigus, 73 with BP and 28 with MMP. The diagnosis had been made using standard clinical, histological and immunofluorescence criteria. We diagnosed as MMP cases with mucosal lesions characterized by a subepithelial cleavage with deposit of immunoglobulins and complement along the basement membrane zone (BMZ) (12). In some cases, the lesions healed with a scar, diagnosed as cicatricial MMP (cMMP). Cases of pure IgA pemphigus, IgA linear dermatitis and dermatitis herpetiformis were not considered in this study.

In all cases, we repeated the previous DIFs by using antisera against IgG, IgA, IgM and C3.

The sera of patients were recovered from storage at -20°C and studied by standard indirect immunofluorescence (IIF), indirect immunofluorescence on salt-split skin (IIF-SSS) and immunoblotting for BP and MMP. ELISA was also used for pemphigus sera.

Direct immunofluorescence

Cryostat sections (6 μm thick) from perilesional skin were incubated with fluorescein isothiocyanate (FITC)-labelled anti-human IgG, IgA, IgM and C3 goat serum (Kallestad Diagnostics, Chaska MN, USA). FITC alone was used as control.

Indirect immunofluorescence

All sera were diluted 1:20 in PBS buffer and overlaid for 30 min on the appropriate substrate. The slides were then washed in PBS buffer for 30 min. FITC-conjugated goat anti-human IgG and IgA were used as the second step antibody.

Salt-split skin procedure

Normal human skin was obtained from mammoplasty surgery. Epidermis was split from dermis according to the standard technique (13).

Normal human skin, salt-split human skin and monkey oesophagus were used as substrates.

Immunoblotting

Immunoblotting was performed with epidermal proteins obtained from normal human keratinocyte cultures (14).

The epidermal proteins were extracted according to the standard technique (15). Epidermal proteins were separated by 6% SDS-polyacrylamide slab mini-gel electrophoresis under reducing conditions and transferred to nitrocellulose filters as described previously (15). Nitrocellulose strips were then sequentially incubated with: (I) 1:100 dilution of each serum sample in TBS/milk for 18 h at room temperature; (II) biotinylated rabbit anti-human IgG (Dako, Glostrup, Denmark) and goat anti-human IgA (Vector Burlingame, CA) used at dilutions of 1/500 and 1/200, respectively, in-TBS/milk for 30 min at room temperature; (III) 1:3000 dilution of streptavidin-alkaline phosphatase complexes (Dako) in TBS/milk for 30 min at room temperature. The strips were finally developed with 5-bromo-4-chloro-3-indolyl phosphate/nitroblue tetrazolium (BCIP/NBT)-buffered substrate tablets (Roche, Mannheim, Germany). Intervening washes were performed using 0.1% TBS-Tween 20.

ELISA

We used a commercial ELISA kit for the diagnosis of pemphigus consisting of microwells coated with recombinant proteins encompassing the ectodomain of either desmoglein (Dsg) 1 or Dsg 3 (MBL, Naka-Ku Nagoya, Japan).

To compare the results from different plates, the test sample optical densities (OD) were adjusted according to positive and negative control samples supplied in each kit. The final results were expressed as a percentage according to the following calculation:

$$\text{ELISA result} = \frac{(\text{OD sample} - \text{OD negative control})}{(\text{OD positive control} - \text{OD negative control})} \times 100$$

The IgA cut-off value for both Dsg1 and Dsg3 was 7. The IgG cut-off value for Dsg3 was 7 and 14 for Dsg1.

RESULTS

Three of the 32 patients with pemphigus (9.3%) (Table I) exhibited, in addition to IgG, an IgA deposit on the keratinocyte surface at DIF. With IIF on monkey oesophagus, only one patient had circulating IgA antibodies, but at lower titre than IgG. With immunoblotting, two sera showed IgA antibodies directed to Dsg, one to both Dsg1 and 3 and the other to Dsg1 only. In the first case, the IgA was associated with IgG to Dsg 3. With ELISA, two cases showed IgA antibodies directed to Dsg 1 that were associated with IgG; the IgA titres were 15.3 and 11.6, respectively.

With DIF, 6 of the 73 patients with BP (8.3%) (Table II) and 13 of the 28 (46%) patients with MMP or cMMP showed linear IgA deposits at the BMZ (Fig. 1). In all cases, IgA was associated with IgG deposits.

With IIF on monkey oesophagus, one of the 6 DIF-positive patients with BP and none of the 13 DIF-positive patients with MMP/cMMP had circulating IgA antibodies. On the contrary, with IIF on salt-split skin, one BP, two MMP and one cMMP sera had circulating IgA anti-BMZ antibodies, all binding the epidermal side of the split skin. IgA was associated with IgG in only two cases.

With immunoblotting, three of the DIF-positive BP sera had circulating IgA antibodies that recognized BP antigens. In particular, two sera had IgA reacting with the 230-kDa BP antigen (BPag1) and one serum

Table I. Direct and indirect immunofluorescence (DIF, IIF), immunoblotting and ELISA results in IgA-DIF-positive pemphigus patients

Patients' sex/age	Clinical diagnosis	DIF intercellular deposits	IIF		Immunoblotting		ELISA	
			IgG	IgA	IgG	IgA	IgG	IgA
M/42	PV	IgG, IgA, IgM, C3	1/160	1/20	Dsg3	Dsg1/3	Dsg1/3	Dsg1
F/75	PF	IgG, IgA, C3	1/160	Negative	Dsg1	neg	Dsg1	neg
M/62	PF	IgG, IgA, IgM, C3	1/40	Negative	neg	Dsg1	Dsg1	Dsg1

Dsg, desmoglein; PV, pemphigus vulgaris; PF, pemphigus foliaceus.

Table II. Direct and indirect immunofluorescence (DIF, IIF), immunoblotting and ELISA data for six patients with bullous pemphigoid positive for IgA on DIF

Patients' sex/age	DIF linear deposits	IIF		IIF-SSS		Immunoblotting	
		IgG	IgA	IgG	IgA	IgG	IgA
F/70	IgG, IgA, C3	1/80	Negative	Roof	Negative	Negative	230
F/84	IgG, IgA, C3	Negative	Negative	Roof	Negative	180	230-180
M/89	IgG, IgA, C3	Negative	Negative	Roof	Negative	Negative	Negative
M/71	IgG, IgA, C3	1/40	1/20	Roof	Negative	Negative	Negative
F/82	IgG, IgA, C3	1/40	Negative	Roof	Roof	Negative	230
M/76	IgG, IgA	1/40	Negative	Roof	Negative	180	Negative

SSS, salt-split skin.

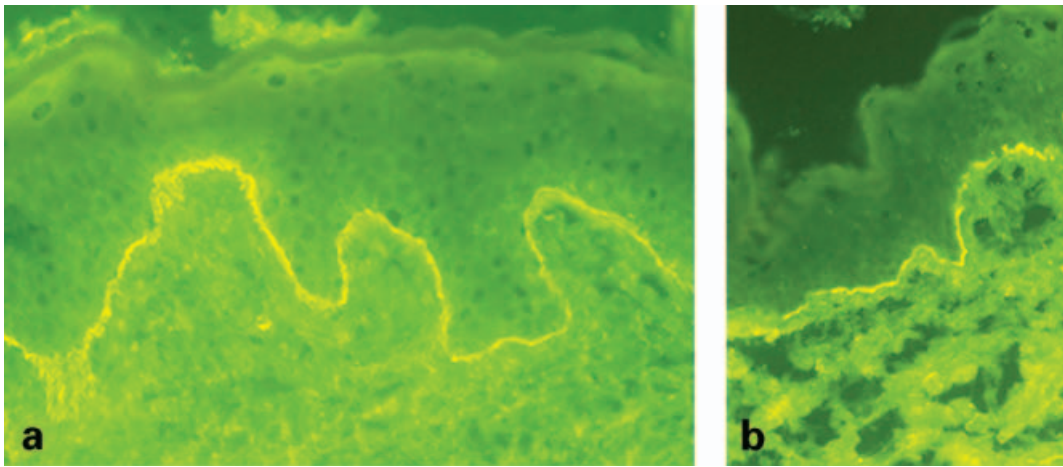


Fig. 1. Direct immunofluorescence in a patient with bullous pemphigoid: (a) deposit of IgG at basal membrane zone (BMZ); (b) deposit of IgA at BMZ.

reacted with both the BPAg1 and 180-kDa BP antigen (BPAg2). Only in the latter case were the circulating IgG and IgA antibodies directed to the BPAg2.

One MMP serum had circulating IgA directed to BPAg1, one to BPAg2 and one to both BPAg1 and BPAg2. The latter also had IgG directed to both antigens. One patient with cMMP had IgA directed to both BPAg1 and BPAg2.

DISCUSSION

With DIF, we found IgA autoantibodies in 22 of our 133 cases with bullous diseases. Circulating IgA was detected in 2 of 3 IgA-DIF-positive patients with pemphigus, in 3 of 6 patients with BP, and in as many as 6 of 13 patients with cMMP or MMP. This high prevalence of circulating IgA is due to the fact that we detected the antibodies by associating different serological laboratory methods with higher sensitivity than standard IIF, i.e. IIF on salt-split skin, immunoblotting and ELISA.

In the literature, a few cases of pemphigus with IgA antibodies associated with IgG have been reported previously. They have been called IgG/IgA pemphigus and were related to lung cancer in one case (6), and to IgA gammopathy in another (7). None of our cases suffered from monoclonal gammopathy or from any internal malignancy.

In 35 cases of BP, Kirtschig & Wojnarowska (9) determined the presence of circulating IgA anti-BMZ antibodies by IIF using salt-split human skin as substrate. Most of them recognized BPAg1 and/or BPAg2, but also reacted with an epidermal protein (270–280 kDa) that was not further characterized. This is not our experience as our positive sera recognized only BPAg1 and BPAg2.

In MMP, IgA antibodies have been found to react with a number of antigens, some of which proved to be different from those recognized by IgG (16–18). In

addition, a 45-kDa keratin, which was recognized only by IgA antibodies, was described in ocular cicatricial pemphigoid (17).

The high prevalence of IgA antibodies in MMP sera has already been observed by Setterfield et al. (10). In their study of 67 patients with MMP, they found circulating IgA in 61.2%, in all cases binding the roof of the salt-split skin. Moreover, these patients had a more severe and persistent disease than those lacking IgA autoantibodies. Unlike Setterfield et al., we failed to confirm the importance of IgA antibodies as a prognostic indicator. Furthermore, the IgA antibodies in our MMP patients were directed to BPAg1 alone. We can only confirm that IgA reactivity is significantly more frequently associated with mucous membrane involvement (19, 20) than to ordinary BP and that it is more frequent in cases of MMP (5/8) than in cases of cMMP (1/5).

The antigenic specificity of IgA in pemphigus, BP and MMP is not clearly understood and whether or not IgA plays a pathogenetic role remains unclear. Speculatively, IgA could recognize different epitopes to IgG, possibly via epitope spreading (21), and might be responsible for the persistence of the inflammatory process.

REFERENCES

1. Scully C, Carrozzo M, Gandolfo S, Puiatti P, Monteil R. Update on mucous membrane pemphigoid, a heterogeneous immune-mediated sub-epithelial blistering entity. *Oral Surg Oral Med Oral Pathol Oral Radiol End* 1999; 88: 56–68.
2. Bhol KC, Colon JE, Ahmed AR. Autoantibody in mucous membrane pemphigoid binds to a human beta4 integrin and causes basement membrane zone separation in oral mucosa in an organ culture model. *J Invest Dermatol* 2003; 120: 701–702.
3. Spaeth S, Riechers R, Borradori L, Zillikens D, Budinger L, Hertl M. IgG, IgA and IgE autoantibodies against the ectodomain of desmoglein 3 in active

- pemphigus vulgaris. *Br J Dermatol* 2001; 144: 1183–1188.
4. Oiso N, Yamashita C, Yoshioka K, Amagai M, Komai A, Nagata Y, et al. IgG/IgA pemphigus with IgG and IgA antidesmoglein 1 antibodies detected by enzyme-linked immunosorbent assay. *Br J Dermatol* 2002; 147: 1012–1017.
 5. Hashimoto T, Ebihara T, Nishikawa T. Studies of autoantigens recognized by IgA anti-keratinocyte cell surface antibodies. *J Dermatol Sci* 1996; 12: 10–17.
 6. Chorzelski TP, Hashimoto T, Nishikawa T, Ebihara T, Dmochowski M, Ismail M, et al. Unusual acantholytic bullous dermatosis associated with neoplasia and IgG and IgA antibodies against bovine desmocollins I and II. *J Am Acad Dermatol* 1994; 31: 351–355.
 7. Miyagawa S, Hashimoto T, Ohno H, Nakagawa A, Watanabe K, Nishikawa T, et al. Atypical pemphigus associated with monoclonal IgA gammopathy. *J Am Acad Dermatol* 1995; 32: 352–357.
 8. Gooptu C, Mendelsohn S, Amagai M, Hashimoto T, Nishikawa T, Wojnarowska F. Unique immunobullous disease in a child with a predominantly IgA response to three desmosomal proteins. *Br J Dermatol* 1999; 141: 882–886.
 9. Kirtschig G, Wojnarowska F. IgA basement membrane zone autoantibodies in bullous pemphigoid detect epidermal antigens of 270–280 kDa, 230 kDa, and 180 kDa molecular weight by immunoblotting. *Clin Exp Dermatol* 1999; 24: 302–307.
 10. Setterfield J, Shirlaw PJ, Kerr-Muir M, Neill S, Bhogal BS, Morgan P, et al. Mucous membrane pemphigoid: a dual circulating antibody response with IgG and IgA signifies a more severe and persistent disease. *Br J Dermatol* 1998; 138: 602–610.
 11. Murakami H, Nishioka S, Setterfield J, Bhogal BS, Black MM, Zillikens D, et al. Analysis of antigens targeted by circulating IgG and IgA autoantibodies in 50 patients with cicatricial pemphigoid. *J Dermatol Sci* 1998; 17: 39–44.
 12. Carrozzo M, Fasano ME, Broccoletti R, Carbone M, Cozzani E, Rendine S, et al. HLA-DQB1 alleles in Italian patients with mucous membrane pemphigoid predominantly affecting the oral cavity. *Br J Dermatol* 2001; 145: 805–808.
 13. Gammon WR, Briggaman RA, Inman AO, Queen LL, Wheeler CE. Differentiating anti-lamina lucida and anti-sublamina densa anti-BMZ antibodies by indirect immunofluorescence on 1.0 M sodium chloride-separated skin. *J Invest Dermatol* 1984; 82: 139–144.
 14. Laemmli UK. Cleavage of structural proteins during the assembly of the head of bacteriophage T4. *Nature* 1970; 227: 680–685.
 15. Cozzani E, Kanitakis J, Nicolas JF, Schmitt D, Thivolet J. Comparative study of indirect immunofluorescence and immunoblotting for the diagnosis of autoimmune pemphigus. *Arch Dermatol Res* 1994; 286: 295–299.
 16. Sarret Y, Hall R, Cobo LM, Thivolet J, Patton DL, Woodley DT. Salt-split human skin substrate for the immunofluorescent screening of serum from patients with cicatricial pemphigoid and a new method of immunoprecipitation with IgA antibodies. *J Am Acad Dermatol* 1991; 24: 952–958.
 17. Smith EP, Taylor TB, Meyer LJ, Zone JJ. Identification of a basement membrane zone antigen reactive with circulating IgA antibody in ocular cicatricial pemphigoid. *J Invest Dermatol* 1993; 101: 619–623.
 18. Chan LS, Hammerberg C, Cooper KD. Cicatricial pemphigoid. Identification of two distinct sets of epidermal antigens by IgA and IgG class circulating autoantibodies. *Arch Dermatol* 1990; 126: 1466–1468.
 19. Egan CA, Taylor TB, Meyer LJ, Petersen MJ, Zone JJ. The immunoglobulin A antibody response in clinical subsets of mucous membrane pemphigoid. *Dermatology* 1999; 198: 330–335.
 20. Christophoridis S, Budinger L, Borradori L, Hunziker T, Merk HF, Hertl M. IgG, IgA and IgE autoantibodies against the ectodomain of BP180 in patients with bullous and cicatricial pemphigoid and linear IgA bullous dermatosis. *Br J Dermatol* 2000; 143: 349–355.
 21. Vanderlugt CJ, Miller SD. Epitope spreading. *Curr Opin Immunol* 1996; 8: 831–836.