

D-Penicillamine-induced Pemphigus Vulgaris in a Patient with Scleroderma-Rheumatoid Arthritis Overlap Syndrome

Andrea Szegedi¹, Péter Surányi², Gabriella Szücs³, Mária Kiss⁴, János Hunyadi¹ and János Gaál^{2*}

¹Department of Dermatology, Medical and Health Science Center, University of Debrecen, ²Department of Rheumatology, Kenézy Gyula Hospital, Bartók B. str. 2-26, HU-4043 Debrecen, ³3rd Department of Internal Medicine Medical and Health Science Center, University of Debrecen, Debrecen and ⁴Department of Dermatology, University of Szeged, Szeged, Hungary.

*E-mail: gaalja@freemail.hu

Accepted January 9, 2004.

Sir,

Pemphigus vulgaris (PV) developing in conjunction with D-penicillamine treatment is a rare disorder; to date the number of described cases is about 100 (1). Most reports of D-penicillamine-induced PV are in patients with rheumatoid arthritis (RA) (2), but there are no data in the medical literature about this complication in systemic sclerosis-rheumatoid arthritis SSc-RA overlap syndrome. We here report a case of D-penicillamine-induced PV in a patient with SSc-RA overlap syndrome. Discontinuation of the offending agent and a high dose of methylprednisolone were required to terminate the disease flare.

CASE REPORT

A 62-year-old white woman had a 10-year history of symmetrical polyarthritis, with morning stiffness lasting more than an hour. In November 2000 she was referred to the dermatology unit with typical diffuse cutaneous sclerosis, bilateral swollen and tender wrists, metacarpophalangeal, proximal interphalangeal and ankle joints, eye and oral dryness, and a sensation of foreign body in her eyes. Abnormal Schirmer's (4 mm/5 min), rose Bengal tests and decreased non-stimulated salivary gland excretion (0.1 ml/15 min) were found. The laboratory examinations showed increased ESR (120 mm/1st h), hypergammaglobulinaemia (20.71 g/l) and raised CRP level (16.5 ml/l). All other laboratory parameters, including haematology and biochemistry, were normal. The immunoserology showed granular ANA positivity in the HEp-2 cell line and rheumatoid factor positivity, while autoantibody screening was negative for ENA, Sm/RNP, SSA, SSB and Scl-70 (topoisomerase I). She underwent extensive examinations, the results of which did not show any internal organ involvement or erosions in the small joints. Multiple blood, stool and urine cultures and serological investigations for known viruses were negative. The diagnosis of Sjögren syndrome secondary to SSc was made; saliva and tear supplementation, ACE inhibitor, colchicine, pentoxifyllin, vitamin E, NSAID and PUVA treatment were initiated. The patient showed signs of clinical improvement, but missed the regular follow-up controls for a year. In November 2001 she began taking D-penicillamine 300 mg daily, following the advice of a relative without consulting her physician. In February 2002 she was hospitalized at the rheumatology department because her skin symptoms worsened and she had typical RA-like polyarthritis affecting the wrists, metacarpophalangeal, proximal interphalangeal joints, right knee and the ankle joints. Radiological examination showed erosions on bilateral styloids, and the laboratory examination found anti-ENA, -SSA and -SSB positivity. SSc-RA overlap syndrome was diagnosed, and the dose of D-penicillamine was increased up to 450 mg daily, with physiotherapy and PUVA treatment being initiated in addition to ongoing medication. Her joint

pain decreased, the skin softened, and her general health status and movement capabilities improved significantly. Ten days after the initiation of higher dose D-penicillamine, erosions and ulcers developed on the inner surface of the lips (Fig. 1). Mouth balm was applied.

At the end of February she again reported to the dermatology unit with enlarged and painful lip ulcers and blisters that appeared throughout the body. Nicolsky's sign was positive, the histological examination showed perivascular lymphocytic infiltration, oedema and incipient acantholysis. Direct immunofluorescence demonstrated IgG and C3 staining along the epidermal cell surface membranes. Immunoblot analysis showed autoantibodies against the 130-kd desmoglein-3 (Fig. 2). A diagnosis of D-penicillamine-induced pemphigus vulgaris was made, the penicillamine treatment was stopped, and methylprednisolone 64 mg daily was started. Seven days later the skin and mucosal symptoms had disappeared, and the steroid was tapered and finally discontinued by the end of May 2002. As a disease-modifying agent methotrexate was given 7.5 mg weekly. Since then she has not been given steroid treatment and has been in remission for the past 17 months.

DISCUSSION

The definition of overlap syndromes is somewhat controversial in the medical literature. Most authors use this term for the coexistence of two distinct clinical entities. Some of them are relatively common, (RA-SLE, RA-Sjögren syndrome, RA-polymyositis, SLE-polymyositis), while others are relatively rare. The overlap between SSc and RA is less common, and represents a distinct clinical

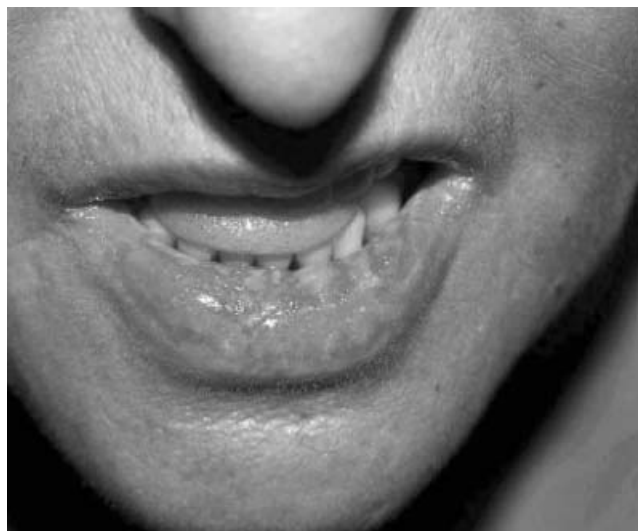

Fig. 1. Ulcers on the inside of the lip.

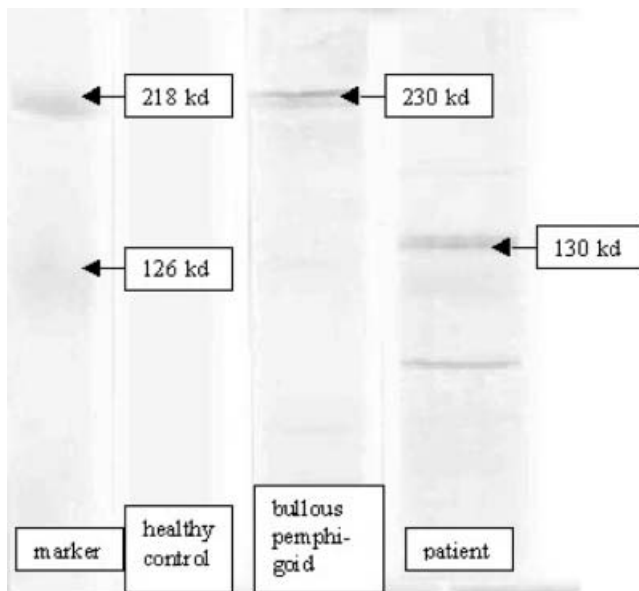


Fig. 2. Immunoblot analysis showing autoantibodies against the 130-kd desmoglein-3.

entity with generalized skin sclerosis and severe erosive polyarthritis (3).

During the past two decades, D-penicillamine has frequently been prescribed for patients with SSc in spite of significant adverse effects. Of particular interest is the association between penicillamine treatment and a wide variety of autoimmune disorders, including myasthenia, immune complex nephritis, thyroiditis, polymyositis, lupus erythematosus, thrombotic thrombocytopenic purpura and Goodpasture's syndrome. The cutaneous side effects of penicillamine are summarized in ref. (4). There is a growing body of evidence that pemphigus may be induced or exacerbated by penicillamine; about 100 cases have been described in the literature to date (1).

According to evidence gained from two *in vitro* studies, some drugs possess strong acantholytic qualities (5). Based on chemical structure two groups of drugs are distinguished: 1) thiol drugs like penicillamine and captopril, and 2) others. The clinical behaviour of pemphigus allows for division into two main groups; one comprises pemphigus that continues after stopping the drug, which is referred to as triggered pemphigus. In all probability this occurs in patients with a previous predisposition, with only a 15% spontaneous remission rate (5), while most patients (85%) have true pemphigus vulgaris. The other group consists of patients with lesions that clear soon after withdrawal of the drug, and is called induced pemphigus, with a spontaneous recovery rate of about 50%.

The pathogenesis of pemphigus connected with drug exposure is not entirely clear. The proposed mechanisms are: (i) drug interference with keratinocyte membrane and desmosomal surfaces, (ii) direct interference with normal desmosomal function or alteration of its antigenicity, (iii) production of immunogenic fragments by the enzymatic cleavage of desmoglein induced by SH groups or

penicillamine, and (iv) a change in suppressor or helper T-lymphocyte function or both, allowing the formation of autoantibodies against the 130-kd desmoglein-3 (1, 5, 6). Emery et al. (7) proved the pathogenetic role of autoantibodies against the 80-kd extracellular domain of desmoglein-1 in pemphigus foliaceus and pemphigus vulgaris. Several studies show that the autoantibody response is similar in both spontaneous and drug-induced disease (6, 8). Predisposing factors are underlying disease (e.g. RA), prolonged treatment, and, according to some authors, a genetic predisposition, i.e. HLA A3, B15 positivity (9).

The discontinuation of the offending drug and the introduction of oral or intravenous corticosteroid are the standard approaches. In case of refractory symptoms, or continuous steroid requirement, steroid-sparing agents (methotrexate, azathioprine, cyclophosphamide) or even plasmapheresis may be used. Lastly, promising therapeutic attempts with the use of long-term intramuscular sodium thiomalate were described by Penneys et al. (10).

Most reports of penicillamine-induced pemphigus are in patients with RA, 10 cases have been reported in patients with SSc (1) and only one case is described in a patient with mixed connective tissue disease (11). This is the first publication regarding a patient with SSc-RA overlap syndrome.

REFERENCES

- Shapiro M, Jimenez S, Werth VP. Pemphigus vulgaris induced by D-penicillamine therapy in a patient with systemic sclerosis. *J Am Acad Dermatol* 2000; 42: 297–299.
- Brenner S, Wolf R, Ruocco V. Drug-induced pemphigus I: a survey. *Clin Dermatol* 1993; 11: 501–504.
- Horiki T, Moriuchi J, Takaya M, Uchiyama M, Hoshina Y, Inada K, et al. The coexistence of systemic sclerosis and rheumatoid arthritis in five patients: clinical and immunogenetic features suggest a distinct entity. *Arthritis Rheum* 1996; 39: 152–156.
- Levy RS, Fisher M, Alter JN. Penicillamine: review and cutaneous manifestations. *J Am Acad Dermatol* 1983; 8: 548–558.
- Wolf R, Brenner S. An active amide group in the molecule of drugs that induce pemphigus: a casual or causal relationship? *Dermatology* 1994; 189: 1–4.
- Brenner S, Bialy-Golan A, Anhalt GJ. Recognition of pemphigus antigens in drug-induced pemphigus vulgaris and pemphigus foliaceus. *J Am Acad Dermatol* 1997; 36: 919–923.
- Emery DJ, Diaz LA, Fairley JA, Lopez A, Taylor AF, Giudice GJ. Pemphigus foliaceus and pemphigus vulgaris autoantibodies react with the extracellular domain of desmoglein-1. *J Invest Dermatol* 1995; 104: 323–328.
- Korman NJ, Eyre RW, Zone J, Stanley JR. Drug-induced pemphigus: autoantibodies directed against the pemphigus antigen complexes are present in penicillamine and captopril-induced pemphigus. *J Invest Dermatol* 1991; 96: 273–276.
- Zone J, Ward J, Boyce E, Schubach C. Penicillamine-induced pemphigus. *JAMA* 1982; 247: 2705–2707.
- Penneys NS, Eaglstein WH, Frost P. Management of pemphigus with gold compounds. *Arch Dermatol* 1976; 112: 185–187.
- Peñas PF, Buezo GF, Carvajal I, Daudén E, López A, Diaz LA. D-penicillamine-induced pemphigus foliaceus with autoantibodies to desmoglein-1 in a patient with mixed connective tissue disease. *J Am Acad Dermatol* 1997; 37: 121–123.