

## Late-onset Familial Onychodystrophy Heralding Incontinentia Pigmenti

Mario Bittar<sup>1</sup>, Retno Danarti<sup>1</sup>, Arne König<sup>1</sup>, Andreas Gal<sup>2</sup> and Rudolf Happle<sup>1</sup>

<sup>1</sup>Department of Dermatology, Philipp University, Deutschhausstrasse 9, D-35033 Marburg, Germany and <sup>2</sup>Department of Human Genetics, University Hospital Eppendorf, Hamburg, Germany. E-mail: mariobittar@web.de  
Accepted October 11, 2004.

Sir,

Incontinentia pigmenti (IP) is an X-linked dominant trait that is intrauterine lethal for males. The disorder is caused by *NEMO* mutations involving the NF $\kappa$ B activation pathway (1). It is characterized by linear skin lesions and various defects of the central nervous system, the teeth and the eyes. The cutaneous lesions are arranged along the lines of Blaschko, reflecting functional X-chromosome mosaicism (2). Because the diagnosis can now be confirmed or excluded by molecular analysis (1), it is possible to ascertain cases showing a rather mild or atypical involvement. In the present family, nail changes acquired during adulthood were a clue to recognizing two cases of IP.

### CASE REPORT

A 47-year-old woman complained of progressive painful nail changes that she had noted for 2 years. Onychodystrophy involved the thumbs as well as the left second and fourth finger which showed longitudinal ridging. Moreover, the proximal nail folds of the third and fourth fingers of the left hand were deformed, and that of the fourth finger was hyperplastic (Fig. 1a). The nails of both thumbs showed a 'sand-blasted' surface. Initially we thought of lichen planus but the patient reported that her maternal cousin had similar changes. A thorough examination of the patient revealed streaky hypopigmented lesions on her calves, becoming more prominent on Wood light examination, and a linear hypopigmentation with slight atrophy running from her left shoulder to the left upper arm (Fig. 1b). Several patchy areas of hairlessness were noted on her scalp. Moreover, absence of molar teeth was noted.

Her 45-year-old maternal cousin had noticed disturbed, but asymptomatic, nail growth for 5 years. Her molar teeth were absent. She had had three miscarriages, and one of them was analysed and found to have a normal male karyotype. Her left leg was shorter than her right leg. Cerebral apoplexy had occurred 4 years previously. A thorough examination of this patient revealed streaky hypopigmented lesions on her calves following the lines of Blaschko, becoming more prominent on Wood light examination. Patchy areas of hairlessness were noted on her scalp (Fig. 2). Distal onycholysis and a mild subungual hyperkeratosis were found on the index and middle fingers of her right hand.

Moreover, the probanda reported that her mother had streaky hypopigmented lesions and that a severely malformed eye was removed shortly after birth. The

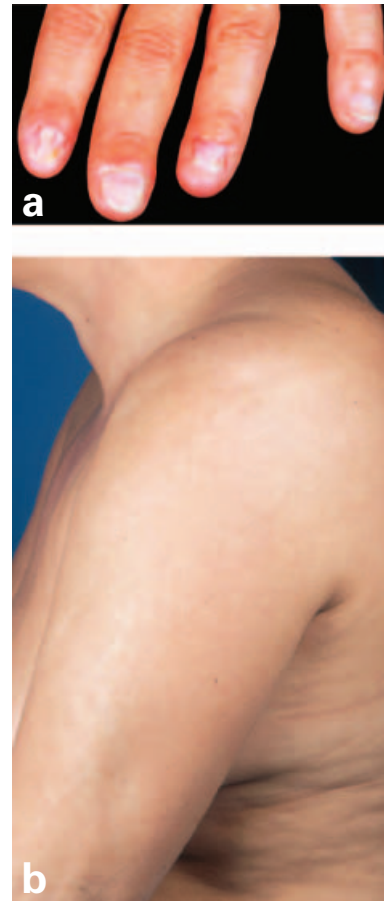

Fig. 1. (a) Left hand: Note longitudinal ridging of the nails of the index and ring finger. The proximal nail folds are deformed, and that of the ring finger is hyperplastic. (b) Left shoulder and upper arm showing a linear hypopigmentation.

patient's aunt reportedly had disturbed nail growth involving several fingers. Molecular analysis was performed in the probanda and her clinically unaffected daughter, as well as in the patient's cousin and her unaffected daughter. In the patient and her cousin a deletion of exons 4–10 within the *NEMO* gene was found, confirming the diagnosis of IP. No *NEMO* mutation was found in the healthy daughters of these individuals.

### DISCUSSION

In the present case, an adult woman asked for evaluation of an 'acquired' nail disorder that she had first noted at the age of 45 years. Her onychodystrophy turned out to represent a clue for the diagnosis of IP. Remarkably, a female cousin of this patient had first

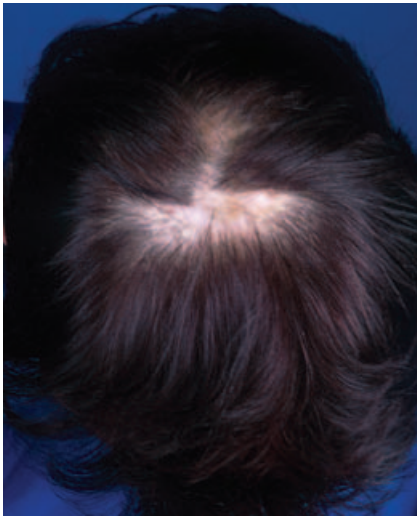


Fig. 2. Patchy hairlessness of the scalp of the 45-year-old cousin.

noticed similar nail changes at the age of 40 years and she was likewise shown to be affected with IP. This diagnosis had so far been overlooked in both women, although other clinical features such as absent molar teeth, patchy areas of hairlessness, asymmetrical length of legs, unilateral ocular malformation and miscarriages had occurred in two generations of this family.

The gene of IP has been identified as NEMO/IKK gamma, which maps at Xq28 and encodes for the nuclear factor kappa B (NF $\kappa$ B) essential modulator (1). NEMO/IKK gamma is required for activation of the transcription factor NF $\kappa$ B as well as for resistance to tumour necrosis factor-induced apoptosis (3), and is therefore involved in the control of many immunological, inflammatory and apoptotic pathways (1).

Nail dystrophy has been reported previously in association with IP (4, 5). These changes usually begin in childhood and tend to involve several nails.

Scardamaglia et al. (6) reported a case of IP with subsequent 20-nail dystrophy showing longitudinal ridging, thinning, fragility, loss of lustre, and roughness at the age of 3 years. These changes were documented to persist 6 years later.

Nicolaou & Graham-Brown (7) reported a 57-year-old woman with a history of nail dystrophy since the age of 11 years. Remarkably, these nail changes were the only manifestation of her IP that was confirmed by molecular analysis. Her daughter had classical IP.

A rather rarely associated nail disease in incontinentia pigmenti consists of painful subungual tumours (5, 8–15). They typically were observed in adulthood (15). Histopathologically they show verrucous hyperplasia of the epidermis with dyskeratotic cells at all levels, reminiscent of the features seen in the verrucous stage of IP (5, 8, 12, 15). In the present case there was no clear evidence of a subungual tumour, although the patient reported pain in her fingers.

It is difficult to understand why this type of nail change developed so late. Usually, nail changes in IP are noted during infancy, whereas in the present case the nails apparently remained normal until the age of 45 and 40 years, respectively.

In conclusion, today molecular analysis can help to ascertain mild or atypical cases of IP. Apparently the broad spectrum ranging from severe to mild involvement cannot be explained exclusively by the random effect of X-inactivation. A genotype–phenotype correlation has so far not emerged.

## REFERENCES

- Smahi A, Courtois G, Vabres P, Yamaoka S, Heuertz S, Munnich A, et al. Genomic rearrangement in NEMO impairs NF-kappaB activation and is a cause of incontinentia pigmenti. The International Incontinentia Pigmenti (IP) Consortium. *Nature* 2000; 405: 466–472.
- Happle R. Lyonization and the lines of Blaschko. *Hum Genet* 1985; 70: 200–206.
- Makris C, Godfrey VL, Krahn-Senftleben G, Takahashi T, Roberts JL, Schwarz T, et al. Female mice heterozygous for IKK gamma/NEMO deficiencies develop a dermatopathy similar to the human X-linked disorder incontinentia pigmenti. *Mol Cell* 2000; 5: 969–979.
- Carney RG. Incontinentia pigmenti. A world statistical analysis. *Arch Dermatol* 1976; 112: 535–542.
- Landy SJ, Donnai D. Incontinentia pigmenti (Bloch-Sulzberger syndrome). *J Med Genet* 1993; 30: 53–59.
- Scardamaglia L, Howard A, Sinclair R. Twenty-nail dystrophy in a girl with incontinentia pigmenti. *Australas J Dermatol* 2003; 44: 71–73.
- Nicolaou N, Graham-Brown RA. Nail dystrophy, an unusual presentation of incontinentia pigmenti. *Br J Dermatol* 2003; 149: 1286–1288.
- Mascaro JM, Palou J, Vives P. Painful subungual keratotic tumors in incontinentia pigmenti. *J Am Acad Dermatol* 1985; 13: 913–918.
- Abimelec P, Rybojad M, Cambiaghi S, Moraillon I, Cavelier-Balloy B, Marx C, et al. Late, painful, subungual hyperkeratosis in incontinentia pigmenti. *Pediatr Dermatol* 1995; 12: 340–342.
- Moss C, Ince P. Anhidrotic and achromians lesions in incontinentia pigmenti. *Br J Dermatol* 1987; 116: 839–849.
- Adeniran A, Townsend PL, Peachey RD. Incontinentia pigmenti (Bloch-Sulzberger syndrome) manifesting as painful periungual and subungual tumours. *J Hand Surg [Br]* 1993; 18: 667–669.
- Simmons DA, Kegel MF, Scher RK, Hines YC. Subungual tumors in incontinentia pigmenti. *Arch Dermatol* 1986; 122: 1431–1434.
- Shatkin BT, Hunter JG, Song IC. Familial subungual keratoacanthoma in association with ectodermal dysplasia. *Plast Reconstr Surg* 1993; 92: 528–531.
- Malvey J, Palou J, Mascaro JM. Painful subungual tumour in incontinentia pigmenti. Response to treatment with etretinate. *Br J Dermatol* 1998; 138: 554–555.
- Montes CM, Maize JC, Guerry-Force ML. Incontinentia pigmenti with painful subungual tumors: a two-generation study. *J Am Acad Dermatol* 2004; 50: S45–S52.