

Schnitzler's Syndrome without Monoclonal Gammopathy

Tatiana Cristina Nogueira Varella, Marcel Yossuke Nishimura, Maria Cecília Rivitti Machado, Dewton de Moraes-Vasconcelos and Evandro Ararigoia Rivitti

Division of Dermatology, Hospital das Clínicas, University of São Paulo, Avenida Itaboraí, n 425, apto 14, Bosque da Saúde, Cep. 04135-000, São Paulo, SP, Brazil. E-mail: tativarella@hotmail.com

Accepted October 11, 2004.

Sir,

Schnitzler's syndrome was first reported in 1972 and comprises chronic non-pruritic urticaria associated with intermittent fever, arthralgia, bone pain, hyperostosis, increased erythrocyte sedimentation rate (ESR) and a monoclonal IgM gammopathy (1). It is a rare and probably underdiagnosed disorder: so far about 50 cases have been reported in the literature. The aetiology of the syndrome is unknown. Age at onset of Schnitzler's syndrome ranges from 29 to 70 years and a slightly higher prevalence was reported in men (2). Although most cases follow a benign course, some cases develop a lymphoproliferative disease (3). We describe here a patient presenting clinical signs of Schnitzler's syndrome, but without IgM monoclonal gammopathy. In 2000, Husak et al. (4) described a similar case. Other cases have been described with clinical features of Schnitzler's syndrome and gammopathy of non-IgM immunoglobulin class (3).

CASE REPORT

A 36-year-old man presented a 2-year history of severe chronic non-pruritic urticaria. Urticarial lesions appeared almost daily and each lesion lasted from a few hours to a few days, causing residual pigmentation. He also had arthralgia, bone pain and intermittent high-grade fever. Fever peaks, sometimes as high as 40°C, were accompanied by worsening of skin rash. On examination, he had a widespread erythematous, oedematous, maculopapular rash on his trunk, extremities and face (Fig. 1).

Histological examination of the biopsy from an urticarial lesion revealed neutrophilic urticaria (Fig. 2). Direct immunofluorescence was negative for IgM, IgG, IgA and C3. Laboratory investigation showed an ESR of 51 mm/h and hypoalbuminaemia. Blood counting revealed leukocytosis of $19.84 \times 10^9/l$, with 91% of neutrophils, and normochromic normocytic anaemia (haemoglobin 116 g/l). Serum protein electrophoresis demonstrated high IgM concentration, although no clear evidence of monoclonal IgM gammopathy was found. Total IgM was 3.46 g/l (normal: 0.73–1.71 g/l). IgG, IgA, complement haemolytic assay (CH50), C3 and C4 were in normal range. β 2-Microglobulin was raised at 2.1 g/l (normal: 1.0–1.7 g/l). Test for rheumatoid factor was positive at 60.3 UI/ml (normal: <20 UI/ml). There were no antinuclear antibodies and cryoglobulins. Renal and hepatic profiles were normal. No Bence-Jones proteinuria was detectable. Multiple blood cultures were negative. Virological and microbiological screening revealed no infectious aetiology, including tests for hepatitis B and C, HIV, HTLV, infectious mononucleosis, acute cytomegalovirus disease, toxoplasmosis, infective endocarditis, syphilis, Lyme disease, brucellosis, histoplasmosis, aspergillosis, paracoccidioidomycosis, tuberculosis or leprosy. Analysis of stool specimens showed no parasites or ova. Studies to detect solid tumours were negative. Analysis of

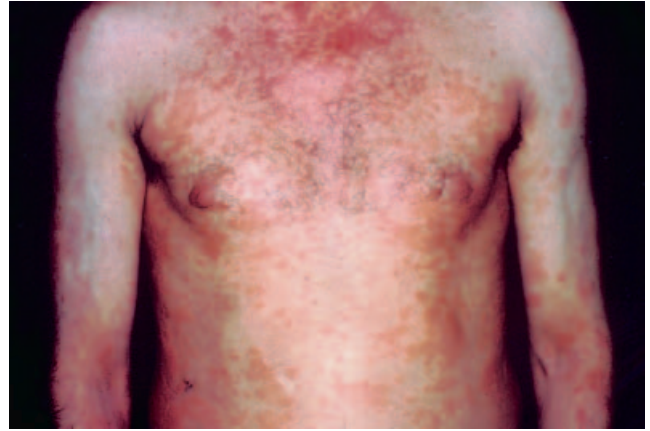


Fig. 1. Erythematous, oedematous, maculopapular rash on the trunk.

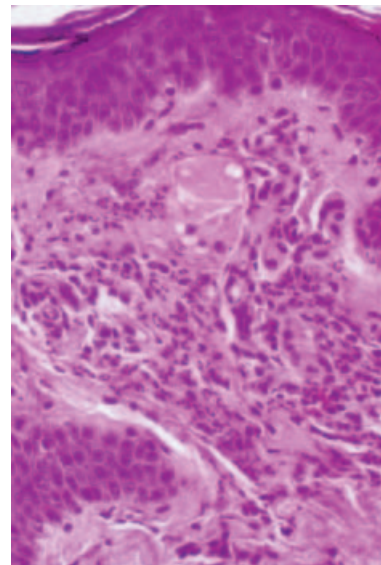


Fig. 2. A skin biopsy showing neutrophilic urticaria ($\times 400$).

single-cell cytokine profile revealed normal levels of interleukin (IL)-1, IL-6, IL-8, IL-10 and IL-12. Skeletal X-ray showed osteosclerosis of both femora. Thoracic computerized tomography demonstrated small para-aortic lymphadenopathy and abdominal ultrasonography showed splenomegaly and a renal cyst. Bone marrow histology displayed no abnormality.

Based on these findings, we favoured the diagnosis of Schnitzler's syndrome, despite the absence of monoclonal gammopathy.

The patient received high-dose prednisone, antihistamines, non-steroidal anti-inflammatory drugs (NSAIDs) and thalidomide with good control of arthralgia and bone pain, but without improvement of fever and rash. Interferon alpha-2b (3 MU s.c., three times per week) was then introduced, with no additional benefits.

DISCUSSION

In Schnitzler's syndrome, patients present chronic non-pruritic urticaria that usually appears simultaneously with high-grade intermittent fever. Bone pain, arthralgia and arthritis are characteristic findings. Additional features include weight loss, lymphadenopathy and hepatosplenomegaly.

Laboratory investigations show increased ESR, neutrophilic leucocytosis, normochromic normocytic anaemia and, in some cases, elevated platelet counts. Low levels of complement components, mainly C4, have also been observed. The presence of rheumatoid factor, antinuclear antibodies and cryoglobulins was reported in less than 10% of cases (5–7).

Histopathological findings of clinical urticarial lesions of Schnitzler's syndrome are not uniform but usually demonstrate neutrophilic urticaria. Alterations consistent with leukocytoclastic vasculitis, lymphocytic urticaria and spongiotic dermatitis have been reported (8). In about 25% of patients, direct immunofluorescence demonstrates monoclonal IgM deposits in skin along basement membrane or in capillary walls.

Conventional bone radiography shows osteosclerosis involving mainly the cortices of long bones, beginning with periosteal appositions.

At the time of diagnosis, bone marrow examination is normal in about 80% of patients. In the remaining 20%, unspecific, polyclonal, lymphocytic or plasmocytic infiltrates were observed (5).

In the great majority of patients, monoclonal IgM gammopathy without features of lymphoproliferative disease is present. IgM levels may be low (<10 g/l in 67% of patients) and can remain stable or increase progressively (5). The exact role of the monoclonal IgM or IgG in the pathogenesis of Schnitzler's syndrome is unclear. Intensity of the urticaria is not related to the level of paraprotein.

Differential diagnosis includes adult-onset Still's disease, cryoglobulinaemia, hypocomplementaemic urticarial vasculitis, systemic lupus erythematosus and lymphoma.

The disease follows a chronic course. Spontaneous or treatment-induced remissions have not been reported. Although 90% of cases follow a benign course, some cases develop a lymphoproliferative disorder such as IgM myeloma, Waldenström's macroglobulinaemia or lymphoplasmacytoid lymphoma (3).

Treatment of Schnitzler's syndrome remains difficult and unsatisfactory. Antihistamines do not control the skin rash. NSAIDs can control fever and bone pain, but with variable effect on urticaria. High-dose steroids can be effective in controlling urticarial rash and fever; however, this treatment cannot be sustained for long periods of time because of its side effects. Sulphones,

colchicine, immunosuppressive drugs, plasmapheresis and high-dose immunoglobulin therapy are ineffective. Psoralen and ultraviolet A therapy can reduce the urticaria in some patients. Thalidomide controlled rash, fever and bone pain in two cases reported in the literature (9). One patient showed good response to cyclosporin A (10) and two patients were successfully treated with interferon alpha-2b (11, 12). So, therapeutic guidelines remain to be established.

In most cases described in the literature, monoclonal IgM gammopathy was clearly evident and thus is one of the criteria that define Schnitzler's syndrome. However, in the last decade, some cases have been reported with paraproteinaemia of different classes (3) and even without monoclonal gammopathy (4).

REFERENCES

1. Schnitzler L. Lésions urticariennes chroniques permanents (érythème pétaoïde?). Case cliniques n. 46 B. *Journée Dermatologique d'Angers* 1972; 28 October (Abstr. 46).
2. Almerigogna F, Giudizi MG, Cappelli F, Romagnani S. Schnitzler's syndrome: what's new? *J Eur Acad Dermatol Venereol* 2002; 16: 214–219.
3. Akimoto R, Yoshida M, Matsuda R, Miyasaka K, Itoh M. Schnitzler's syndrome with IgG kappa gammopathy. *J Dermatol* 2002; 29: 735–738.
4. Husak R, Nestoris S, Goerdts S, Orfanos CE. Severe course of chronic urticaria, arthralgia, fever and elevation of erythrocyte sedimentation rate: Schnitzler's syndrome without monoclonal gammopathy? *Br J Dermatol* 2000; 142: 581–582.
5. Lipsker D, Veran Y, Grunenberger F, Cribier B, Heid E, Grosshans E. The Schnitzler syndrome. Four new cases and review of the literature. *Medicine* 2001; 80: 37–44.
6. Puddu P, Cianchini G, Girardelli CR, Colonna L, Gatti S, de Pita O. Schnitzler's syndrome: report of a new case and review of the literature. *Clin Exp Rheumatol* 1997; 15: 91–99.
7. Berdy SS, Bloch KJ. Schnitzler's syndrome: a broader clinical spectrum. *J Allergy Clin Immunol* 1991; 87: 849–854.
8. de Castro FR, Masouye I, Winkelmann RK, Saurat JH. Urticarial pathology in Schnitzler's (hyper-IgM) syndrome. *Dermatology* 1996; 193: 94–99.
9. Worm M, Kolde G. Schnitzler's syndrome: successful treatment of two patients using thalidomide. *Br J Dermatol* 2003; 148: 601–602.
10. Pascual-Lopez M, Hernandez-Nunez A, Sanchez-Perez J, Fernandez-Herrera J, Garcia-Diez A. Schnitzler's syndrome with monoclonal IgG kappa gammopathy: good response to cyclosporin. *J Eur Acad Dermatol Venereol* 2002; 16: 267–270.
11. Scharz NE, Buder S, Sperl H, Audring H, Paus R, Tebbe B, et al. Report of a case of Schnitzler's syndrome treated successfully with interferon alpha 2b. *Dermatology* 2002; 205: 54–56.
12. Kuenzli S, Buchet S, Saurat JH. Successful treatment of Schnitzler's syndrome with interferon alfa-2b. *Dermatology* 2002; 205: 74.