

Juvenile Pemphigus Vegetans of the Glans Penis

Giovanni Maria Palleschi, Barbara Giomi and Andrea Giacomelli

II Department of Dermatological Sciences, University of Florence, Via della Pergola 58, IT-50121 Florence, Italy.

E-mail: giovannimaria.palleschi@tin.it

Accepted December 15, 2003.

Sir,

Pemphigus is defined as a group of mucocutaneous blistering diseases characterized by epithelial acantholysis. In all variants of pemphigus, circulating and fixed autoantibodies against the intercellular substance of epithelium have been demonstrated. Suprabasal clefting is seen in pemphigus vulgaris and its rare variant, pemphigus vegetans (1).

The latter form of pemphigus is characterized by papillomatous and vegetative lesions and accounts for about 5% of cases. It is historically differentiated into two types (2). In the Neumann type, often beginning as pemphigus vulgaris, soft whitish vesicles soon erode and heal with verrucous hypertrophic growths. In the Hallopeau type, yellowish pustules are the primary lesions; crusted, verruciform or papillomatous proliferations then develop with an advancing border of new pustules (1). The course of disease is relatively benign (3).

Both entities affect primarily the intertriginous areas (4). In addition, broken bullae and erosions with vegetations may occur on the oral, nasal or oesophageal mucosa (5–7); the involvement of the genital mucosa is exceedingly rare.

Herein we report the occurrence of pemphigus vegetans of the Neumann type with both cutaneous and mucous manifestations in a young boy.

CASE REPORT

A 16-year-old boy was admitted for evaluation of coincidental erosive balanoposthitis and stomatitis of 6 months duration. His medical history revealed a transient bullous eruption on the back, appearing about 2 months earlier. Physical examination showed large and painful erosions of the cheek mucosa (Fig. 1) and soft palate, with irregular shedding outline and central hypertrophic and vegetating epithelium regeneration. Scrotal tongue was not present. Oral smear for Tzanck cytodiagnosis revealed numerous acantholytic cells. Similar coalescing erosions with vegetating borders were seen on the glans and the mucous surface of the prepuce (Fig. 2). Hyperpigmented lesions after previous bullae were localized on the sacral region. Microscopic examination of a specimen taken from the prepuce showed a suprabasal detachment, with loss of the surface epithelium. The extensive acantholytic phenomena featured numerous villous projections consisting of dermal papillae. A modest downward growth of epithelial strands from the basal cells was also demonstrated. Telangiectasias with extravasation of erythrocytes and a variably dense band-like mixed inflammatory infiltrate, consisting of plasma cells and small lymphocytes with focal collection of eosinophils were present in the villous projections and superficial dermis (Fig. 3).

Indirect immunofluorescence (IIF) of the patient's serum showed circulating antibodies to the intercellular spaces of

titre 1:80. Direct immunofluorescence (DIF) performed on perilesional glans penis mucosa revealed intercellular deposition of IgG and C3.

These findings allowed us to establish the diagnosis of juvenile pemphigus vegetans. Treatment with prednisone at an initial dose of 1.5 mg/kg/day, gradually tapered to 0.2 mg/kg/day produced rapid benefit. Within 4 months of therapy mucosal lesions had completely cleared and IIF findings had become negative.

Unfortunately, the patient did not comply with the instructions; once he discontinued corticosteroids, the disease relapsed with cutaneous bullae typical of pemphigus vulgaris. Within the first year he was lost to follow-up and we could not observe the long-term evolution of this case.

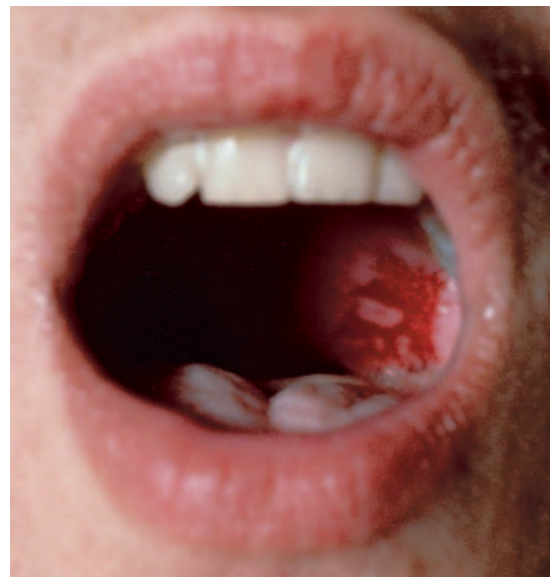

Fig. 1. Erosions of the cheek mucosa with central hypertrophic and vegetating epithelium regeneration.

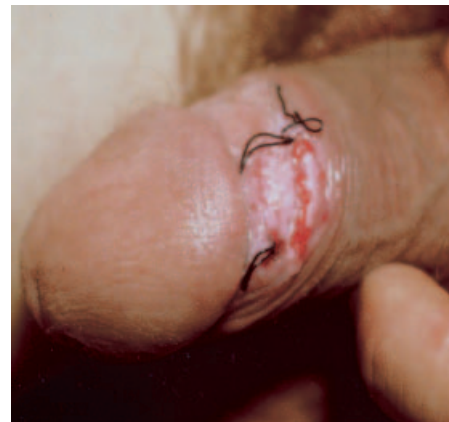

Fig. 2. Coalescing erosions with vegetating borders of the glans and the mucous surface of the prepuce.

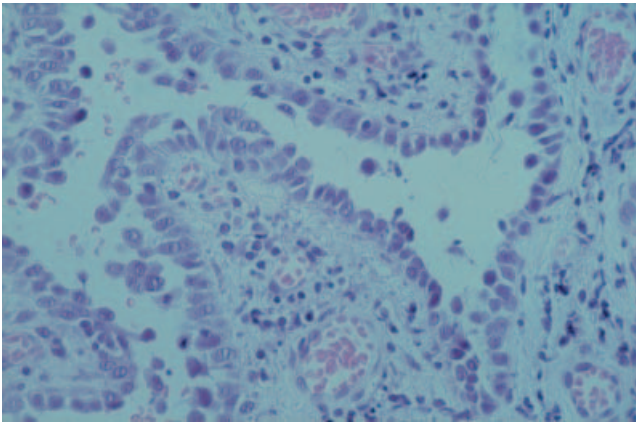


Fig. 3. Suprabasal detachment, and extensive acantholytic phenomena of the epithelium. Band-like mixed inflammatory infiltrate, consisting of plasma cells and small lymphocytes with focal collection of eosinophils, present in the villous projections and superficial dermis. (H&E staining, $\times 150$).

DISCUSSION

Pemphigus is a rare mucocutaneous disease which generally affects middle-aged adults. So far, the literature reports only few cases occurring under the age of 18 (8, 9); most of these patients suffered from pemphigus vulgaris or foliaceus.

Only two reports about the vegetans variety of the disease in childhood have been published (9–11), both referring to cutaneous forms. The first patient described in 1992 (11) was a 12-year-old Chinese boy, who developed painful stomatitis and vegetating erosive plaques of the intertriginous regions. In the second case (9) the clinical presentation resembled pemphigus vulgaris but the lesions in the perianal area healed as hypertrophic granulation tissue. The patient was treated with oral and intralesional corticosteroids and azathioprine.

Regarding pemphigus vegetans of mucosae in all ages, we could only find two case reports in the literature. The first describes a recurrent vulvar acantholytic dermatosis in a 22-year-old Indian woman (12), while the second (13) describes a man suffering from chronic balanitis closely resembling our case. As in our report, treatment with prednisone orally (starting dose 60 mg/day) resulted in a significant improvement within 3 weeks.

Our patient, who represents the first case of juvenile pemphigus vegetans of the glans penis, additionally showed hypertrophic granulations in the oral mucosa, and cutaneous manifestations of pemphigus vulgaris.

The prognosis of pemphigus in childhood has been widely debated (8, 13–15). Controversies probably depend on earliness of diagnosis, type of management and differences in follow-up time, but all authors agree that superficial or localized variants are associated with a less severe course, whereas widespread pemphigus vulgaris, especially in infants, often

leads to fatal outcome. In severe cases, treatment with high doses of systemic corticosteroids and cytostatic drugs may cause serious side-effects (8). When blistering is milder and/or patients are relatively older, low-dose corticosteroids are effective and well tolerated. In some reports even aggressive topical therapy (16), intralesional corticosteroids (14) or dapsone (17) were successful.

Despite the usual treatment resistance of mucous membrane lesions, our patient went rapidly into clinical remission with oral prednisone, but early recurrence was observed. Our experience thus further confirms previous observations (8).

REFERENCES

- Braun-Falco O, Plewig G, Wolff HH, Winkelmann RK. Vesicular and bullous diseases. In: *Dermatology*, 3rd edn. Berlin: Springer-Verlag, 1991: 468–501.
- Jansen T, Messer G, Meurer M, Plewig G. Pemphigus vegetans. A historical perspective. *Hautartz* 2001; 52: 504–509.
- Lever WF. Noninfectious vesiculobullous and vesiculopustular diseases. In: Lever WF, ed. *Histopathology of the skin*, 8th edn. Philadelphia: Lippincott-Raven, 1997: 221–222.
- Pye RJ. Bullous eruptions. In: Champion RH, Burton JL, Ebling FJG, eds. *Rook/Wilkinson/Ebling textbook of dermatology*, 5th edn. Oxford: Blackwell Science, 1992: 1641–1642.
- Downie JB, Dicostanzo DP, Cohen SR. Pemphigus vegetans – Neumann variant associated with intranasal heroin abuse. *J Am Acad Dermatol* 1998; 39: 872–875.
- Ichimiya M, Nakano J, Muto M. Pemphigus vegetans involving the esophagus. *J Dermatol* 1998; 25: 195–198.
- Sawai T, Kitazawa K, Danno K, Sugie N, Machizuli T, Sugiura H, et al. Pemphigus vegetans with oesophageal involvement: successful treatment with minocycline and nicotinamide. *Br J Dermatol* 1995; 132: 668–670.
- Ahmed AR, Salm M. Juvenile pemphigus. *J Am Acad Dermatol* 1983; 8: 799–807.
- Wanaunkul S, Pongprasit P. Childhood pemphigus. *Int J Dermatol* 1999; 38: 29–35.
- Sillevis Smitt JH, Muelder TJ, Albeda FW, Van Nierop JC. Pemphigus vegetans in a child. *Br J Dermatol* 1992; 127: 289–291.
- Sillevis Smitt JH. Pemphigus vulgaris in childhood: clinical features, treatment and prognosis. *Pediatr Dermatol* 1985; 2: 185–190.
- Wong KT, Wong KK. A case of acantholytic dermatosis of the vulva with features of pemphigus vegetans. *J Cutan Pathol* 1994; 21: 453–456.
- Castle WN, Wentzell JM, Schwartz BK, Clendenning WE, Selikowitz SM. Chronic balanitis owing to pemphigus vegetans. *J Urol* 1987; 137: 289–291.
- Qureshi WA, Ali A, Bhol KC, Ahmed AR. Juvenile pemphigus foliaceus treated with sublesional corticosteroids. *Int J Dermatol* 1997; 36: 848–849.
- Mehravaran M, Morvay M, Molnar K, Olah J, Korom I, Husz S, et al. Juvenile pemphigus foliaceus. *Br J Dermatol* 1998; 139: 496–499.
- Khan G, Lewis HM. True childhood pemphigus: pemphigus foliaceus in an 18-months-old child. *Am J Dis Child* 1971; 121: 253–256.
- Basset N, Gillot B, Bruno M. Dapsone as initial treatment in superficial pemphigus. *Arch Dermatol* 1987; 123: 783–785.