

Cryptococcosis: Long-lasting Presence of Fungi after Successful Treatment

Miwa Kobayashi, Koji Murata, Hiroshi Orimo Hiroshi and Yoshiki Tokura

Department of Dermatology, University of Occupational and Environmental Health Japan, 1-1 Iseigaoka Yahatanishi-ku, Kitakyushu, J-807-8555, Japan. E-mail: miw-koba@med.uoeh-u.ac.jp

Accepted December 12, 2003.

Sir,

Cryptococcosis is an opportunistic infection caused by *Cryptococcus neoformans* and is usually seen in immunocompromised patients. Histopathologically, the skin lesions are divided into two types, i.e. cystic and granulomatous lesions (1, 2), each of which occurs exclusively depending on the conditions of individual hosts (3). For unknown reason the titre of cryptococcal antigen in patients' sera may be persistently positive even after treatment with antifungal therapies (4). We report here an immunosuppressed patient with severe cryptococcosis who had persistent elevation of antigen titre post-treatment and a presence of fungi remaining after clinical improvement.

CASE REPORT

A 68-year-old Japanese man was admitted to our hospital in November 2000 because of a 4-month history of enlarging ulcers on both lower legs. The eruption started as phlegmonous lesions occurring on the posterior aspect of the right calf and evolved into large ulcers thereafter. Because of myasthenia gravis, he had been treated since 1997 with 30 mg prednisolone and 150 mg azathioprine, daily. He had a hobby of keeping cage birds.

On examination, there were irregularly shaped large ulcers extending from the left calf to thigh and right calf, which reached the underlying muscles (Fig. 1a,b). Yeast-like cells with thick capsules were observed in the smear of pus from the ulcer by the India ink technique (Fig. 1c). Culture on brain-heart infusion agar yielded growth of *C. neoformans* A identified by Crypto Check[®] (Iatron, Tokyo, Japan).

Computed tomography of the chest cavity showed multiple nodules in the right lung. The serum titre of cryptococcal antigen assessed by latex agglutination was 1:512, but the antigen was negative in the cerebrospinal fluid. We diagnosed our patient as having asymptomatic pulmonary cryptococcosis with cutaneous dissemination.

Shortly after admission, the patient was given oral itraconazole, 200 mg daily. Three months later, the ulcers were covered with a fresh granulation tissue, and a skin grafting operation was performed. He was discharged and currently remains healthy without recurrence.

Changes in the titre of the patient's serum cryptococcal antigen were monitored in the clinical course. It was elevated to 1:16,384 in February 2001. This extremely high level continued for 1 year and gradually decreased to 1:1,024 during the following year.

Biopsy specimens were taken from lesional skin four times, i.e. November 2000, February 2001, June 2001 and October 2001. Before the treatment with itraconazole (November 2000), there was a relatively low level of inflammation and there were aggregates of spores in the dermal and subcutaneous fat tissues. The vessel walls of small arteries and veins were necrotic with surrounding polymorphonuclear cell infiltrates, suggesting that the cryptococcal infection was disseminated haematogenously to the skin. In the first

specimen, the inflammatory cell infiltrate was not heavy, while a great number of spores were present (Fig. 2a). After the treatment (February 2001), a considerable tissue reaction appeared. Most parts of the dermis and subcutaneous fat were filled with histiocytes, multinucleate giant cells such as Touton giant cells, neutrophils and lymphocytes. The giant cells contained many spores (Fig. 2b). Three months later (June 2000), the infiltrate was almost entirely displaced by epithelioid histiocytes, which still had spores in the cytoplasm. Finally in October 2001, foreign-body giant cells and marked fibrosis were seen (Fig. 2c). Notably, many spores still existed within and outside the giant cells (Fig. 2d).

DISCUSSION

Cryptococcal cellulitis is a rare disease and all the previously reported cases had immunosuppressive conditions (5). Our patient had been treated with immunosuppressants for 4 years. The first biopsy specimen disclosed that necrotizing vasculitis was present in association with accumulated fungi, as has been documented in two cases of cryptococcal cellulitis (5, 6). This finding can be interpreted as haematogenous dissemination from the lung to the skin. Skin eruptions may occur as the initial manifestation of disseminated cryptococcosis (5) and provide an important clue for diagnosing this infection.

Our histological study of the four serial biopsy specimens demonstrated the dynamic changes in the

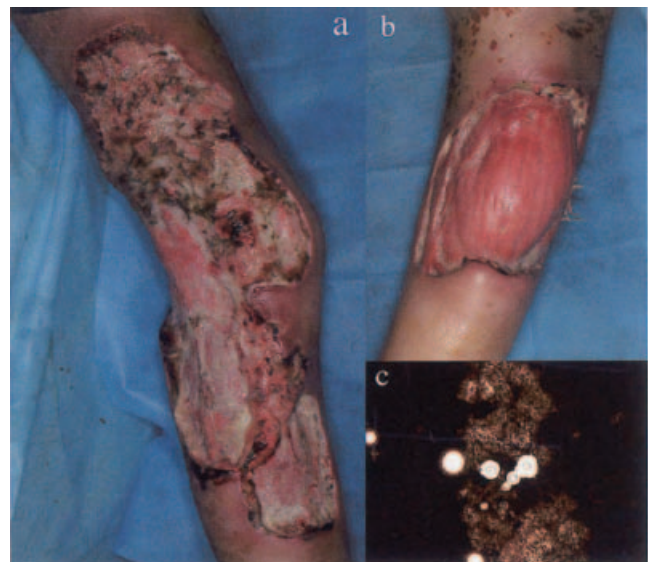

Fig. 1. Large, deep ulcers on the left (a) and right (b) legs. Cryptococci were found in the smear of pus by the India ink technique (c).

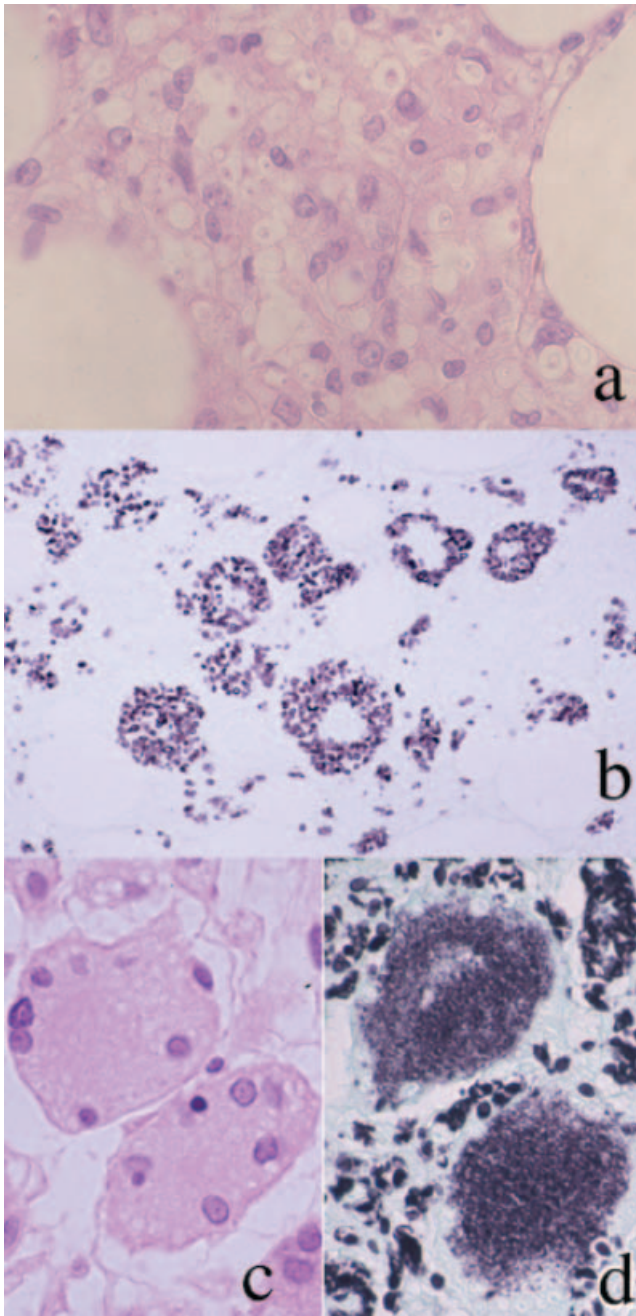


Fig. 2. Before treatment (a) oval or budding spores surrounded by haloes are present with lymphocytes and neutrophils (H&E $\times 400$). Twelve weeks after antifungal treatment (b), cryptococci are seen in large multinucleate histiocytes (Grocott methenamine silver (GMS) stain $\times 200$). Forty-five weeks later fibrosis is present in dermal and subcutaneous tissue with foreign-body giant cells (c) (H&E $\times 400$), containing numerous small fungal structures (d) (GMS $\times 400$).

tissue reaction to *Cryptococcus* and the existing state of this fungus. The initial inflammatory response to fungi was rather low and mediated mainly by neutrophils, as

poor tissue reactions or suppurative inflammation have been reported in cryptococcal cellulitis (6–8). Later specimens exhibited marked granulomatous changes, which consisted of histiocytes and multinucleate giant cells containing many spores. This was followed by fibrosis and foreign-body histiocyte infiltration, as seen in the fourth specimen taken from the normal-appearing skin. In this specimen, a large number of fungi were still present within the cells and freely in the dermis.

The serum cryptococcal antigen titre remained high during the course of the disease. Such persistent elevation of the antigen has also been reported in other patients (9). Ikeda et al. (10) found that the elimination half-life of cryptococcal antigen is approximately 40 days in an animal model of cryptococcal antigenaemia, suggesting that the fungal polysaccharide is stored in the tissue. In our observation, however, the high antigen titre paralleled the actual presence of fungi, as typically seen in the fourth specimen. Therefore, the antigenaemia seems not to be derived merely from the stored fungal elements in the tissue. It is suggested that a long period of usage of antifungal drugs is preferable in patients with cryptococcosis, especially in immunocompromised hosts.

REFERENCES

1. Rippon JW. Medical mycology, 2nd edn. Philadelphia: WB Saunders, 1982: 532–538.
2. Moore M. Cryptococcosis with cutaneous manifestations. *J Invest Dermatol* 1957; 28: 159–182.
3. Watanabe T, Miyaji M, Nishimura K. Studies on relationship between cysts and granulomas in murine cryptococcosis. *Mycopathologia* 1984; 86: 113–120.
4. Aoki Y, Ohtsuka M, Nakazawa M, Nakamura H, Yoda Y, Abe T. A case report of systemic cryptococcosis with Lennert's lymphoma — A clinical significance of *C. neoformans* antigen titer in the serum [in Japanese]. *Jpn J Clin Immunol* 1985; 8: 110–116.
5. Sharader SK, Watis JC, Dancik JA, Band JD. Disseminated cryptococcosis presenting as cellulitis with necrotizing vasculitis. *J Clin Microbiol* 1986; 24: 860–862.
6. Kimura M, Kadota E, Satou T, Yoneda E, Furuta T. Case report. Cryptococcal cellulitis showing necrotizing vasculitis. *Mycosis* 2001; 44: 115–118.
7. John GP. Cryptococcal cellulitis. *JAMA* 1977; 237: 672–673.
8. Anderson DJ, Schmidt C, Goodman J, Pomeroy C. Cryptococcal disease presenting as cellulitis. *Clin Infect Dis* 1992; 14: 666–672.
9. Schupbach CW, Wheeler CE, Briggaman RA, Warner NA, Kanof EP. Cutaneous manifestation of disseminated cryptococcosis. *Arch Dermatol* 1976; 112: 1734–1740.
10. Ikeda R, Tamura M, Shinoda T. Persistence of cryptococcal antigenemia in an infected dog and uninfected rabbits. *Med Mycol* 2000; 38: 85–89.