

## Dyshidrosiform Bullous Pemphigoid

You Jeong Kim, Mi-Yeon Kim, Hyung Ok Kim and Young Min Park\*

Department of Dermatology, Kangnam St Mary's Hospital, College of Medicine, Catholic University of Korea, 505 Banpo-Dong, Seocho-Gu, Seoul, 137-040, South Korea. \*E-mail: knderma@cmc.cuk.ac.kr  
Accepted November 29, 2003.

Sir,

Dyshidrosiform bullous pemphigoid (DBP) is an unusual localized variant of bullous pemphigoid (BP), first described by Levine et al. (1) in 1979. It presents with a persistent vesicobullous eruption similar to dyshidrosiform dermatitis. As it may be the only feature of BP, and it usually responds well to topical steroid treatment, it may mislead clinicians to the diagnosis of pompholyx. Herein we report a case of DBP that initially presented with vesicles and bullae localized to both soles, which subsequently spread to both extremities.

### CASE REPORT

An 89-year-old woman presented with recurrent painful vesicles and bullae localized to both soles. They had recurred once or twice a year for the previous 2 years and responded to topical steroid therapy. An examination revealed multiple tense vesicobullae of various sizes, in part haemorrhagic, with a base of normal skin colour on both soles (Fig. 1). The Nikolsky sign was negative. No mucosal and other cutaneous involvement was observed. Potassium hydroxide preparation and fungal culture of the lesion were negative. Her past and family history was not contributory.

A biopsy specimen from the sole showed focal spongiosis in the epidermis, predominantly eosinophilic infiltration in the oedematous papillary dermis. Stains for fungal organisms were negative. Direct

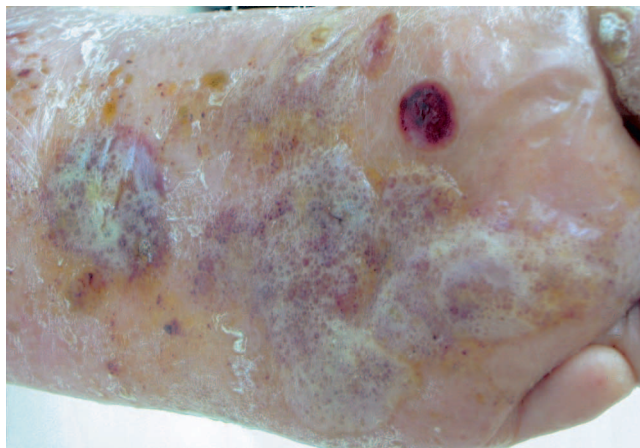


Fig. 1. Multiple tense vesicles and bullae, in part haemorrhagic, with a base of normal skin colour on both soles.

immunofluorescence (DIF) of the perilesional skin disclosed continuous linear deposits of IgG and C3 along the dermo-epidermal junction. Indirect immunofluorescence (IIF) revealed anti-basement membrane antibody at a titre of 1:640 on the normal human skin and circulating antibodies exclusively localized to the epidermal side of the human salt split skin. Treatment with prednisolone 30 mg/day for 2 weeks combined with topical steroid application resulted in a marked clinical improvement with no new blister formation. The systemic steroid dose was then gradually tapered. After the next 3 months, while she withdrew from the subsequent follow-up, new vesicles and bullae developed on both extremities. An examination revealed multiple, focally haemorrhagic, tense vesicles and bullae on the erythematous or normal skin-coloured bases with erosions. Routine histological examination, DIF and IIF of the new lesions also showed findings consistent with those of BP.

### DISCUSSION

DBP is a localized variant of BP, clinically characterized by palmo-plantar vesicobullae, sometimes haemorrhagic. This may be the only feature, or it may sometimes occur with minor generalized classic lesions of BP (2). As in the other types of localized BP, some cases of DBP may subsequently progress to a generalized BP, as shown in our case. Because DBP shares the same causative anti-basement membrane antibody with BP, the histopathological and immunofluorescence microscopic findings of DBP are consistent with those of BP. However, the mechanism of a localization of DBP is unclear. Levine et al. (1) suggested that antigens are usually protected from antibody recognition and an inflammatory process such as tinea pedis could cause the antigen to be uncovered. However, further studies will be needed to determine this mechanism.

The prevalence of DBP is not fully understood. From the recent literature, 19 cases of DBP have been reported so far (2). However, some studies indicated that DBP is not as rare as previously reported. Åsbrink & Hovmark (3) reported that 9 of 20 patients presented with the vesicles on the palms and/or soles as prodromal symptoms of BP, and two of them had this vesicular eruption exclusively on the palms and/or the soles. Barth et al. (4) showed that palmar and/or

plantar lesions were observed in 28% (20/71) of the patients with pemphigoid, and in four patients, the palmo-plantar lesions were the presenting features. A clinical study of 86 patients with BP in Taiwan revealed that only 3 of 86 cases could be diagnosed with dyshidrosiform pemphigoid (5).

The clinical manifestation of DBP is quite similar to that of pompholyx, which can delay a proper diagnosis. Clinicians should be aware that an unusually persistent or haemorrhagic dyshidrosiform dermatitis on the palms and/or soles, particularly in elderly patients, may conceal BP. Therefore, a histopathological study and immunofluorescence microscopy should be performed as soon as possible in all such cases.

## REFERENCES

1. Levine N, Freilich A, Barland P. Localized pemphigoid simulating dyshidrosiform dermatitis. *Arch Dermatol* 1979; 115: 320–321.
2. Patrizi A, Rizzoli L, Benassi L, Neri I. Another case of dyshidrosiform pemphigoid. *Eur Acad Dermatol Venereol* 2003; 17: 370.
3. Åsbrink E, Hovmark A. Clinical variations in bullous pemphigoid with respect to early symptoms. *Acta Derm Venereol* 1981; 61: 417–421.
4. Barth JH, Venning VA, Wojnarowska F. Palmo-plantar involvement in auto-immune blistering disorders – pemphigoid, linear IgA disease and herpes gestationis. *Clin Exp Dermatol* 1988; 13: 85–86.
5. Chang YT, Liu HN, Awong CK. Bullous pemphigoid – a report of 86 cases from Taiwan. *Clin Exp Dermatol* 1996; 21: 20–22.