

## Diffuse Dermal Angiomatosis due to an Iatrogenic Arteriovenous Fistula

Sabine Sommer<sup>1</sup>, William James Merchant<sup>2</sup> and Caroline Lesley Wilson<sup>1</sup>

Departments of <sup>1</sup>Dermatology and <sup>2</sup>Histopathology, United Leeds Teaching Hospitals, Leeds General Infirmary, Great George Street, Leeds LS1 3EX, UK. E-mail: s.sommer@ntlworld.com  
Accepted 21 November 2003.

Sir,

Reactive angio-endotheliomatosis (RAE) is a rare skin condition characterized by a diffuse proliferation of endothelial cells within the vascular lumina with secondary intravascular thrombi, resulting in obliteration of involved blood vessels. Clinical features are variable with both generalized and localized forms recognized (1, 2). We describe here a patient with Wegener's granulomatosis (WG), who developed a localized patch of diffuse dermal angiomatosis, a subtype of RAE, distal to an arteriovenous fistula required for haemodialysis.

### CASE REPORT

A 59-year-old woman presented with end-stage renal failure and a collapsed nasal septum, but without skin changes. Her past medical history included pernicious anaemia, cholecystectomy for gallstones and tuberculosis of the hip.

Abnormal investigations comprised a positive c-ANCA > 100 U/ml (<7), CRP 275 mg/l (<10), Hb 7 g/dl (12–16), WCC  $17.9 \times 10^9/l$  (4–10). Renal biopsy showed an acute necrotizing vasculitis, granulomas and late stage glomerulonephritis leading to a diagnosis of WG. Treatment with pulsed methylprednisolone and cyclophosphamide failed to improve her renal function. A right-sided brachiobasilic fistula was created for haemodialysis.

She was commenced on oral prednisolone reducing gradually from 40 mg to 5 mg per day. Other medication consisted of disodium etidronate, lansoprazole, codeine phosphate, folic acid, vitamin B12 and iron injections.

After 1 year, while still on prednisolone, she developed a painful lesion on her forearm without any symptoms of active WG, a negative c-ANCA and normal CRP. The prednisolone was increased to 7.5 mg/day and she was referred to the Department of Dermatology.

The patient presented with a solitary, erythematous, indurated and centrally ulcerated plaque distal to the shunt on the volar aspect of her right forearm (Fig. 1a). This was slowly enlarging and painful. The surrounding normal-looking skin was tender, with underlying muscle wasting, but without oedema. Her right hand was scaly, pale and cold to the touch, suggesting a vascular steal phenomenon.

Swabs for microbiology and fungal scrapings were negative. A soft tissue X-ray showed no calcification.

A skin biopsy revealed a proliferation of small capillary blood vessels extending from the papillary dermis into the deep reticular dermis. The vessels had narrow lumina, often containing red blood cells. They were lined by a single layer of plump endothelial cells and were surrounded by a pericyte layer, confirmed by a smooth muscle actin stain. No granulomas or necrotizing vasculitis were identified (Fig. 2a). A CD31 stain was positive for endothelial cells within the vascular channels (Fig. 2b). A diagnosis of diffuse dermal angiomatosis, a variant of RAE, secondary to an iatrogenic arteriovenous fistula with associated steal phenomenon was made.

Treatment with topical clobetasol propionate 0.05%

ointment under occlusion initially helped the soreness, but was soon ineffective, with the plaque extending towards the shunt. The prednisolone was increased to 40 mg/day, resulting in symptomatic and visible improvement after 3 weeks, whereafter the dose was gradually reduced over 10 weeks to 5 mg/day as required as maintenance therapy for the WG. The RAE had healed completely after 2 months. When the patient was discharged from the Department of Dermatology after a further 2 months, her hand felt warm to the touch with pink-looking skin (Fig. 1b).

### DISCUSSION

WG is a systemic disease characterized by necrotizing granulomatous inflammation and vasculitis. One series found skin involvement in only 14% of (mainly generalized) cases (3). This was clinically varied, showing necrotizing vasculitis or granuloma formation on histology. The activity of the skin disease was mirrored by the general activity of the WG, and the c-ANCA was usually positive.

Benign reactive vascular proliferations of unknown aetiology include RAE, acroangiokeratosis and diffuse dermal angiomatosis. The clinical features of RAE range from ecchymoses, macules and plaques to bullous lesions (1, 2). Different conditions have been associated with generalized forms of the disease, although it remains unknown to what extent any of these are truly causative, with a marked inter-case heterogeneity in clinical pattern, disease course and histopathological features (2). RAE is not related to intravascular lymphoma (angiotropic lymphoma or intravascular

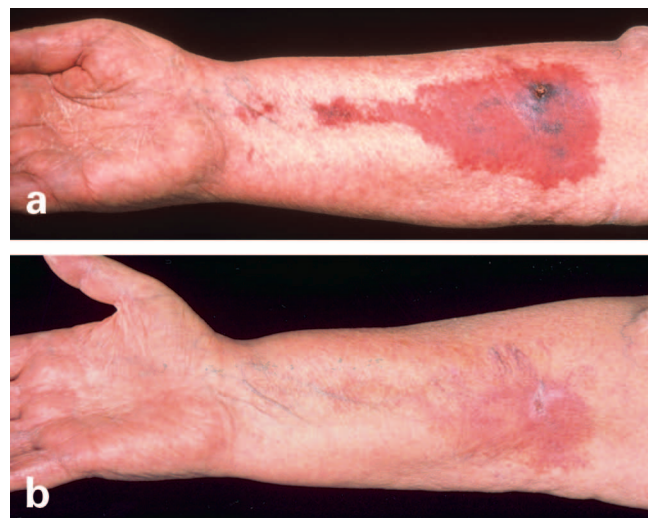

Fig. 1. (a) Volar aspect of the forearm, showing a plaque of indurated erythematous skin with central necrosis. (b) Same patient after 4 months.

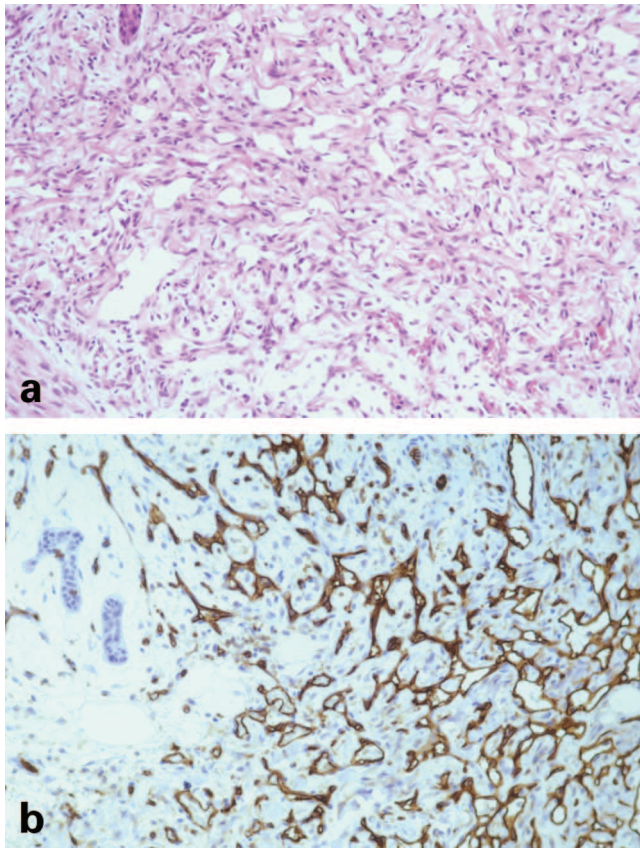


Fig. 2. (a) Numerous thin-walled vascular channels are seen throughout the reticular dermis. An eccrine duct is noted at the top lefthand corner. (b) The CD31 stain (same magnification) highlights the endothelial cells forming the lumen of the vascular channels. H&E stain, original magnification  $\times 52$ .

malignant lymphomatosis), although this was previously called malignant RAE.

Acroangiokeratosis of Mali may occur in severe stasis dermatitis and has similar histopathological features to pseudo-Kaposi secondary to venous hypertension (4, 5). Oedema is often seen, in contrast to the atrophy of RAE. These changes can also arise with congenital arteriovenous malformations of the lower extremities (Stewart-Bluefarb syndrome) (6).

Diffuse dermal angiomas has initially been described as a rare variant of RAE in the lower extremities of patients with severe peripheral vascular arteriosclerotic disease (7). Histology showed diffuse proliferation of endothelial cells interstitially arranged between collagen bundles of the reticular dermis, rather than endoluminal as in RAE. More recently, a case of diffuse dermal angiomas of the breast unrelated to arteriosclerosis was reported, which responded to isotretinoin (8).

Histopathological features support the diagnosis of diffuse dermal angiomas rather than pseudo-Kaposi in our patient.

Complications of arteriovenous fistulae include poor flow, ischaemia, gangrene, thrombosis, false aneurysms, infection and venous hypertension of the hand (9).

RAE is rarely seen, with only two cases reported previously. Both had an iatrogenic arteriovenous fistula leading to a steal phenomenon and RAE (one intravascular RAE and the other diffuse dermal angiomas). No drug treatment was attempted, but the skin cleared following reversal of the fistulae (10).

In situations of local hypoxia, as for example caused by arteriovenous steal, a local increase of vascular endothelial growth factor may cause the endothelial proliferation (11–14). Corticosteroids have anti-angiogenic properties and affect vascular endothelial growth factor expression (15). This may explain this patient's response to an increased dose of prednisolone.

## REFERENCES

- Martin S, Pitcher D, Tschien J, Wolf JE. Reactive angioendotheliomatosis. *J Am Acad Dermatol* 1980; 2: 117–123.
- McMenamin M, Fletcher C. Reactive angioendotheliomatosis: a study of 15 cases demonstrating a wide clinicopathologic spectrum. *Am J Surg Pathol* 2002; 26: 685–697.
- Daoud MS, Gibson LE, DeRemee RA, Specks U, el-Azhary RA, Su WP. Cutaneous Wegener's granulomatosis: clinical, histopathologic, and immunopathologic features of 30 patients. *J Am Acad Dermatol* 1994; 31: 605–612.
- Mali JW, Kuiper JT, Hamers AA. Acro-angiokeratosis of the foot. *Arch Dermatol* 1965; 92: 515–518.
- Headley JL, Cole GW. The development of pseudo-Kaposi's sarcoma after placement of a vascular access graft. *Br J Dermatol* 1980; 102: 327–331.
- Bluefarb SM, Adams LA. Arteriovenous malformation with angiokeratosis: stasis dermatitis simulating Kaposi's disease. *Arch Dermatol* 1967; 96: 176–181.
- Krell JM, Sanchez RL, Solomon AR. Diffuse dermal angiomas: a variant of reactive cutaneous angioendotheliomatosis. *J Cutan Pathol* 1994; 21: 363–370.
- McLaughlin ER, Morris R, Weiss SW, Arbiser JL. Diffuse dermal angiomas of the breast: response to isotretinoin. *J Am Acad Dermatol* 2001; 45: 462–465.
- Haimov M, Baez A, Neff M, Slifkin R. Complications of arteriovenous fistulas for hemodialysis. *Arch Surg* 1975; 110: 708–712.
- Requena L, Farina Ma C, Renedo G, Alvarez A, Yus ES, Sanguenza OP. Intravascular and diffuse dermal reactive angioendotheliomatosis secondary to iatrogenic arteriovenous fistulas. *J Cutan Pathol* 1999; 26: 159–164.
- Dvorak HF, Brown LF, Detmar M, Dvorak AM. Vascular permeability factor/vascular endothelial growth factor, microvascular hyperpermeability, and angiogenesis. *Am J Pathol* 1995; 146: 1029–1039.
- Banai S, Shweiki D, Pinson A, Chandra M, Lazarovici G, Keshet E. Up-regulation of vascular endothelial growth factor expression induced by myocardial ischaemia. Implications for coronary angiogenesis. *Cardiovasc Res* 1994; 24: 1176–1179.
- Peer J, Shweiki, Itin A, Hemo I, Gnessin H, Keshet E. Hypoxia-induced expression of vascular endothelial growth factor by retinal cells is a common factor in neovascularizing ocular diseases. *Lab Invest* 1995; 72: 638–645.
- Ferrara N. Vascular endothelial growth factor. *Eur J Cancer* 1996; 32A: 2413–2433.
- Nauck M, Karakiulakis G, Perruchoud AP, Papakonstantinou E, Roth M. Corticosteroids inhibit the expression of vascular endothelial growth factor gene in human vascular smooth muscle cells. *Eur J Pharmacol* 1998; 341: 309–315.