

## CLINICAL REPORT

# Drug-Induced Hypersensitivity Syndrome Associated with Cytomegalovirus Reactivation: Immunological Characterization of Pathogenic T Cells

Hideo HASHIZUME and Masahiro TAKIGAWA

*Department of Dermatology, Hamamatsu University School of Medicine, Hamamatsu, Japan*

**We report a case of tribenoside-induced hypersensitivity syndrome associated with cytomegalovirus reactivation and investigation of the immunological characteristics of the circulating and skin-infiltrating lymphocytes. Activated CD8<sup>+</sup> T cells outnumbered CD4<sup>+</sup> cells in both the circulation and the skin lesions. Upon *in vitro* stimulation with the drug, CD4<sup>+</sup> cells proliferated and produced interferon- $\gamma$ . The circulating CD8<sup>+</sup> cells used limited T-cell receptor V $\beta$ s, some of which are restricted to cytomegalovirus-derived peptide in the context of the HLA-A2 haplotype. CD8<sup>+</sup> cells and cytomegalovirus-containing cells closely co-localized in the skin lesions. These results suggested that CD4<sup>+</sup> cells were drug-reactive, whereas cytomegalovirus activated CD8<sup>+</sup> cells in the present case. These two cell types seemed to play a distinct role in drug-induced hypersensitivity syndrome. Key words: drug-induced hypersensitivity syndrome; cytomegalovirus; T cell.**

(Accepted August 9, 2004.)

Acta Derm Venereol 2005; 85: 47–50.

Hideo Hashizume, Department of Dermatology, Hamamatsu University School of Medicine, 1-20-1 Handa-yama, Hamamatsu, 431-3192, Japan. E-mail: hihashiz@hama-med.ac.jp

Drug-induced hypersensitivity syndrome (DIHS) is characterized by lymphadenopathy, fever, generalized rash, circulating atypical lymphocytes, blood eosinophilia and multiple organ dysfunction (1). Human herpes virus (HHV)-6/7 (2) and cytomegalovirus (CMV) (3) are often transiently reactivated during the course of DIHS. As T cells not only mediate the inflammatory response in the majority of drug allergies, but also interact with virus-infected cells, special contribution of different T-cell populations to the pathogenesis of DIHS is suggested.

We here report for the first time a case of tribenoside-induced DIHS with cytomegalovirus reactivation and analysis of the immune function of activated CD4<sup>+</sup> and CD8<sup>+</sup> T-cell subsets.

Tribenoside, ethyl 3,5,6-tri-O-benzyl-D-glucoside (MW 478.59), is a polysaccharide with anticoagulant and inhibitory action against inflammatory

mediators including histamine and prostaglandins, providing improvement of microcirculation and oedema, and is used in several countries including Japan, Italy, German and Switzerland for treatment of haemorrhoids, chronic venous insufficiency, or arthritis.

## CASE REPORT

A 49-year-old man was given tribenoside 600 mg/day (Hemoza<sup>®</sup>, Jdorph Co, Ltd, Shiga, Japan) for pain relief after an operation for haemorrhoids. Thirty-seven days after the operation, he took acetaminophen 300 mg/day for 5 successive days due to sore throat. He then developed a skin rash appearing on the extremities, and spreading to all body regions accompanied by fever. Both drugs were discontinued. While the rash faded and the temperature fell to normal levels within 7 days, erythroderma and fever relapsed together with white blood cells of more than  $30.0 \times 10^9/l$  with appearance of atypical lymphocytes ( $0.8 \times 10^9/l$ ). Erythematous macules, papules, and petechiae were apparent (Fig. 1A). No enanthema was observed. There was fever of 38.5°C and cervical and axillar lymphadenopathy without tenderness. A white cell count showed  $32.8 \times 10^9/l$  with 18% of eosinophils and 25% of atypical large lymphocytes. Liver enzymes were 5–10-fold above normal range and CRP was 0.8 mg/dl (0–0.1). HLA haplotypes of the patient were A2/33, B46/44, Cw1 and DR6/8. Chest X-roentgenograms and abdominal ultrasonograms were normal. Re-arrangement of T-cell receptor (TCR) V $\beta$  or IgH chain genes was not detected by Southern blot analysis. DIHS was diagnosed and all drugs were discontinued. The eruption completely disappeared on prednisolone 50 mg/day for 16 days following tapering over 10 weeks.

Titres of anti-cytomegalovirus IgG and IgM antibodies were 23.2 (normal, <0.4) and 0.43 (normal, <0.8), on admission, and >128 and 1.97 on the 42nd day, and >128 and 0.75 on the 60th day, respectively, indicating a reactivation of CMV. Titres of IgG antibodies against Epstein–Barr virus (EBV), HHV-6 and HHV-7 were unchanged during the observation period. Patch tests performed after recovery were positive with tribenoside, but negative with acetamino-

phen. Lymphocyte stimulation tests (4) with tribenoside and acetaminophen were positive (stimulation index, > 1.8). Based on these observations, the causative drug was most likely tribenoside, although both drugs might contribute to the clinical manifestations.

## MATERIAL AND METHODS

The patient gave informed consent to the immunological investigations. Blood was drawn on day 8, when he had all symptoms, and on day 72 when he was symptom-free. Peripheral blood mononuclear cells (PBMCs) and blastoid cells corresponding to atypical large lymphocytes were isolated as described previously (5). Lymphocyte proliferation assay with tribenoside or acetaminophen and subsequent 5,6-carboxy-fluorescein diacetate succinimidyl ester (CFSE) staining were performed according to the methods described previously (4). All cultures contained autologous EBV-transformed lymphoblastoid B-cell lines as antigen-presenting cells to stimulate T cells with the drug.

A panel of 22 fluorescence-isothiocyanate (FITC)-labelled monoclonal antibodies (MoAbs) recognizing different TCR V $\beta$  gene products, a V $\alpha$  $\beta$  common frame, and MoAbs against interleukin (IL)-4, IL-5 and interferon (IFN)- $\gamma$  were obtained from PharMingen (Sorrento Valley, CA, USA); FITC-labelled anti-CD3 (SK7), anti-CD4 (SK3) and anti-CD8 (SK1) MoAbs, and phycoerythrin (PE)-labelled anti-HLA-DR (TU36), anti-CD25 (2A3) and anti-CD69 (L78) MoAbs from Beckton Dickinson (San Jose, CA, USA); and an anti-granzyme B MoAb from Pharmacia, Paris France. More than  $5 \times 10^4$  cells per sample were stained with fluorescent-conjugated antibodies and were analysed in a FACScaliber flow cytometer (Beckton Dickinson Biosciences, Heidelberg, Germany) by gating the lymphocyte subpopulation. Intracytoplasmic cytokine staining was performed with Cytofix/Cytoperm Plus (Beckton Dickinson Biosciences) according to the manufacturer's protocol. Results were analysed using FlowJo software (TreeStar, San Carlos, CA, USA).

One half of a 4- $\mu$ m skin punch biopsy specimen was stained with haematoxylin-eosin and the other was processed for immunohistochemistry. Four- $\mu$ m thick sections were incubated with primary MoAbs, and then with appropriate alkaline phosphatase-conjugated secondary antibodies. Fuchsin red was used for visualization. Nuclei were stained with haematoxylin. Substitution of the isotype-matched primary antibody or omission of the primary antibody served as control. The UltraSensitive Enhanced fluorescent streptavidin *in situ* detection system and PathoGene (Enzo Diagnostics, Farmingdale, NY, USA) were employed to detect the cytomegalovirus DNA genome in lesional skin and PBMCs according to the manufacturer's protocol.

## RESULTS

The skin histology disclosed lichenoid reactions including dense perivascular infiltration and exocytosis of lymphocytes with a large and condensed nucleus. Immunohistochemistry revealed that CD8+ cells infiltrated throughout the dermis and the epidermal-dermal junction (Fig. 1B), and CD4+ cells focally around vessels in the mid dermis, being less prominent than CD8+ cells. On the other hand, more CD4+ cells than CD8+ cells infiltrated in the dermis at the positive

site of the patch test. Granzyme B was found in about 20% of the infiltrating cells at the upper dermis (not shown).

The phenotype and TCR V $\beta$  usage of blastoid cells showed that 40% and 60% of the cells were positive for CD4 and CD8, respectively. HLA-DR molecules and CD25 were expressed in about 90% and 10% among the CD8+ cell fraction, and in about 90% and 40% among the CD4+ cell fraction. These values were comparable to those of fresh PBMCs obtained at the height of the disease. Cells bearing TCR V $\beta$ s 5.1 (4.8%), 5.3 (1.2%), 6.7 (3.7%) and 14 (4.0%) were increased in number by more than threefold among the CD8+ blastoid cell fraction compared with the same fraction at the recovery phase (1.6%, 0.3%, 1.0% and 1.3%, respectively, among PHA-stimulated PBMC obtained after recovery, of which V $\beta$  usage was presumed to be in the patient's healthy status). No apparent increase of particular TCR V $\beta$ + cells was noted in the CD4+ blastoid cell fraction.

The patient's lymphocytes showed maximum proliferation in response to 40 and 400 ng/ml of tribenoside, which then were used. Stimulation of PBMC with tribenoside after recovery increased CD4+ cells bearing V $\beta$ s 1 (15.6%), 6.7 (20.9%) and 16 (1.9%) by more than ninefold as compared with those obtained at the recovery phase (0.9%, 2.6% and 0.2% among the CD4+ population, respectively), but did not enhance the particular V $\beta$  usage in CD8+ cells. Furthermore, CFSE staining analysis disclosed that percentages of dividing CD4+ cells were  $6.0 \pm 0.4\%$  with tribenoside (40 ng/ml) and  $1.1 \pm 0.5\%$  with medium alone ( $p < 0.01$ , t-test) after 7-day cultivation. Only 1.9% of CD8+ cells proliferated in response to the drug. These results indicate that certain TCR V $\beta$ -bearing CD4+ cells proliferated following stimulation with the drug, not CD8+ cells. About 3% of the CD4+ blastoid population spontaneously produced both IFN- $\gamma$  and IL-4 and the IFN- $\gamma$  production was augmented by the addition of either anti-CD3 MoAb or the drug to the culture, but did not lead to increased IL-4. In contrast, CD8+ blastoid cells spontaneously produced IL-4, but not IFN- $\gamma$ . These cells, although they responded to anti-CD3 MoAb, did not produce significant levels of cytokines by drug stimulation.

Because of high anti-CMV antibody titres, and a massive expansion of CD8+ cells in peripheral blood and a predominant infiltration of CD8+ cells in skin lesions, the CMV genome was sought in the lesional skin and PBMCs at the height of the disease. About 5% of the cells infiltrating in the skin (Fig. 2A) and 5% of PBMC (Fig. 2B) had specific fluorescence, indicating the presence of the virus genome. There was no fluorescence of keratinocytes, fibroblasts, sweat glands in the skin lesion provoked by the patch test (data not shown).

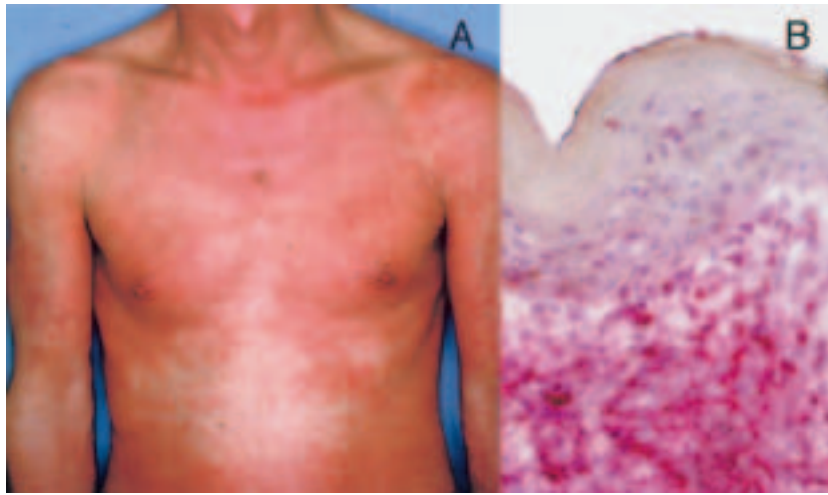


Fig. 1. Generalized erythema of the trunk (A) and CD8 expression of the lesion (B).

## DISCUSSION

DIHS is distinguished from other types of drug hypersensitivity by high fever, extensive skin rash and organ involvement, close association with herpes virus reactivation, and a limited number of causative drugs including anticonvulsants, diaphenylsulfone, salazosulfapyridine, allopurinol, minocycline, calcium blockers, terbinafine and mexiletine (6). Tribenoside provides anti-inflammatory, mild analgesic and fibrinolysis-promoting effects and is often used in the treatment of haemorrhoids in Japan. The present case was diagnosed as DIHS because of the fulfilment of the criteria (1), typical two waves of the disease activity and high titres of CMV antibodies, indicating CMV reactivation. DIHS usually occurs from 10 days up to 8 weeks after the first exposure to the drug, and in the present case, tribenoside seemed to be a causative agent as it was used for 38 days and gave a positive patch test. Acetaminophen was

only given for 5 days and provided a negative patch test. Possible involvement of the co-operating effect by these drugs, however, could not be eliminated.

In the present case, activated CD8+ T cells outnumbered CD4+ T cells in the circulation and the skin histology, suggesting a special role of this subset for the inflammation processes. Drug-reactive CD8+ cells with cytotoxic molecules such as perforin and granzyme A/B are involved in tissue damage including epidermal necrosis, liver dysfunction (4, 7, 8) and other organ failure in severe drug eruptions such as Stevens-Johnson syndrome (SJS) and toxic epidermal necrolysis (TEN) (4, 9). However, CD8+ cells in the present case seemed to be different from those in SJS/TEN in their immunological activity. First, despite marked skin infiltration of granzyme B+ cells, extensive epidermal necrosis was absent in the skin histology. Second, CD8+ cells did not proliferate and produced IL-4 or IFN- $\gamma$  after *in vitro* stimulation with the drug. These observations raise the possibility that CD8+ cells reacted with molecules other than drug-derived antigen and had poorly cytotoxic potential. Indeed, the activated CD8+ cells in the circulation preferentially expressed V $\beta$ s 5.1, 5.3, 6.7 and 14; the latter two V $\beta$ s are preferentially expressed by CMV-derived pp65-reactive cutaneous T lymphocytes in the context of HLA-A2 (10, 11), the same haplotype as our patient. Furthermore, there was a close association between the virus genome positive cells and CD8+ cells containing granzyme B in the lesional skin. The CMV+ cells in the skin seemed to be monocytes/macrophages, because they were large and round/polygonal in shape compared with lymphocytes, and CMV latently infects CD14+ cells of the peripheral blood (12). These results supported the notion that the CD8+ cells targeted the infected cells. The CD4+ cells bearing particular V $\beta$ s proliferated and produced IFN- $\gamma$  in response to tribenoside, suggesting that they had a Th1 type, whereas blastoid CD8+ cells in the circulation

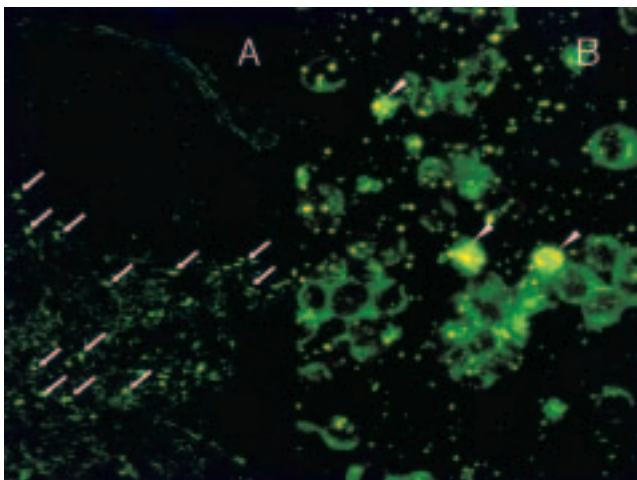


Fig. 2. *In situ* hybridization analysis for cytomegalovirus DNA detection in the skin lesions (A) and peripheral blood mononuclear cells (B).



produced IL-4, but not IFN- $\gamma$  by polyclonal stimulation, implicating that they were of Tc2 type. We did not assess the cytotoxic function of the CD8+ cells against CMV-infected target cells, however, as Tc2 cells ineffectively repress virus proliferation.

Typically, two waves of the skin activity occur during the course of DIHS (1, 14), papulo-macular rash and high fever start, and then extensive cutaneous inflammation occurs concomitant with atypical lymphocytosis and lymphadenopathies. These two waves seem to reflect correspondingly predominant CD4+ and CD8+ cell infiltrations in the upper dermis of the provoked and the developed lesions, respectively. Our findings propose a scenario where pathogenic CD4+ cells played a role in initiating the drug-induced immune response, and CD8+ cells were subsequently activated in association with reactivation of a latent infection of CMV to amplify inflammatory responses in DIHS.

In conclusion, the distinctive role of CD4+ and CD8+ T cells in the present case was shown by (i) predominant appearance of circulating CD8+ cells bearing TCR V $\beta$ s recognizing CMV-derived antigenic peptide, (ii) expansion of CD4+ T cells bearing particular TCR V $\beta$ s and their production of IFN- $\gamma$  in response to the drug, and (iii) close association between CMV-infected cells and CD8+ cells, but not CD4+ cells, in the lesion, indicating that the majority of CD8+ T cells were activated with peptides derived from CMV-infected cells in parallel with stimulation of CD4+ T cells with the drug during the course.

#### ACKNOWLEDGEMENT

This work was supported in part by a grant from Science Research Foundation Ministry of Education, Culture, Sports, Science and Technology in Japan (15591173-00).

#### REFERENCES

1. Sullivan JR, Shear NH. The drug hypersensitivity syndrome: what is the pathogenesis? *Arch Dermatol* 2001; 137: 357–364.
2. Suzuki Y, Inagi R, Aono T, Yamanishi K, Shiohara T. Human herpesvirus 6 infection as a risk factor for the

development of severe drug-induced hypersensitivity syndrome. *Arch Dermatol* 1998; 134: 1108–1112.

3. Arakawa M, Kakuto Y, Ichikawa K, Chiba J, Tabata N, Sasaki Y. Allopurinol hypersensitivity syndrome associated with systemic cytomegalovirus infection and systemic bacteremia. *Intern Med* 2001; 40: 331–335.
4. Hashizume H, Takigawa M, Tokura Y. Characterization of drug-specific T cells in phenobarbital-induced eruption. *J Immunol* 2002; 168: 5359–5368.
5. Yagi J, Baron J, Buxser S, Janeway CA Jr. Bacterial proteins that mediate the association of a defined subset of T cell receptor:CD4 complexes with class II MHC. *J Immunol* 1990; 144: 892–901.
6. Roujeau JC, Stern RS. Severe adverse cutaneous reactions to drugs. *N Engl J Med* 1994; 10: 1272–1285.
7. Behrendt C, Gollnick H, Bonnekoh B. Up-regulated perforin expression of CD8+ blood lymphocytes in generalized non-anaphylactic drug eruptions and exacerbated psoriasis. *Eur J Dermatol* 2000; 10: 365–369.
8. Schnyder B, Frutig K, Mauri-Hellweg D, Limat A, Yawalkar N, Pichler WJ. T-cell-mediated cytotoxicity against keratinocytes in sulfamethoxazol-induced skin reaction. *Clin Exp Allergy* 1998; 28: 1412–1417.
9. Le Cleach L, Delaire S, Boumsell L, Bagot M, Bourgault-Villada I, Bensussan A, et al. Blister fluid T lymphocytes during toxic epidermal necrolysis are functional cytotoxic cells which express human natural killer (NK) inhibitory receptors. *Clin Exp Immunol* 2000; 119: 225–230.
10. Retiere C, Prod'homme V, Imbert-Marcille BM, Bonneville M, Vie H, Hallet MM. Generation of cytomegalovirus-specific human T-lymphocyte clones by using autologous B-lymphoblastoid cells with stable expression of pp65 or IE1 proteins: a tool to study the fine specificity of the antiviral response. *J Virol* 2000; 74: 3948–3952.
11. Keever-Taylor CA, Margolis D, Konings S, Sandford GR, Nicolette CA, Lawendowski C, et al. Cytomegalovirus-specific cytolytic T-cell lines and clones generated against adenovirus-pp65-infected dendritic cells. *Biol Blood Marrow Transplant* 2001; 7: 247–256.
12. Bolovan-Fritts CA, Mocarski ES, Wiedeman JA. Peripheral blood CD14(+) cells from healthy subjects carry a circular conformation of latent cytomegalovirus genome. *Blood* 1999; 93: 394–398.
13. Maggi E, Manetti R, Annunziato F, Cosmi L, Giudizi MG, Biagiotti R, et al. Functional characterization and modulation of cytokine production by CD8+ T cells from human immunodeficiency virus-infected individuals. *Blood* 1997; 89: 3672–3681.
14. Hashimoto K, Yasukawa M, Tohyama M. Human herpesvirus 6 and drug allergy. *Curr Opin Allergy Clin Immunol* 2003; 3: 255–260.