

Detection of Human Papillomavirus Type 16 in Bowen's Disease of the Web-space of the Foot

Junko Goshima¹, Hiroyuki Hara¹, Ayano Honda¹, Hiroyuki Suzuki¹ and Toshihiko Matsukura²

¹Department of Dermatology, Nihon University School of Medicine, 30-1 Oyaguchi-kamimachi, Itabashi-ku, Tokyo 173-0032, Japan, and ²Department of Virology II, National Institute of Infectious Diseases, Tokyo 162-8640, Japan. E-mail: urahashi@med.nihon-u.ac.jp

Accepted July 19, 2004.

Sir,

Recent studies have identified various types of human papillomavirus (HPV) in Bowen's disease (BD) on the hands and feet, especially at periungual and subungual sites (1, 2). BD represents a squamous cell carcinoma *in situ*. HPV 16 and other 'high risk' types have frequently been identified as in genital BD. Only two cases of BD on the web-spaces of the foot have been reported (3, 4). We describe a case of BD arising in the web-space of the foot associated with HPV 16.

CASE REPORT

A 33-year-old Japanese man had observed a brownish macule on his left foot for 1 year. He had previously been treated for tinea pedis with topical antifungal agents. Physical examination revealed a brownish, relatively well demarcated macule, 7 × 3 mm in diameter, in the web-space between the third and fourth toes of his left foot (Fig. 1a). A skin-coloured, keratotic papule was observed adjacent to the brownish macule. He had no history of genital disorders such as bowenoid papulosis or condyloma acuminatum. Histopathological examination of a skin biopsy revealed proliferation of irregularly arranged atypical keratinocytes throughout the epidermis, hyperkeratosis with dyskeratotic, clumping cells and mitotic figures (Fig. 1b). A diagnosis of BD was made. Fontana-Masson staining showed an increased amount of melanin in the basal layer and numerous pigment-filled dendritic melanocytes in the lesion. Melanophages were also prominent in the upper dermis. The HPV capsid antigen was detected by immunohistochemical analysis (K1H8, Dako, Kyoto, Japan). Southern blot hybridization was employed to detect HPV DNA and determine the HPV genotype. The cleavage patterns of the lesion were similar to those of prototype HPV 16 (Fig. 1c). The lesion was surgically removed and no relapse was observed after 1 year.

DISCUSSION

Our case is clinically characterized by a very small, brownish and keratotic macule on the web-space of the patient's left foot. Histopathological findings were compatible with those of BD. Pigmentation was caused by the presence of pigment-filled melanocytes, a large

amount of melanin in the basal layer and prominent melanophages in the upper dermis. HPV 16 DNA was identified in the lesion.

Over 90 HPV genotypes have been characterized. HPV 16 was first found in extragenital BD in 1983 (5), and subsequently also in BD of the hands and feet (2).

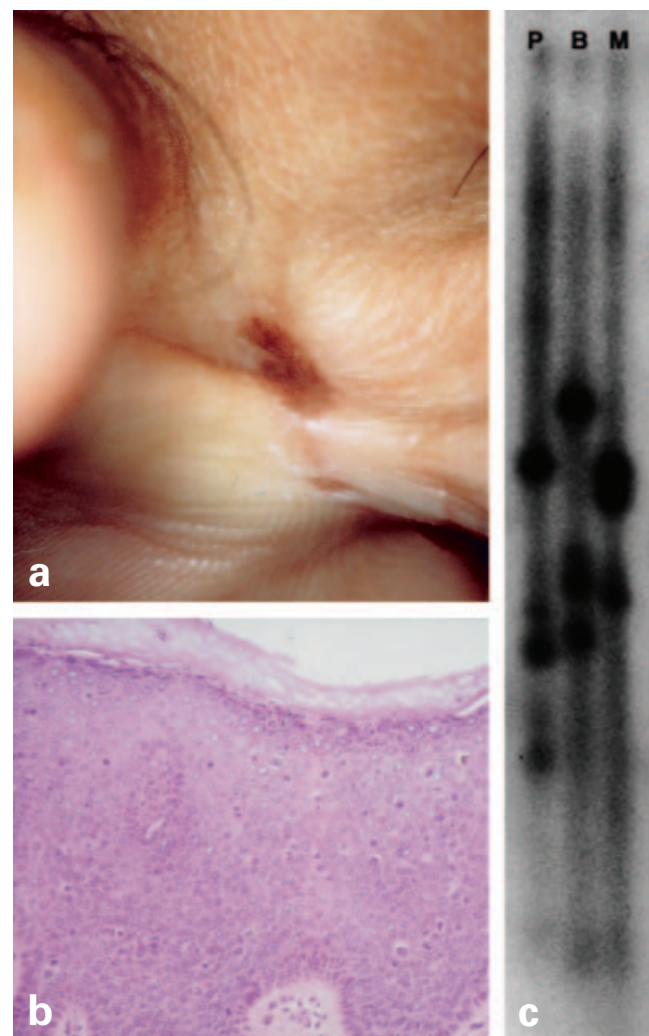


Fig. 1. (a) Well-demarcated pigmented macule in the web-space between the third and fourth toes of the left foot. (b) Proliferated atypical keratinocytes throughout the epidermis, with hyperkeratosis, dyskeratotic cells, clumping cells and mitotic figures (haematoxylin-eosin stain; original magnification × 100). (c) Detection of human papillomavirus 16 DNA in the lesion by Southern blot hybridization. The DNA was digested with several restriction enzymes: *Pst*I (P), *Ban*I (B) and *Msp*I (M).

HPV 16 is the type most often found in cervical intraepithelial neoplasia grade III (CIN III) or invasive cervical carcinoma (6). Since BD histopathologically corresponds to CIN III, it is assumed that specific genital HPVs may induce the same histological lesions both on the skin and in the genital region. In some reported cases, the same HPV type has been found in BD both on the skin and in the genital lesions of the same patient (7, 8). Thus, it is assumed that the viral transmission occurs via a genital-digital route in the development of extragenital BD (8). Our patient was not aware of genital lesions such as bowenoid papulosis or condyloma acuminatum, but had a history of tinea pedis. The scratching may result in autoinoculation of HPV into the skin. His lesion may thus be related to HPV inoculation or environmental trauma.

The occurrence of BD in the web-spaces of the feet has been rarely reported (3, 4). Burns (3) described a patient with multiple pigmented, warty macules in the web-spaces of both feet; however, a virological investigation was not conducted. Stones et al. (4) described a patient with hyperkeratotic plaques on the dorsal surface and interdigital spaces over the second, third and fourth toes of both feet and detected HPV 16 DNA in the tissue using Southern blot hybridization. These three cases including our own had similar clinical features with pigmented, hyperkeratotic macules. However, the previously described lesions have been multiple, well circumscribed and verrucous plaques (3, 4), a type also described by Kettler et al. (9).

REFERENCES

1. Mitsuishi T, Sata T, Matsukura T, Iwasaki T, Kawashima M. The presence of mucosal human papillomavirus in Bowen's disease of the hands. *Cancer* 1997; 79: 1911–1917.
2. Clavel CE, Huu VP, Durlach AP, Birembaut PL, Bernard PM, Derancourt CG. Mucosal oncogenic human papillomaviruses and extragenital Bowen's disease. *Cancer* 1999; 86: 282–287.
3. Burns DA. Bilateral pigmented Bowen's disease of the web-space of the feet. *Clin Exp Dermatol* 1981; 6: 435–437.
4. Stones MS, Noonan CA, Tschen J, Bruce S. Bowen's disease of the feet. *Arch Dermatol* 1987; 123: 1517–1520.
5. Ikenberg H, Gissmann L, Gross G, Grussendorf-Conen E-I, zur Hausen H. Human papillomavirus type 16-related DNA in genital Bowen's disease and bowenoid papulosis. *Int J Cancer* 1983; 32: 563–565.
6. Matsukura T, Sugase M. Relationship between 80 human papillomavirus genotypes and different grades of cervical intraepithelial neoplasia: association and causality. *Virology* 2001; 283: 139–147.
7. Forslund O, Nordin P, Andersson K, Stenquist B, Hansson BG. DNA analysis indicates patient-specific human papillomavirus type 16 strains in Bowen's disease on fingers and in archival samples from genital dysplasia. *Br J Dermatol* 1997; 136: 678–682.
8. Nordin P, Stenquist B, Hansson BG. Joint occurrence of human papillomavirus type 16 DNA in Bowen's disease on a finger and in dysplasia of the vulva and the uterine cervix. *Br J Dermatol* 1994; 131: 740.
9. Kettler AH, Rutledge M, Tschen JA, Buffone G. Detection of human papillomavirus in nongenital Bowen's disease by in situ DNA hybridization. *Arch Dermatol* 1990; 126: 777–781.