

CLINICAL REPORT

Metastatic Crohn's Disease Mimicking Genital Pyoderma Gangrenosum in an HIV Patient

José Antonio AVILÉS-IZQUIERDO, Ricardo SUÁREZ-FERNÁNDEZ, Pablo LÁZARO-OCHAITA and M. Isabel LONGO-IMEDIO

Department of Dermatology, Gregorio Marañón University Hospital, Madrid, Spain

The differential diagnosis of ulcerative genital lesions in patients with high risk sexual habits can be a challenge even for dermatologists. We present the case of a 27-year-old HIV-positive male with a history of recalcitrant genital ulcers. Microbiology studies were negative. A skin biopsy and a sample from a perineal fistula showed granulomatous infiltrates. The patient was treated with prednisone, metronidazole and aminosalicylates, showing complete resolution of the lesions in a few weeks. The clinical picture and histological findings are consistent with the diagnosis of cutaneous metastatic Crohn's disease. Although infrequent, metastatic Crohn's disease should be suspected in cases of recalcitrant ulcerative conditions, even in the absence of intestinal disease. Key words: metastatic Crohn's disease; chronic genital ulcer; pyoderma gangrenosum.

(Accepted June 22, 2004.)

Acta Derm Venereol 2005; 85: 60–62.

M. Isabel Longo-Imedio, Department of Dermatology, Gregorio Marañón Hospital, C/ Dr Esquerdo 46, ES-28007, Madrid, Spain. E-mail: milongo@arrakis.es

The diagnosis of genital lesions in patients with a medical history of multiple sexually transmitted diseases is challenging in the presence of immunosuppression. Once a sexually transmitted infection has been excluded, many other entities must be studied depending on the time of evolution. For acute conditions drug eruptions and trauma must be considered. Likewise, neoplasms and cutaneous manifestations of internal diseases must be investigated in cases of chronic evolution. Crohn's disease is an inflammatory bowel disease (IBD) of unknown aetiology that is sometimes associated with cutaneous manifestations. These skin lesions are usually clinically and histologically nonspecific, and include pyoderma gangrenosum and erythema nodosum. Rarely, Crohn's disease can actually occur in the skin, an entity known as metastatic Crohn's disease. The diagnosis of metastatic Crohn's disease is supported by the histological findings of non-caseating granulomas. Extraintestinal Crohn's disease and its associated conditions could be the first symptom of IBD and all of them have a good response to therapies targeted for Crohn's disease.

CASE REPORT

A 27-year-old man was referred with a history of ulcers on the dorsum of the penis and scrotum of several months' duration. He had a medical history of multiple sexually transmitted infections including syphilis, scabies, gonorrhoea, hepatitis B and HIV, and long-standing perineal abscesses and fistulae. Before referral he was empirically treated with antibiotics (tetracyclines and macrolides) and antiviral drugs (acyclovir) without improvement. Previous examinations included swab and skin biopsy cultures for bacteria, fungi, viruses (herpes simplex, herpes zoster) and mycobacteria as well as bacterial and viral serology; all were negative. Repeated direct immunofluorescence tests for herpes virus were also negative. Additional tests showed a high erythrocyte sedimentation rate, leukocytosis and a non-haemolytic microcytic anaemia.

Physical examination showed a deep ulcer with a fibrinous base in the dorsum of the penis (Fig. 1a), and another similar smaller ulcer in the scrotum. Both lesions were tender. Small, non-tender, bilateral inguinal adenopathies and purulent perineal fistulae were also observed.

As an inflammatory dermatosis was suspected, a skin biopsy was performed. Histopathological findings were non-specific, but showed non-caseating granulomatous infiltrates of histiocytes, neutrophils and giant cells (Fig. 2).

A colonoscopy was performed to rule out subclinical IBD, which was negative. The only gastrointestinal findings corresponded to perineal fistulae and recurrent abscesses. A biopsy from one of the perineal lesions also showed non-caseating granulomas.

Based on the clinical and histological findings the patient was diagnosed as having Crohn's disease. He was treated with prednisone 30 mg o.d., metronidazole 500 mg t.i.d. and 5-aminosalicylic acid 3 g q.i.d., leading to a spectacular response. Within a few months, the genital ulcers were completely healed (Fig. 1b). Currently, the patient is on maintenance therapy with aminosalicylates and has been in remission for the past year.

DISCUSSION

Cutaneous Crohn's disease, also known as metastatic Crohn's disease, is a rare complication of Crohn's

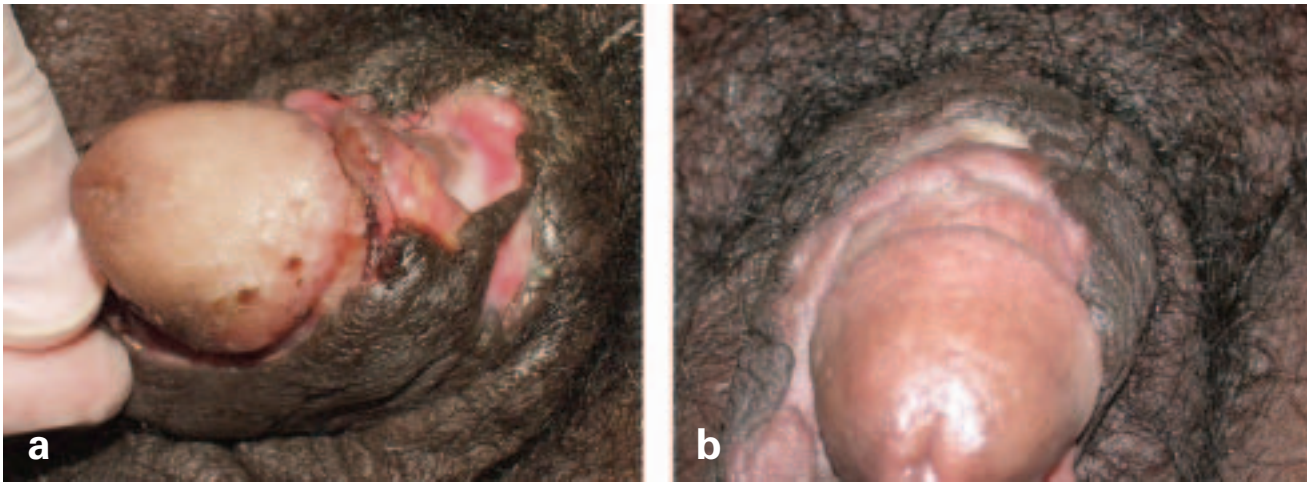


Fig. 1. (a) Deep ulcer with well-defined borders localized to the dorsum of the penis. (b) Healed lesions a few months later.

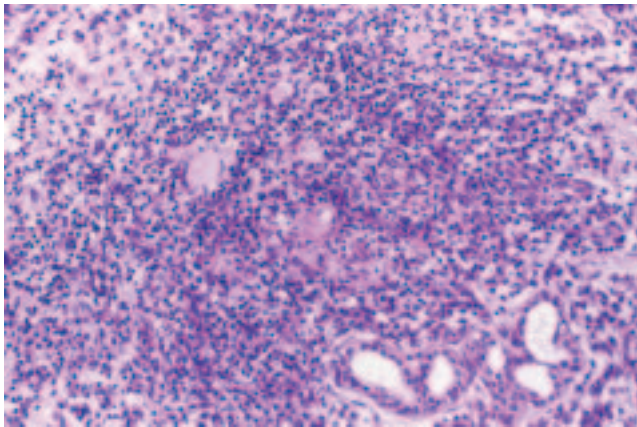


Fig. 2. Photomicrograph showing non-caseating granulomas in the dermis (magnification power $\times 120$).

disease in which granulomatous lesions involve skin separated from gastrointestinal lesions by normal tissue. Its clinical manifestations are heterogeneous, involving any part of the cutaneous surface (1).

Involvement of the genitalia in metastatic Crohn's disease is rare and consists of ulcerated lesions in almost all cases reported in the literature (2). Other rare presentations include vulvar, scrotal or prepuce oedema and erysipelas-like dermatosis (3–5). Its clinical course is usually independent from the intestinal disease (6).

Cutaneous disease may be the primary manifestation of Crohn's disease and it may appear several years before intestinal symptomatology develops. Perianal lesions consisting of perianal abscesses and anal fistulae are relatively common in Crohn's disease and are observed in 15–50% of cases (7). Indeed, fistulae are frequently the first manifestation of Crohn's disease and may precede bowel disease by several years (8). Our patient had a history of non-infectious recurrent perianal abscesses and anal fistulae.

Although chronic Crohn's disease lacks definitive histopathological criteria (9), most cases show non-caseating or sarcoidal granulomas with an associated superficial and deep perivascular mixed inflammatory cell infiltrate (10).

Cutaneous lesions usually respond to metronidazole, mesalamine and prednisone (11). Due to recurrence of cutaneous lesions as prednisone dose is tapered, some patients require maintenance therapy.

In the differential diagnosis of chronic genital ulcers, especially in HIV-positive patients, infectious causes must be rigorously excluded, as atypical presentations are not uncommon (12). The most frequent cause of genital ulceration is herpes simplex virus (HSV) infection. Chronic ulceration due to HSV of more than 1 month's duration is a diagnostic criterion for AIDS (13). Our patient had stage A HIV infection and repeated investigations such as biopsy, culture and direct immunofluorescence ruled out HSV infection. Other infectious causes of chronic genital ulcers include chancroid and granuloma inguinale. Chancroid is characterized by painful and multiple ulcers accompanied by lymphadenopathy. It is caused by *Haemophilus ducreyi* and is more frequent in developing countries. Diagnosis based on the clinical findings and exclusion of other micro-organisms can be confirmed by appropriate cultures. Granuloma inguinale is a rare infection mostly restricted to a few developing countries. It usually causes a non-tender chronic ulcer with extensive destruction. It is readily diagnosed by the demonstration of intracytoplasmic Donovan bodies, more frequently found in smears than within biopsies.

In the appropriate clinical setting other infectious causes of chronic genital ulceration such as tuberculosis should be excluded.

With respect to non-infectious causes of chronic genital ulceration one of the most important entities to rule out is pyoderma gangrenosum (PG), among others

such as neoplasms. PG is an uncommon neutrophilic dermatosis of uncertain aetiology. The clinical presentation varies but classically begins as a papulopustule that becomes necrotic and expands with minimal trauma. It has been reported in 0.5–20% of cases of Crohn's disease (14). PG in patients with arthritis and IBD is characterized by a slowly enlarging ulcer with extensive granulation tissue. PG may occur on the genitalia and has been termed vulvar or penile PG. This variant must be differentiated from sexually transmitted diseases. Histological findings are non-specific and vary with the age of the lesion and the clinical subtype of PG. In cases of PG associated with IBD, sulfasalazine and dapsone have been shown to be effective.

In the present case, we have described an HIV-positive patient with a non-infectious ulcerative chronic condition that posed the main differential diagnosis between PG and metastatic cutaneous Crohn's disease. Our patient has criteria favouring a diagnosis of Crohn's disease. Firstly, the clinical picture is consistent with Crohn's disease. Even though the patient did not present overt bowel symptoms, he had a history of recurrent non-infectious abscesses and anal fistulae, both conditions commonly encountered in patients with Crohn's disease. Secondly, the lesions of PG are more commonly found in the extremities and, when associated with IBD, the ulcers tend to show exuberant granulation tissue, a characteristic not present in our patient. Thirdly, the histological study demonstrated granulomatous infiltrates which are consistent with Crohn's disease.

Based on all of the above a diagnosis of Crohn's disease was favoured and the patient was treated with prednisone, metronidazole and aminosalicylates, showing complete clearance of the lesions in a few weeks.

Metastatic Crohn's disease should be suspected in any ulcerative condition with torpid evolution, even if intestinal symptoms are not evident at the time of presentation.

REFERENCES

1. Biancone L, Geboes K, Spagnoli LG, Del Vecchio Blanco G, Monteleone I, Vavassori P, et al. Metastatic Crohn's disease of the forehead. *Inflamm Bowel Dis* 2002; 8: 101–105.
2. Neri I, Bardaza F, Fanti PA, Guidetti MS. Penile Crohn's disease: a case report. *Genitourin Med* 1995; 71: 45–46.
3. Bel Pla S, Garcia-Patos Briones V, Garcia Fernandez D, Aparicio Espanol G, Castells Rodellas A. Vulvar lymphedema: unusual manifestation of metastatic Crohn's disease. *Gastroenterol Hepatol* 2001; 24: 297–299.
4. Bloget F, Bisiau S, Delaporte E, Mazeman E, Cortot A, Gosselin B. "Metastatic" Crohn's disease of the penis. *Ann Pathol* 1996; 16: 296–298.
5. Macaya A, Marcoval J, Bordas X, Moreno A, Vazquez S, Peyri J. Crohn's disease presenting as prepuce and scrotal edema. *J Am Acad Dermatol* 2003; 49: S182–S183.
6. Guest GC, Fink RL. Metastatic Crohn's disease: case report of an unusual variant and review of the literature. *Dis Colon Rectum* 2000; 43: 1764–1766.
7. McCallum DI, Kinmont PDC. Dermatological manifestations of Crohn's disease. *Br J Dermatol* 2000; 80: 1–8.
8. Fielding JF. Perianal lesions in Crohn's disease. *J R Coll Surg Edinb* 1972; 17: 32–37.
9. Hackzell-Bradley M, Hedblad MA, Stephansson EA. Metastatic Crohn's disease. Report of 3 cases with special reference to histopathologic findings. *Arch Dermatol* 1996; 132: 928–932.
10. Acker SM, Sahn EE, Rogers HC, Maize JC, Moscatello SA, Frick KA. Genital cutaneous Crohn disease: two cases with unusual clinical and histopathologic features in young men. *Am J Dermatopathol* 2000; 22: 443–446.
11. Gilson MR, Elston LC, Pruitt CA. Metastatic Crohn's disease: remission induced by mesalamine and prednisone. *J Am Acad Dermatol* 1999; 41: 476–479.
12. Czelusta A, Yen-Moore A, Van der Straten M, Carrasco D, Tying SK. An overview of sexually transmitted diseases. Part III. Sexually transmitted diseases in HIV-infected patients. *J Am Acad Dermatol* 2000; 43: 409–432.
13. Centers for Disease Control, 1993 Revised classification system for HIV infection and expanded surveillance case definition for AIDS among adolescents and adults. *MMWR Re-comm Rep* 1992; 41: 1–19.
14. Greenstein AJ, Janowitz HD, Sachat DB. The extra-intestinal complications of Crohn's disease and ulcerative colitis: a study of 700 patients. *Medicine (Baltimore)* 1976; 55: 401–412.