

INVESTIGATIVE REPORT

Demonstration of Polarizable Crystals in Fresh Comedonal Extracts: Sebum CrystallizesAldo GONZÁLEZ-SERVA^{1,2} and George KROUMPOUZOS^{3,4,5}¹Ameripath New England, Boston, ²Department of Dermatology, Tufts University School of Medicine, Boston, MA, ³Dermatology Clinic, South Shore Medical Center, Norwell, ⁴Department of Medicine, South Shore Hospital, South Weymouth and ⁵Division of Dermatology, Worcester Medical Center, Worcester, MA, USA

Previous studies using paraffin-embedded sections showed the presence of varying degrees of lipidic calculus (sebolith) formation in the pilosebaceous duct in acne comedonal lesions. The objective of this study was to examine the content of fresh acne comedonal extracts and pustules in polarizable crystalline material. Furthermore, to investigate if the amount of crystalline material correlates with the morphology, evolutionary stage, age and location of the comedone we performed polariscopic examination of 20 fresh acne comedonal extracts and 6 acne pustules. As controls, we used extracts from solar comedones, milia and epidermal inclusion cysts, follicular extracts from acne rosacea lesions, pustules of bacterial folliculitis and extracts from normal follicles from acne-prone individuals. The vast majority of acne comedones contained considerable amounts of polarizable crystalline material. Crystallization was more prominent in closed comedones, long-standing macrocomedones and conglobate comedones. Crystal formation was seen less commonly ($p < 0.01$) in solar comedones, milia and epidermal inclusion cysts. As shown in this study, crystallization of sebum is a common element of comedogenesis and may possibly contribute to comedo preservation. **Key words:** polarization; birefringence; comedone; sebum; sebolith.

(Accepted May 21, 2004.)

Acta Derm Venereol 2004; 84: 418–421.

George Kroumpouzou, 9 Hawthorne Place, Suite 6D, Boston, MA 02114, USA. E-mail: george.kroumpouzou@GKderm.com

Previous studies (1) using paraffin-embedded sections showed the existence of a lipidic calculus (sebolith) in the pilosebaceous duct in comedonal acne lesions (Fig. 1, left). The calculus was often birefringent on polariscopic examination (Fig. 1, right). It was suggested that sebolith formation may favour comedo preservation and enlargement (2) with subsequent dilatation of the pilosebaceous duct. In paraffin-embedded sections there was no evidence of calcium deposits or solvent-labile urate crystals within the birefringent crystalline material. *Propionibacterium*

acnes was often seen near or on the crystalline aggregates. To further investigate the above observation we performed polariscopic microscopic examination in fresh acne comedonal extracts and pus compared to various other follicular conditions.

PATIENTS AND METHODS

Examination was performed in 20 fresh acne comedonal extracts and 6 acne pustules from 26 patients (12 females and 14 males). We also performed polariscopic examination of extracts from solar comedones (Favre-Racouchot disease), epidermal inclusion cysts, milia, follicles from lesions of acne rosacea, pustules of bacterial folliculitis and normal follicles from acne-prone individuals in a total of 33 patients (16 females and 17 males). The specimens were treated with 10% potassium hydroxide prior to polariscopic examination after squeezing the extract on a glass. The grading of specimens examined was done according to Table I. Statistical analysis of results was done by the χ^2 test.

RESULTS

Polariscopic examination of acne comedones showed a variety of well-defined geometric crystals with square, rectangular, wedge-like or, less often, globular shapes

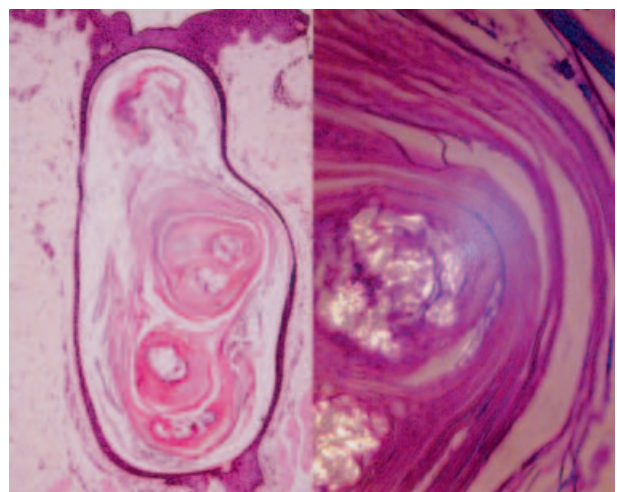


Fig. 1. Biopsy specimen from comedonal acne lesion. Left: a dilated pilosebaceous duct containing a sebolith (haematoxylin and eosin stain). Right: the sebolith, as shown on polariscopic examination, contains birefringent material that bulges against a thinned follicular wall.

Table I. Grading of specimens examined

Grade	Microscopic findings
Negative	No crystals or seboliths
+/-	Focal minute crystals
1+	Frequent and/or widespread crystals and/or single sebolith
2+	Rare seboliths
3+	Several seboliths
4+	Dense diffuse crystals and/or single or several large seboliths

amidst amorphous material and cell clusters (Fig. 2). Some of the aggregates were larger than 0.5 mm and even reached 1 mm in diameter. The internal structure of some crystalline aggregates (sebolith) showed periodicity (Fig. 2d) and stratification (Fig. 2e). Other

anisotropic crystals showed honeycomb appearance, suggestive of incrustation of the crystals in pre-existing cell aggregates, perhaps sebocytes (Fig. 2d). Some rectangular crystals were reminiscent of cholesterol crystals seen in other pathological conditions such as haemorrhagic fluids, e.g. synovial fluid (Fig. 2e). Rare small spherocrystals were occasionally seen, the internal structure of which showed radial striations (Fig. 2f). As shown in Table II, birefringent material was found in 18 of 20 (90%) acne comedones. Crystal formation was more prominent in closed comedones compared with open comedones and in macrocomedones/conglobate comedones compared with the early stage comedones. Crystal formation did not correlate with patient age, sex or location (face versus trunk) of the specimen. Acne pustules showed crystals but rarely compact seboliths.

As also shown in Table II, polarizable material was

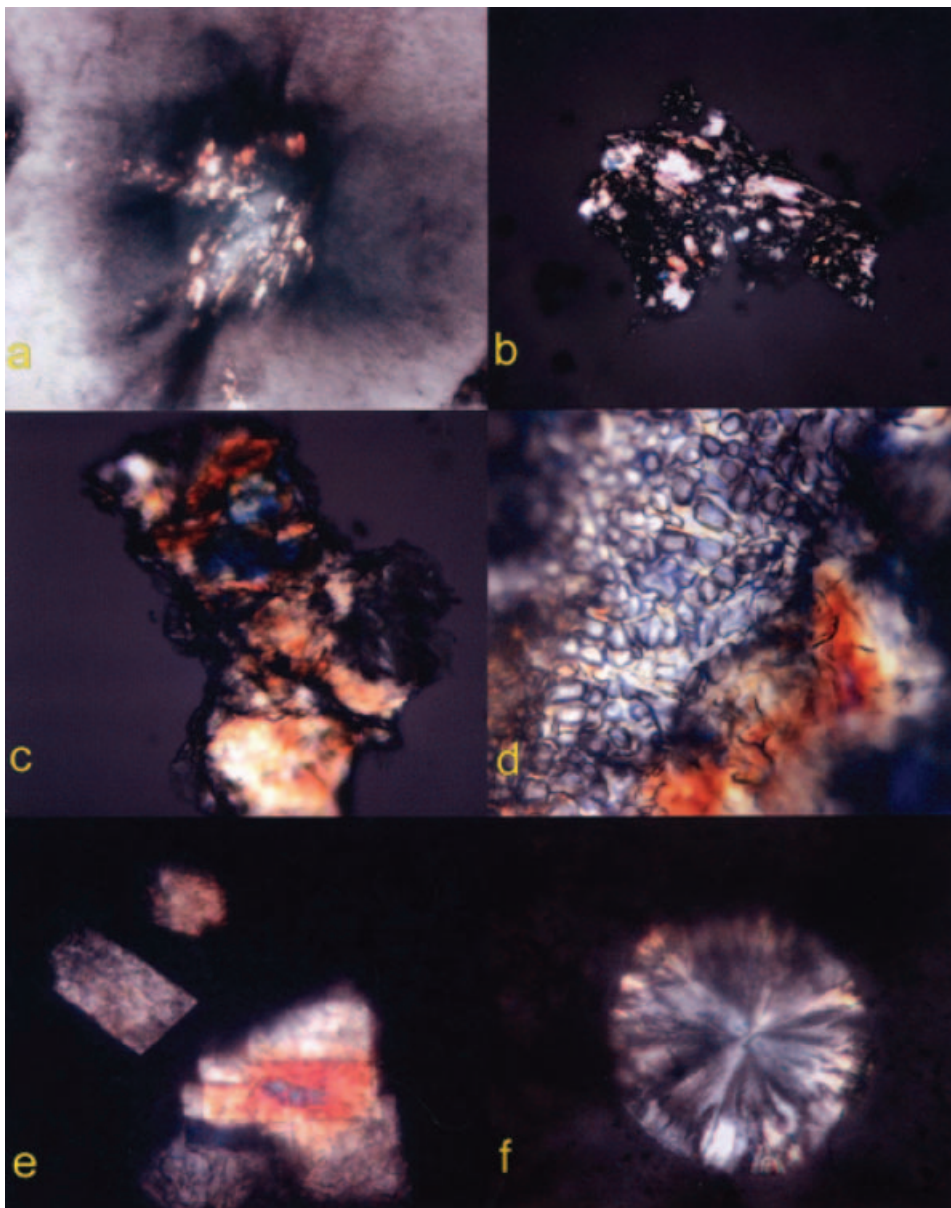


Fig. 2. Polariscope examination of specimens. Low and intermediate power: (a) plug of dense and nearly compact crystals between cells; (b) compact solid wedge-like sebolith, larger than 0.5 mm, intermixed with keratinous filamentous material and hair shaft remnants; (c) rocky birefringent sebolith with dichroism. High power: (d) sebolith composed of densely arranged rectangular and square crystals resembling a honeycomb, possibly due to lipidic incrustation of sebocytes; (e) compact and overlapping rectangular crystals reminiscent of cholesterol crystals; (f) spherocrystal with internal structure showing radial striations.

observed, although to a lesser extent ($p < 0.01$), in solar comedones (Favre-Racouchot disease), in giant comedo-like epidermal inclusion cysts and milia. Crystals and/or seboliths were uncommon within follicular structures of acne rosacea. Pustules of bacterial folliculitis and eight scant specimens from normal follicles did not show substantial crystallization.

DISCUSSION

This study demonstrates that crystal formation is common in acne comedones. Crystallization has been shown in extracutaneous cysts in a few reports (3, 4). While Suskind (5) first observed birefringent lipids (positive for the Liebermann-Buchard reaction of cholesterol compounds) in a large proportion of sebaceous glands, to our knowledge, crystal formation in comedonal extracts has not been reported previously. Montagna (6) reported that sebaceous lipids are anisotropic under polarized light and that the distribution of these lipids corresponds to the colour reaction obtained with the Schulz test for cholesterol. He suggested that these sebaceous lipids, especially the polarizable spherocrystals, are esters of cholesterol. Spherocrystals were not infrequent in our study (Fig. 2f), which supports the early observation by Montagna. However, we noted more variably shaped and conglomerated patterns of crystallization as well (Fig. 2c–e).

Burd et al. (7) have claimed that seboliths can only be found in the distal portions of the pilosebaceous duct. They concluded that they do not appear to play a significant role in the acne-related inflammation. On the contrary, our previous observations demonstrate seboliths also in the deeper portions of the pilosebaceous duct (Fig. 1). The fact that the crystals making up the sebolith resist haematoxylin and eosin-related solvents

in histological preparations and water-based potassium hydroxide solution in our fresh preparations militates, against pure cholesterol and urate crystals, respectively. It appears, therefore, that sebolith formation in acne represents crystallization of other lipids contained within sebum, perhaps squalene (1, 8) or cholesterol-related compounds, such as cholesterol esters (6). Such crystallization may be enhanced by decreased upward elimination of crystalline material secondary to infra-infundibular hyperkeratosis (9) or impaction of the sebolemmal sheath (keratin casing of sebaceous duct origin) in the infra-infundibulum (1, 2). These two mechanisms have been proposed as an explanation for primary comedo formation (2, 10). In our histological studies sebophilic bacteria were often seen on or near crystalline aggregates. Interestingly, Kossard et al. (11) suggested that bacteria (12) and *Pityrosporum* organisms in the follicular infundibulum might induce crystalline structures. This suggestion raises speculation that crystallization of sebum may be induced or enhanced by *P. acnes*.

The vast majority (90%) of acne comedones in our study showed crystal formation, which indicates that crystallization of sebum is a common element of comedogenesis. Crystal formation may increase the cohesion of horny impactions within the comedo, therefore decreasing their upward elimination and eventually prolonging the life of the comedo. Crystalline material in closed comedones may distend the follicular lining, rendering it more susceptible to frictional trauma or even rupture. A similar mechanism was proposed in the pathogenesis of the recently described necrotizing infundibular crystalline folliculitis (11). These authors suggested that crystal formation is an essential element in the sequence of events leading to the destruction of the follicular infundibulum.

Although the sample sizes are small, Table II shows

Table II. Results of polariscopic examination of follicular skin from various types of skin disease

	Microscopic findings ^a						Total number of specimens
	Negative	+/-	1+	2+	3+	4+	
Acne comedones	2	1	5	4	4	4	20
Non-inflamed	2	1	4	1	1	2	11 ^b
Inflamed	0	0	1	3	3	2	9
Open	2	1	3	2	1	1	10
Closed	0	0	2	2	3	3	10
Early comedones	1	2	2	0	0	0	5
Macrocomedones	0	0	2	2	3	3	10
Acne pustules	1	2	3	0	0	0	6
Solar comedones (Favre-Racouchot disease)	2	3	2	1	0	1	9
Epidermal inclusion cysts	0	1	1	2	0	1	5
Milia	0	1	0	1	1	0	3
Rosacea	3	1	0	0	0	0	4
Folliculitis	3	1	0	0	0	0	4

^aThe grading system is explained in Table I.

^bComedone extracts are shown repeatedly, e.g. as non-inflamed, open and macrocomedones.

a tendency for the macrocomedo/conglobate comedones to contain more crystalline material than the early stage comedones. This indicates that crystal formation may increase with the age and size of the comedones. Similarly, Table II shows a tendency for the closed comedones to contain more birefringent material than the open type. This can be due to the fact that sebum can still flow through channels in the open comedones, whereas there is no sebum flow in the closed type (9).

Crystal formation was also observed in our study in solar comedones, which are known to show intact follicular epithelium, absence of inflammation and scars, and sparse or absent *P. acnes* (9). Crystal formation in solar comedones may contribute to the preservation of these lesions but, in the absence of other critical elements of inflammation such as *P. acnes*, it may be insufficient to cause inflammation. We believe that the same occurs with milia and epidermal inclusion cysts, lesions that, as shown in our study, may also contain crystalline material. Crystal formation in these lesions can be attributed to stagnation of sebaceous lipids. However, the presence of a more pliant lining and wider lumen in cysts minimizes the opportunity for rupture and inflammation. As shown in this study, crystal formation is not observed in bacterial folliculitis and acne rosacea, which is not unexpected because these skin disorders are neither primary disorders of the sebaceous gland nor characterized by comedo formation.

In conclusion, this study demonstrates that crystallization of sebum is a common event during comedogenesis, a finding that has not been reported or recognized for decades. Crystal formation is not a prerequisite for inflammation but its role in the inflammatory process in acne needs to be studied. The presence of crystals or better-formed seboliths without follicular epithelial breakdown and significant numbers of *P. acnes* may be insufficient to initiate or enhance inflammation and many small or smooth contoured seboliths are likely to be excreted subclinically. This could explain why some comedones disappear without treatment. However, the presence of birefringent aggregates and calculi in follicular contents

invites investigation as to whether lipidic crystals are strong irritants when they diffuse into the dermis during the stage of follicular rupture and whether they play a role in that rupture. Clarifying these issues will improve our understanding of the natural history of acne comedones and will make clearer the sequence of events that leads to their formation, natural resolution, preservation or inflammation.

REFERENCES

1. González-Serva A. [The pathogenesis of acne: from a hyperkeratotic paradigm (comedo) to one of follicular calculus (sebolith).] *Med Cutan Iber Lat Am* 1996; 24: 11–25 [in Spanish].
2. Abramovits W, González-Serva A. Sebum cosmetics and skin care. *Dermatol Clin* 2000; 18: 617–620.
3. Raso DS, Greene WB, Silerman JF. Crystallizing galactoceles. *Acta Cytol* 1997; 41: 863–870.
4. Shapiro A, Tso MO, Putterman A, Goldberg MF. A clinicopathologic study of hematic cysts of the orbit. *Am J Ophthalmol* 1986; 102: 237–241.
5. Suskind RR. The chemistry of human sebaceous gland. Histochemical observations. *J Invest Dermatol* 1951; 17: 37–54.
6. Montagna W. The sebaceous glands in man. In: Montagna W, Ellis RA, Silver AF, eds. *Advances in biology of the skin*, Vol. IV. New York: Pergamon Press, 1963: 19–31.
7. Burd RM, Merchant WJ, Cunliffe WJ. The role of sebolith in the pathogenesis of inflamed acne lesions. *Br J Dermatol* 1998; 139: 53.
8. Ernst J, Sheldrick WS, Fuhrhop JH. The crystal structure of squalene. *Angew Chemie Int Ed Engl* 1976; 15: 778.
9. Plewig G, Kligman AM. Dynamics of primary comedo formation. In: Plewig G, Kligman AM, eds. *Acne and rosacea*. Berlin: Springer-Verlag, 1993: 103–105.
10. Cunliffe WJ, Holland DB, Clark SM, Stables GI. Comedogenesis: some aetiological, clinical and therapeutic strategies. *Dermatology* 2003; 206: 11–16.
11. Kossard S, Scurry J, Killingsworth M. Necrotizing infundibular crystalline folliculitis. *Br J Dermatol* 2001; 145: 165–168.
12. Juhlin L, Shelley WB. Oriented fibrin crystallization: a phenomenon of hypersensitivity to bacteria in psoriasis, vasculitis and other dermatoses. *Br J Dermatol* 1977; 96: 577–586.