

## CLINICAL REPORT

## Digital Skin Necrosis in Congenital Afibrinogenaemia Associated with Hepatitis C Virus Infection, Mixed Cryoglobulinaemia and Anticardiolipin Antibodies

Céline GIRARD<sup>1</sup>, Bernard GUILLOT<sup>1</sup>, Christine BIRON<sup>2</sup>, Thierry LAVABRE-BERTRAND<sup>3</sup>, Robert NAVARRO<sup>3</sup> and Didier BESSIS<sup>1</sup>

<sup>1</sup>Service de Dermatologie, <sup>2</sup>Laboratoire Central d'Hématologie-Centre Régional de traitement de l'Hémophilie et des Maladies hémorragiques and

<sup>3</sup>Service d'Hématologie et Oncologie Médicale, CHU Montpellier, France

**Congenital afibrinogenaemia is a rare genetic disorder transmitted as an autosomal recessive trait and characterized by the complete absence of fibrinogen in the plasma. We report a 41-year-old woman who suffered from congenital afibrinogenaemia and hepatitis C viral infection and presented with ischaemic necrosis and livedo of the toes. Laboratory investigations showed the presence of mixed cryoglobulinaemia and anticardiolipin antibodies. Resolution occurred with plasmapheresis. We discuss the pathophysiology of this unusual condition and review the literature for skin manifestations associated with this rare haemostasis disorder. Key words: digital necrosis; congenital afibrinogenaemia; hepatitis C virus infection; cryoglobulinaemia; anticardiolipin antibodies syndrome.**

(Accepted July 19, 2004.)

Acta Derm Venereol 2005; 85: 56–59.

Dr Didier Bessis, Service de Dermatologie, Hôpital Saint Eloi, CHU Montpellier, 80, Avenue Augustin Fliche, FR-34295 Montpellier Cedex 5, France. E-mail: bessis.d@free.fr

Congenital afibrinogenaemia is a rare genetic disorder transmitted as an autosomal recessive trait and characterized by the complete absence of fibrinogen in the plasma (1). The main clinical manifestations of congenital afibrinogenaemia are bleeding symptoms: umbilical cord bleeding in newborn infants, central nervous system bleeding, haemarthroses, haematomas, gastrointestinal bleeding and other mucosal tract bleeding such as epistaxis, menorrhagia and haematuria. Decreased fertility and recurrent abortions have also been reported. However, the knowledge of the spectrum of symptoms in such patients is limited, due to the rarity of this defect.

Arterial and venous thrombotic events, including cutaneous necrosis, cerebral infarcts and deep venous thrombosis, have been rarely described in afibrinogenaemic patients (2). We report here a case of an afibrinogenaemic patient with a history of hepatitis C virus (HCV) infection who presented with ischaemic skin lesions on her feet and was diagnosed as having mixed polyclonal cryoglobulinaemia and anticardiolipin antibodies (ACL).

## CASE REPORT

A 41-year-old woman had been diagnosed with congenital afibrinogenaemia at the age of 5 years since she experienced spontaneous recurrent intraperitoneal bleeding and haematomas. Details of the molecular analysis of the mutation of the fibrinogen gene have been reported previously (3). She received multiple administrations of fresh plasma and fibrinogen concentrate. At the age of 37, post-transfusion active HCV infection was diagnosed. Treatment with recombinant interferon alpha (Intron A, Schering Plough, Nutley, NJ, USA),  $3 \times 10^6$  U injected subcutaneously three times a week for 1 year, resulted in the absence of detection of the HCV-RNA in serum by polymerase chain reaction, but a relapse of circulating HCV-RNA was noted 2 months after cessation of the treatment. During the same period, the patient complained of a permanent blue discoloration of the lateral sides of the feet. Oral nifedipine treatment for a 1-month period was ineffective. One year later, 20 days after a perfusion of 3 g of fibrinogen concentrate (human fibrinogen, Clottagen®, LFB, Les Ulis, France) for a haematoma of the right breast, the patient complained of a marked dark-blue discoloration of the fifth toes. She had taken no other medication before the onset of symptoms and had not been exposed to cold temperatures at the time.

On admission, a livedo reticularis over the dorsal aspect of the feet was noticed. The fifth toes were blue, painful to the touch, and a central necrotic zone was present on the right pad (Fig. 1). The clinical examination was otherwise unremarkable.

Investigations including full blood count, calcium, phosphate, renal and liver function tests were all normal. Circulating HCV-RNA was positive. The prothrombin time, the partial thromboplastin time and the fibrinogen level ( $<0.3 \text{ g l}^{-1}$ , normal  $1.9\text{--}4 \text{ g l}^{-1}$ ) were not measurable. Enzyme immunoassay revealed positive ACL of the IgG subclass at  $25 \text{ UGPL l}^{-1}$  (normal  $<15 \text{ UGPL l}^{-1}$ ), whereas ACL of IgM isotype and lupus anticoagulant (LA), anti-beta2-glycoprotein I antibodies (anti $\beta$ 2-GP I) were absent. LAs were assessed according to the ISTH recommendations (4). ACL and

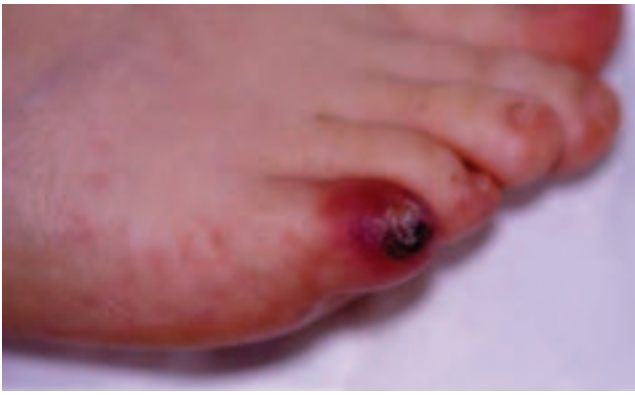

Fig. 1. Necrotic cutaneous lesions and livedo of the fifth toe of the right foot.

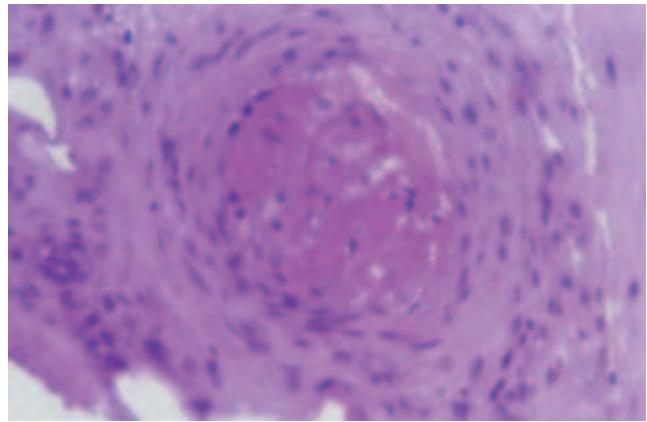


Fig. 2. Hyalinizing thrombosis with no evidence of vasculitis or leucocytoclasia (haematoxylin-eosin; original magnification  $\times 40$ ).

anti $\beta$ 2-GP I were determined by quantitative ELISA (QuantaLite Inova diagnostics, San Diego, CA, USA). The standards and controls were obtained from the Antiphospholipid Standardization Laboratory (Louisville, USA). The normal values were levels below: 13.5 GPL/ml or 11 MPL/ml for IgG or IgM ACL respectively, and 20 SGU/ml for both IgG or IgM anti- $\beta$ 2-GP I.

A type III mixed polyclonal cryoglobulinaemia was present. Quantitation of protein C, protein S, anti-thrombin and homocystein, and search for Factor V Leiden and prothrombin gene G20210A polymorphism revealed no abnormality. A cutaneous biopsy (3-mm punch) was performed on the distal pad of the left fifth toe, immediately after administration of fibrinogen concentrate. Histological examination demonstrated a non-inflammatory hyaline thrombosis of the blood vessel of the reticular dermis and a mild cell infiltration of lymphocytes, with no evidence of vasculitis or leucocytoclasia (Fig. 2).

Plasmapheresis was instituted consisting of exchange of 1.0–1.6 plasma volumes followed by the administration of 4.5–6 g of human fibrinogen during each session. A series of six cycles of plasma exchanges in a 6-week period was carried out, resulting in a fading of the blue discoloration of the toes and a partial regression of the livedo after the third session. Thirty-six additional cycles were done during the next 7 months, leading to a complete clearing of the cutaneous lesions. At the same time, repeated cryoglobulin analyses were negative.

## DISCUSSION

Cutaneous manifestations of afibrinogenemia are so far paradoxically limited to skin arterial thrombosis (5–11), leading to leg ulcers and digital necrosis. The main clinical features and haemostasis investigations are summarized in Table I. The ischaemic necrosis always involves the toes and is most commonly associated with a blue discoloration or a livedo reticularis of the feet.

Table I. Cutaneous manifestations of thrombosis-associated afibrinogenemia: review of the literature

Ref. no.	Age, sex	Clinical manifestation	Associated manifestation	Treatment, outcome
5	36, F	Necrosis of the toes	Cerebral haemorrhage, carotid and aortic thrombosis	Died 7 months later
6	37, F	Necrosis of a toe		Prostaglandin: improvement
7	13, F	Necrosis of the toes		Fresh frozen plasma, heparin, vasodilative drugs: improvement
8	37, M	Necrosis of the toes and fingers		
9	32, F	Necrosis and blue toes, leg ulcers	Deep venous thrombosis	Amputation of toes
2	14, F	Gangrene of a foot		Amputation of toes
10	30, M	Necrosis of a toe, livedo of the foot	Occlusion of iliac and hypogastric arteries	Ilomedin: no improvement. Surgical arterial bypass, heparin, aspirin
11	30, M	Leg ulcer	Venous insufficiency in the left lower extremity	Fresh frozen plasma, excision of ulcer, skin transplantation
This study	41, F	Necrosis of a toe, livedo of the feet		Plasmapheresis: improvement

The severity of the lesions is variable, leading to amputation in three of eight cases due to thrombosis of large arterial vessels.

Hypothetically, two thrombotic mechanisms could explain our observations. First, fibrinogen perfusion could have led to a temporary local hyperfibrinogenemia and a local disturbance of the balance between coagulation and fibrinolysis. However, this mechanism has so far not been clearly documented. In addition, arterial thrombotic events during afibrinogenemia have been described in the absence of any substitutive therapy (8). In our case, the pathogenic role of the fibrinogen administration seems unlikely since the first cutaneous symptoms appeared about 3 weeks after the perfusion, while the half-life of human fibrinogen is about 96–144 h. In addition, the subsequent repeated perfusions of fibrinogen associated with plasmapheresis were not deleterious for the skin symptoms. The second hypothesis is based on the presence of a congenital or acquired thrombophilic associated disorder that could predispose to or trigger a coagulation activation, even in the absence of plasma fibrinogen. Previous laboratory studies have clearly demonstrated that platelet aggregation could occur without fibrinogen by the contribution of other adhesive proteins, like von Willebrand factor, fibronectin and vitronectin (12–14). Two previous clinical observations of necrosis-associated afibrinogenemia mentioned the possible role of congenital protein C deficiency (6, 7). In our case, the laboratory investigations exhibited the presence of ACL and mixed cryoglobulinaemia. However, even if antiphospholipid antibodies and particularly IgG ACL are frequently found in patients with HCV infection, they are mostly of low titre (as in our case) and not significantly associated with the survey of thrombotic events in absence of anti $\beta_2$ -GP I antibodies (15). Cryoglobulins are composed of cold-sensitive immunoglobulins that precipitate at and below normal body temperature. The association of chronic active hepatitis C, mixed cryoglobulinaemia (type II or III), and skin lesions including palpable purpura, livedo reticularis, distal ischaemia or cutaneous ulcers are well documented (16–18). The cutaneous lesions are mainly supposed to be due to deposition of circulating immune complexes in the blood vessels, thus leading to vasculitis (18). However, vascular obstruction by deposition of cryoglobulin in the form of tubular micro-crystallites or platelet aggregation by anti-platelet antibodies are other possible mechanisms (19, 20). In our observation the pathogenic role of the cryoglobulinaemia is suggested by the efficacy of the plasmapheresis resulting in the complete clearing of the cutaneous lesions concurrently with the removal of the cryoglobulin.

In conclusion, the development of cutaneous necroses in afibrinogenemia patients requires a complete

haemostasis evaluation, including laboratory tests for congenital or acquired thrombophilia.

## REFERENCES

1. Neerman-Arbez M. The molecular basis of inherited afibrinogenemia. *Thromb Haemost* 2001; 86: 154–163.
2. Lak M, Keihani M, Elahi F, Peyvandi F, Mannucci PM. Bleeding and thrombosis in 55 patients with inherited afibrinogenemia. *Br J Haematol* 1999; 107: 204–206.
3. Neerman-Arbez M, de Moerloose P, Honsberger A, Parlier G, Arnuti B, Biron C, et al. Molecular analysis of the fibrinogen gene cluster in 16 patients with congenital afibrinogenemia: novel truncating mutations in the FGA and FGG genes. *Hum Genet* 2001; 108: 237–240.
4. Brandt JT, Triplett DA, Alving B, Scharrer I. Criteria for the diagnosis of lupus anticoagulants: an update. On behalf of the Subcommittee on lupus anticoagulant/antiphospholipid antibody of the Scientific and Standardisation Committee of the ISTH. *Thromb Haemost* 1995; 74: 1185–1190.
5. MacKinnon HH, Fekete JF. Congenital afibrinogenemia: vascular changes and multiple thromboses induced by fibrinogen infusions and contraceptive medication. *Can Med Assoc J* 1971; 104: 597–599.
6. Hanano M, Takahashi H, Itoh M, Shibata A. Coexistence of congenital afibrinogenemia and protein C deficiency in a patient. *Am J Hematol* 1992; 41: 57–60.
7. De Mattia D, Regina G, Giordano P, Del Vecchio GC, Altomare M, Schettini F. Association of congenital afibrinogenemia and K-dependent protein C deficiency. *Angiology* 1993; 44: 745–749.
8. Chafa O, Chellali T, Sternberg C, Reghis A, Hamladji RM, Fischer AM. Severe hypofibrinogenemia associated with bilateral ischemic necrosis of toes and fingers. *Blood Coagul Fibrinolysis* 1995; 6: 549–552.
9. Rupec RA, Kind P, Ruzicka T. Cutaneous manifestations of congenital afibrinogenemia. *Br J Dermatol* 1996; 134: 548–550.
10. Dupuy E, Soria C, Molho P, Zini JM, Rosenstingl S, Laurian C, et al. Embolized ischemic lesions of toes in an afibrinogenemic patient: possible relevance to in vivo circulating thrombin. *Thromb Res* 2001; 102: 211–219.
11. Kinebuchi A, Ohtsuka T, Ishida S, Otsuka S, Abe T, Yamakage A, et al. Leg ulcer presenting in a patient with congenital afibrinogenemia. *Eur J Dermatol* 2002; 12: 70–72.
12. De Marco L, Girolami A, Zimmerman TS, Ruggeri ZM. Von Willebrand factor interaction with the glycoprotein IIb/IIIa complex. *J Clin Invest* 1986; 77: 1272–1277.
13. Cattaneo M, Kinlough-Rathbone RL, Lecchi A, Bevilacqua C, Packham MA, Mustard JF. Fibrinogen-independent aggregation and deaggregation of human platelets: studies in two afibrinogenemic patients. *Blood* 1987; 70: 221–226.
14. Remijn JA, Wu YP, Ijsseldijk JW, Zwaginga JJ, Sixma JJ, de Groot PG. Absence of fibrinogen in afibrinogenemia results in large but loosely packed thrombi under flow conditions. *Thromb Haemost* 2001; 85: 736–742.
15. Biron C, Andréani H, Blanc P, Ramos J, Ducos J, Michel H, et al. Prevalence of antiphospholipid antibodies in patients with chronic liver disease related to alcohol or hepatitis C virus: correlation with liver injury. *J Lab Clin Med* 1998; 131: 243–250.

16. Cohen SJ, Pittelkow MR, Su WP. Cutaneous manifestations of cryoglobulinemia: clinical and histopathological study of seventy-two patients. *J Am Acad Dermatol* 1991; 25: 21–27.
17. Daoud MS, el-Azhary RA, Gibson LE, Lutz ME, Daoud S. Chronic hepatitis C, cryoglobulinemia, and cutaneous necrotizing vasculitis. *J Am Acad Dermatol* 1996; 34: 219–223.
18. Trejo O, Ramos-Casals M, Garcia-Carrasco M, Yagüe J, Jimenez S, De La Red G, et al. Cryoglobulinemia. Study of etiologic factors and clinical and immunologic features in 443 patients from a single center. *Medicine* 2001; 80: 252–262.
19. Berliner S, Weinberger A, Ben-Bassat M, Idesess C, Haza B, David M, et al. Small skin blood vessel occlusions by cryoglobulin aggregates in ulcerative lesions in IgM-IgG cryoglobulinemia. *J Cutan Pathol* 1982; 9: 96–103.
20. Takeuchi T, Yoshioka K, Hori A, Mukoyama K, Ohsawa A, Yokoh S. Cytomegalovirus mononucleosis with mixed cryoglobulinemia presenting pseudothrombocytopenia. *Intern Med* 1993; 32: 598–601.