

## Lymph Node False-Positive FDG-PET after Recent Surgery in Primary Melanoma

Pedro Redondo<sup>1</sup> and José F. Boán<sup>2</sup>

Departments of Dermatology<sup>1</sup> and Nuclear Medicine<sup>2</sup>, University Clinic of Navarra, School of Medicine, P.O. Box 4209, ES-31080 Pamplona, Spain. E-mail: predondo@unav.es

Accepted July 4, 2003

Sir,

Positron emission tomography (PET) with (18)F-fluorodeoxyglucose (FDG) is a rapidly developing new imaging technique in the diagnosis and staging of melanoma. Indications for FDG-PET include pre-metastatic melanoma, localized lymph node metastases and monitoring of the response to treatment. FDG-PET can accurately detect metastatic melanoma with a single non-invasive scan, and can demonstrate some metastases months before conventional imaging techniques. Through a meta-analysis, Schwimmer et al. (1) determined, within a 95% confidence level, an overall sensitivity of 92% and an overall specificity of 90% for FDG-PET in detecting recurrent melanoma throughout the whole body.

Although FDG-PET is not a particularly tumour-specific substance, its accumulation in other lesions with increased glucose metabolism (chronic or acute inflammatory processes) may give rise to false-positive results (relatively low specificity, frequently below 85%) (2). FDG-PET has a limited capacity to detect metastases in non-palpable lymph nodes. FDG-PET reliably detects lymph node tumour deposits greater than approximately 80 mm<sup>3</sup> volume, but sensitivity rapidly falls below this (3). Micrometastases are <2 mm<sup>3</sup> deposits of tumoral cells that are segregated spatially from the primary tumour and depend on neovascular formation to propagate.

The sentinel node is the first to receive lymph from any primary solid neoplasm. Lymphoscintigraphy is a

sensitive, inexpensive, relatively non-invasive method of identifying lymphatic drainage patterns and sentinel lymph nodes in patients with malignant melanoma. Here, we describe two melanoma patients with PET-positive axilla and groin who underwent therapeutic lymph node dissection but were found to have no pathological lymph node involvement.

### CASE REPORTS

The two patients, a 55-year-old woman (patient 1) and a 67-year-old man (patient 2), suffered from melanoma with Breslow depths greater than 1.5 mm and clinically negative regional nodes. *Patient 1* was referred to our hospital after resection of a malignant melanoma (Clark IV, Breslow 1.9 mm) of the right leg. Eleven days later, preoperative lymphoscintigraphy showed node drainage around the groin. FDG-PET imaging detected an area of markedly hypermetabolic activity at the same location (Fig. 1). *Patient 2* was referred to our hospital after the resection of ulcerated polypoid malignant melanoma (Clark III, 12 mm thick) of the left arm. Twenty days later, preoperative lymphoscintigraphy indicated axillary lymph draining. FDF-PET imaging showed uptake in the same lymph node basins.

The PET-positive results in both patients led us to perform an elective lymph node dissection in order to study not just the sentinel node but all the lymph nodes. All the lymph nodes analysed in these two patients were negative. In the first patient, the sentinel node

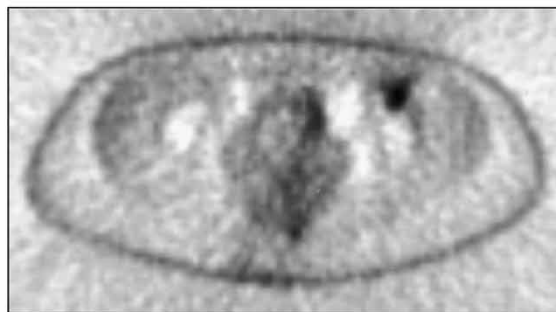
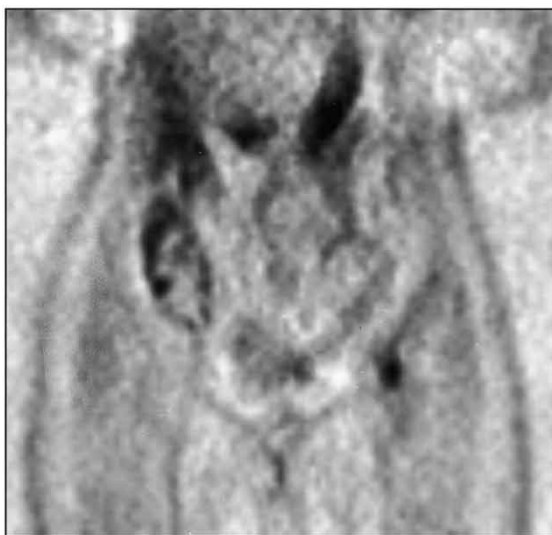

Fig. 1. Coronal and transaxial FDG-PET study in patient No. 1 who previously underwent resection of a cutaneous melanoma of the leg. PET detected a lesion in the groin.

was extracted and dissection performed in the same operation. The immunohistochemical study (S-100 and HMB-45) of the node also proved to be negative, and did not present signs of dermatopathic lymphadenitis.

## DISCUSSION

The most powerful predictor of cancer mortality in solid tumours is the status of the regional lymph nodes. Metastatic melanoma characteristically disseminates in an orderly progression through lymphatic channels to the regional lymph nodes. The presence of regional lymph node involvement is the single most important prognostic factor. The assessment of lymph nodes in patients with melanoma has been a subject of controversy. Elective lymph node dissection is not indicated in thin melanomas, because local excision has a very high curative rate. Furthermore, it is generally not indicated in thick melanomas owing to the high prevalence of local and systemic involvement at presentation. Lymph node dissection is curative for some patients with nodal metastases. The overall survival of patients with nodal metastases removed at elective lymph node dissection is significantly greater than in patients who undergo lymphadenectomy for palpable lymph nodes (4). The technique of sentinel lymph node biopsy is the most accurate method for staging patients with primary cutaneous melanoma who lack clinical (or radiological) evidence of metastatic disease (5). Lymphoscintigraphy with sentinel node dissection and FDG-PET are being used independently in the management of intermediate and thick melanoma. In general, FDG-PET is an insensitive indicator of occult regional lymph node metastases in patients with melanoma because of the minute tumour volumes in this population (6). Because of PET non-detected micrometastases, sentinel node biopsy is the only reliable method for identifying micrometastatic disease in the regional draining node (7). But positive PET raises the suspect of metastatic disease (8). In the case of suspect metastatic disease based on a positive PET, should we carry out a lymphadenectomy? Or could the sentinel lymph node study be enough? Moreover, owing to the poor anatomic definition of the PET images, correlation between the sentinel node of the lymphoscintigraphy and the node with high FDG uptake is difficult

to determine. Our patients provide the first evidence in primary melanoma that recent surgery can produce a node lymph non-specific inflammation by PET in the absence of malignant cells.

Non-infectious inflammatory reactions are just as common weeks, even months, after surgery as positive PET results on primary melanoma surgical scars. In our patients, the false-positives were due to reactive changes post-biopsy. These cases emphasize the complementary roles of lymphoscintigraphy sentinel node mapping and FDG-PET. Knowledge of normal post-operative FDG-PET uptake patterns might be important in reducing false-positive results in this setting.

## REFERENCES

1. Schwimmer J, Essner R, Patel A, Jahan SA, Shepherd JE, Park K, et al. A review of the literature for whole-body FDG-PET in the management of patients with melanoma. *Q J Nucl Med* 2000; 44: 153–167.
2. Strauss LG. Fluorine-18 deoxyglucose and false-positive results; a major problem in the diagnostics of oncological patients. *Eur J Nucl Med* 1996; 23: 1409–1415.
3. Wagner JD, Schauwecker DS, Davidson D, Wenck S, Jung SH, Hutchins D. FDG-PET sensitivity for melanoma lymph node metastases is dependent on tumor volume. *J Surg Oncol* 2001; 77: 237–242.
4. Cascinelli N, Morabito A, Santinami M, MacKie RM, Belli F. Immediate or delayed dissection of regional nodes in patients with melanoma of the trunk: a randomised trial. WHO Melanoma Programme. *Lancet* 2000; 351: 793–796.
5. Morton DL, Thompson JF, Essner R, et al. Validation of the accuracy of intraoperative lymphatic mapping and sentinel lymphadenectomy for early-stage melanoma: a multicenter trial. Multicenter Selective Lymphadenectomy Trial Group. *Ann Surg* 1999; 230: 453–463.
6. Wagner JD, Schauwecker D, Davidson D, Coleman JJ 3rd, Saxman S, Hutchins G, et al. Prospective study of fluorodeoxyglucose-positron emission tomography imaging of lymph node basins in melanoma patients undergoing sentinel node biopsy. *J Clin Oncol* 1999; 17: 1508–1515.
7. Acland KM, Healy C, Calonje E, O'Doherty M, Nunan T, Page C, et al. Comparison of positron emission tomography scanning and sentinel node biopsy in the detection of micrometastases of primary cutaneous malignant melanoma. *J Clin Oncol* 2001; 19: 2674–2678.
8. Damian DL, Fulham MJ, Thompson E, Thompson JF. Positron emission tomography in the detection and management of metastatic melanoma. *Melanoma Res* 1996; 6: 325–329.