

CLINICAL REPORT

Juvenile Mycosis Fungoides Diagnosed Before 18 Years of Age

DAN BEN-AMITAI¹, MICHAEL DAVID², MEORA FEINMESSER³ and EMMILIA HODAK²

¹*Pediatric Dermatology Clinic, Schneider Children's Medical Center of Israel, ²Department of Dermatology and ³Institute of Pathology, Rabin Medical Center, Beilinson Campus, Petah Tiqva and the Sackler Faculty of Medicine, Tel-Aviv University, Tel-Aviv, Israel*

The literature regarding mycosis fungoides in children is sparse. To shed further light on the characteristics of mycosis fungoides in the paediatric population we analysed the clinicopathological features of 10 patients in whom this malignancy was diagnosed before the age of 18 years. All were Jews and Arabs with histologically proven patch/early plaque stage disease: 4 in stage IA, 4 in IB and 2 with unilesional disease. Seven patients had hypopigmented lesions either constituting the sole manifestation (2 patients) or in combination with classic lesions (5 patients); of these, 3 had light skin and 4 pigmented skin. Most patients had immunohistochemical features characteristic of mycosis fungoides, with a predominance of CD4+ T cells. Some had deletion of CD7+ cells. In 3 patients, however, the epidermotropic cells were exclusively or predominantly CD8+ cells. All patients responded to conventional therapy and during an average follow-up of 3.4 years only one patient showed stage progression, but without extracutaneous involvement. It is concluded that juvenile mycosis fungoides is characterized by early stage disease, occasionally with unilesional disease, usually with hypopigmented lesions irrespective of skin colour, and a good response to therapy. On the basis of our experience and review of the literature, it appears that the CD8+ phenotype is over-represented in juvenile disease. **Key words:** *childhood; cutaneous T-cell lymphoma; immunohistochemistry.*

(Accepted July 4, 2003.)

Acta Derm Venereol 2003; 83: 451–456.

Dr Dan Ben-Amitai, Pediatric Dermatology Clinic, Schneider Children's Medical Center of Israel, 14 Kaplan Street, Petah Tiqva 49202, Israel. E-mail: danb@clalit.org.il

Mycosis fungoides (MF) is the most common cutaneous T-cell lymphoma (CTCL). It is characterized by epidermotropic atypical T lymphocytes that are clonally expanded in the skin. Its reported incidence in the Western world is 0.5 cases per 100,000 per year (1) and it usually occurs in older adults: approximately 75% of patients are diagnosed beyond age 50 (1), whereas only 0.5–5% of all cases are diagnosed before age 20 (2, 3).

The diagnosis of early-stage MF is often delayed because the long-standing erythematous patches may

resemble inflammatory dermatoses such as atopic dermatitis, or, in cases of hypopigmented lesions, pityriasis alba, vitiligo or pityriasis versicolor, all of which are much more common in the paediatric population. It would appear that this is particularly true in children; although the literature on this subject is scanty, adult patients occasionally report that the typical rash appeared before the age of 20 years. To shed further light on the characteristics of MF in the paediatric population, we analysed the clinical and immunohistopathological findings and follow-up data in 10 patients in whom MF had been histologically diagnosed before the age of 18 years.

PATIENTS AND METHODS

The study population comprised 10 Caucasian patients (6 boys and 4 girls) diagnosed to have MF before age 18 during the period 1994 to 2002. Age at clinical onset of disease was 1.0 to 15.5 years (median 7.5 years). Six patients had light skin and 4 pigmented skin. Diagnosis was based on the clinical features combined with histopathological findings characteristic for MF (4). The slides were reviewed by two dermatopathologists (MF and EH). In addition, each biopsy was subjected to immunohistochemical studies on formalin-fixed, paraffin-embedded tissue and frozen sections, with an avidin-biotin complex immunoperoxidase technique (ABC Vectastain Kit, Vector Laboratories Inc., Burlingame, CA, USA), using monoclonal antibodies CD3, CD4, CD8 (Dako, Glostrup, Denmark) and CD7 (B-B7; R&D Immuno Quality Product, Uithoorn, The Netherlands). Molecular studies using the polymerase chain reaction (PCR) technique were performed on DNA extracted from frozen tissue of selected cases to determine the rearrangement of the T-cell receptor (TCR) gene as previously described (5).

The evaluation of each child consisted of a detailed personal and familial medical history, physical examination, routine laboratory tests, including blood smear, leucocyte count, biochemistry, the T helper/T suppressor ratio, serology for human T lymphotropic virus type I (HTLV-1) by enzyme-linked immunosorbent assay (ELISA), and imaging procedures, including chest X-rays and abdominal ultrasound examination. Lymph node biopsy was performed when there was palpable lymphadenopathy. Staging was done according to the Bunn & Lamberg staging system (6). Patients in whom the cutaneous lesions had been noted before age 18, but the histological diagnosis made only thereafter, were not included in the study.

The response to therapy was defined as follows: complete response – complete disappearance of clinical lesions for at least one month; partial response – disappearance of more than 50% of the lesions; no response – disappearance of less than 50% of the lesions; progressive disease – a greater than 25% increase in skin lesions.

Table I. Clinical data of the patients with juvenile mycosis fungoides

Patient no./sex	Skin colour	Age at onset by history (years)	Age at diagnosis (years)	Time to diagnosis (years)	Stage at diagnosis	Types of lesions	Site	Therapy and outcome	Course	Duration of last response (years)	Duration of follow-up since diagnosis (years)	Last status
1/M	Light	13.5	13.8	0.3	la (patch)	Mixed	Lower abdomen	Steroids*→NR, NM→CR	No relapse	2.0	4.0	NED
2/M	Pigmented	1.0	4.0	3.0	la (patch/plaque)	Mixed	Upper and lower limbs	Tar + sun→NR, UVB→NR, NM→PD to IIA, PUVA→CR	No relapse	1.5	4.0	NED
3/F	Light	10.0	17.0	7.0	la (patch)	Classic	Axilla, lower abdomen	UVB→CR	Relapse after 1 y, topical steroids→CR	1.5	3.0	NED
4/M	Light	15.5	17.5	2.0	la (patch)	Classic	Axilla, lower abdomen, thighs	UVB→CR	No relapse	1.8	2.5	NED
5/M	Light	5.0	14.0	9.0	Unilesional (patch)	Hypo-pigmented	Thigh	Steroids*→PR, Tar + sun exposure→CR	No relapse	0.5	2.0	Lost to follow-up
6/F	Light	12.5	14.5	2.0	Unilesional (plaque)	Classic	Breast	Excision→CR	No relapse	5.0	6.0	NED
7/M	Pigmented	1.0	15.5	14.5	lb (patch/plaque)	Mixed	Upper and lower limbs	NM→ACO, Tar + sun→PR, PUVA→CR	No relapse	3.0	5.0	NED
8/F	Light	5.0	13.5	8.5	lb (patch)	Mixed	Trunk, upper and lower limbs	PUVA→CR	No relapse	0.8	3.5	Lost to follow-up
9/F	Pigmented	11.5	13.0	1.5	lb (patch)	Hypo-pigmented	Trunk, upper and lower limbs	PUVA→CR	Relapse after 1 y, topical steroids→CR	1.0	3.0	NED
10/M	Pigmented	2.5	16.0	13.5	lb (patch/plaque)	Mixed	Axilla, trunk, upper and lower limbs	NBUVB→PR	Ongoing therapy	1.0	1.0	AWD

Mixed = hypopigmented + classic, UVB = ultraviolet B, NBUVB = Narrow-band UVB, NM = nitrogen mustard, PUVA = psoralen with ultraviolet A, NR = no response, CR = complete response, PR = partial response, NED = no evidence of disease, AWD = alive with disease, ACO = allergic contact dermatitis, PD = progressive disease. *Topically applied corticosteroids (mid to high potency).

RESULTS

The clinical data of the patients are presented in Table I. In 5 patients the initial clinical diagnosis differed from MF (psoriasis, nummular eczema, morphea, pityriasis alba, vitiligo) and in 2 no specific clinical diagnosis had been offered.

Age at the diagnostic biopsy ranged from 3.8 to 17.5 years, median 14.3 years, and the duration of the clinical eruption from onset to diagnosis was between 3 months and 13.5 years (median 5 years). Two patients were siblings (numbers 2 and 7). The remaining cases were apparently sporadic, with no family history of lymphoproliferative disease. All 10 patients were in good general health and without a remarkable medical history except patient no. 5, who had a clinical history of bronchial asthma. None of the patients had atopic dermatitis.

On initial examination, all patients had early MF and most of them presented with patches. In 2 patients there was unilesional MF, i.e. MF presenting as a solitary skin lesion. Four had stage Ia disease with patches and/or plaques involving <10% of body surface and 4 had stage Ib disease with patches and/or plaques involving ≥10% of total body surface. Three patients had classic lesions of MF and 7 had atypical lesions. In 2 patients purely hypopigmented lesions were found and in 5 mixed hypopigmented classic lesions (Figs 1 and 2). The hypopigmented lesions were round or oval patches and/or flat plaques, with or without a scaly surface, and with well- or less-well defined borders. Of the 7 patients with hypopigmented lesions, 3 had light skin (types II or III) and 4 had pigmented skin (type IV). Nine patients were asymptomatic and one (patient 2) had pruritus. Routine evaluation, including serology for HTLV-1 and the T helper/T suppressor ratio, was normal in all patients.

Treatment included topical corticosteroids (mid to high potency) as monotherapy in 3 patients, psoralen and UVA (PUVA) in 4 patients, broad-band UVB in 2 patients, narrow-band UVB in 1 patient, topical tar and

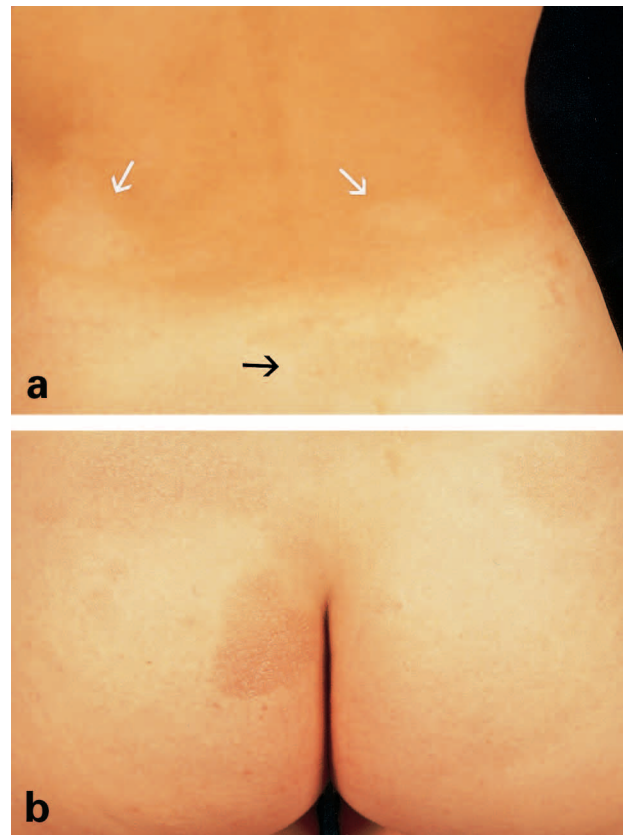


Fig. 2. (a) Hypopigmented non-scaly patches on the back (white arrows) of a light-skinned girl (patient no. 8) in association with a classical presentation of MF in the form of an erythematous patch (black arrow). (b) Classical erythematous patch/plaque on the buttocks.

sun exposure in 2 patients, topical nitrogen mustard in 3 patients and excision in 1 patient. Each modality was given either as the initial therapy or after failure with another therapy, i.e. after partial or no response, or during relapse (Table I). A final complete response was achieved in all patients except in patient no. 10, who is still receiving therapy with narrow-band UVB 3 times

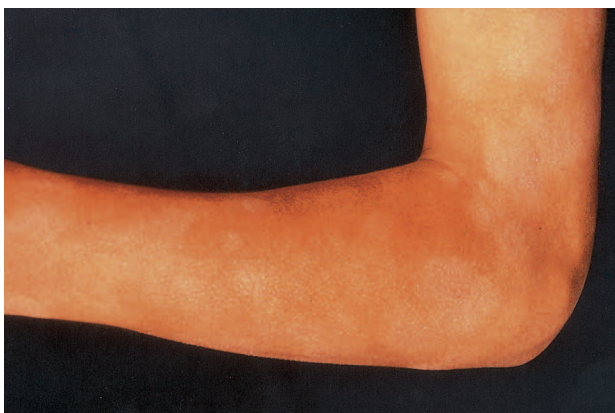

Fig. 1. Hypopigmented scaly patches on the external aspect of an upper limb, mimicking extensive pityriasis alba in a boy (patient no. 2) with pigmented skin.

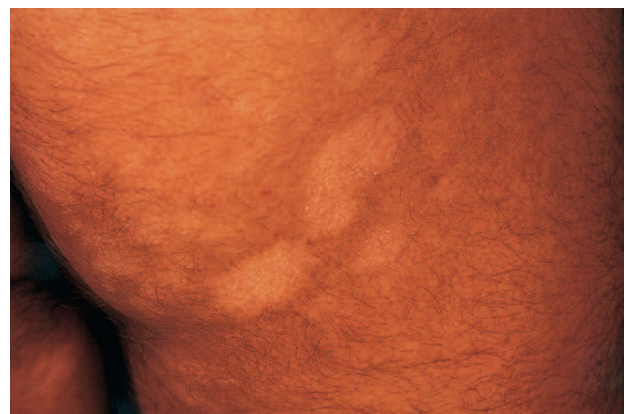

Fig. 3. Hypopigmented scaly patches on the buttocks of a boy (patient no. 10) with pigmented skin.

weekly (Fig. 3). Patients given phototherapy leading to complete response were gradually tapered out over a period of several months.

Follow-up ranged from 1 to 6.0 years (mean 3.4 years). Only one patient showed stage progression from Ia to IIa (patient no. 2) despite treatment with broadband UVB and topical tar followed by topical nitrogen mustard. He developed prominent axillary and inguinal lymphadenopathy which histologically was dermatopathic lymphadenopathy.

Histopathological, immunohistochemical and genotypic findings

All biopsy specimens revealed changes of early MF. Single atypical lymphocytes with minimal spongiosis were present in the epidermis, in some cases aligning the basement membrane and in six forming Pautrier's microabscesses. Adnexotropism was occasionally noted. Necrotic keratinocytes or prominent vascular alteration of the dermoepidermal junction were not seen. The upper dermis contained variable perivascular or lichenoid lymphocytic infiltrates with melanophages noted in a minority of cases (Fig. 4a). Immunohistochemically, in 7 of the 10 cases the epidermotropic cells were CD3+, expressing CD4+ on their surfaces ($\geq 80\%$ of the T cells). In 3 cases, however, there was a decreased

CD4/CD8 ratio in the epidermis. In 2 of these cases almost all of the T cells exclusively expressed CD8 with preference for the junctional zone, whereas the perivascular dermal lymphocytes were predominantly CD3+, CD4+, CD8- (Fig. 4b-d); in one, CD8+ T cells represented about 70% of the epidermotropic T lymphocytes with an equivalent number of CD4+ and CD8+ T cells in the dermis. Four of the 6 patients studied were found to have a reduction of CD7+ cells ($<30\%$ of the T cells); 3 of these had a CD4+ phenotype and one had a CD8+ phenotype. PCR analysis of the TCR γ -gene was performed in 6 of the 10 patients, 3 with CD4+ phenotype (patients 2, 5, 7) and 3 with CD8+ phenotype (patients 1, 4, 9). Evidence for monoclonal rearrangement of the TCR γ -gene was found in one patient with a CD8+ phenotype (patient no. 4).

DISCUSSION

In the past, clinicians have become more aware of the possibility of MF in childhood and the number of publications on paediatric MF has increased (2, 3, 7-15). Nevertheless, data regarding clinical symptoms, treatment and prognosis are still sparse and the true incidence of early-onset MF remains to be determined. We describe

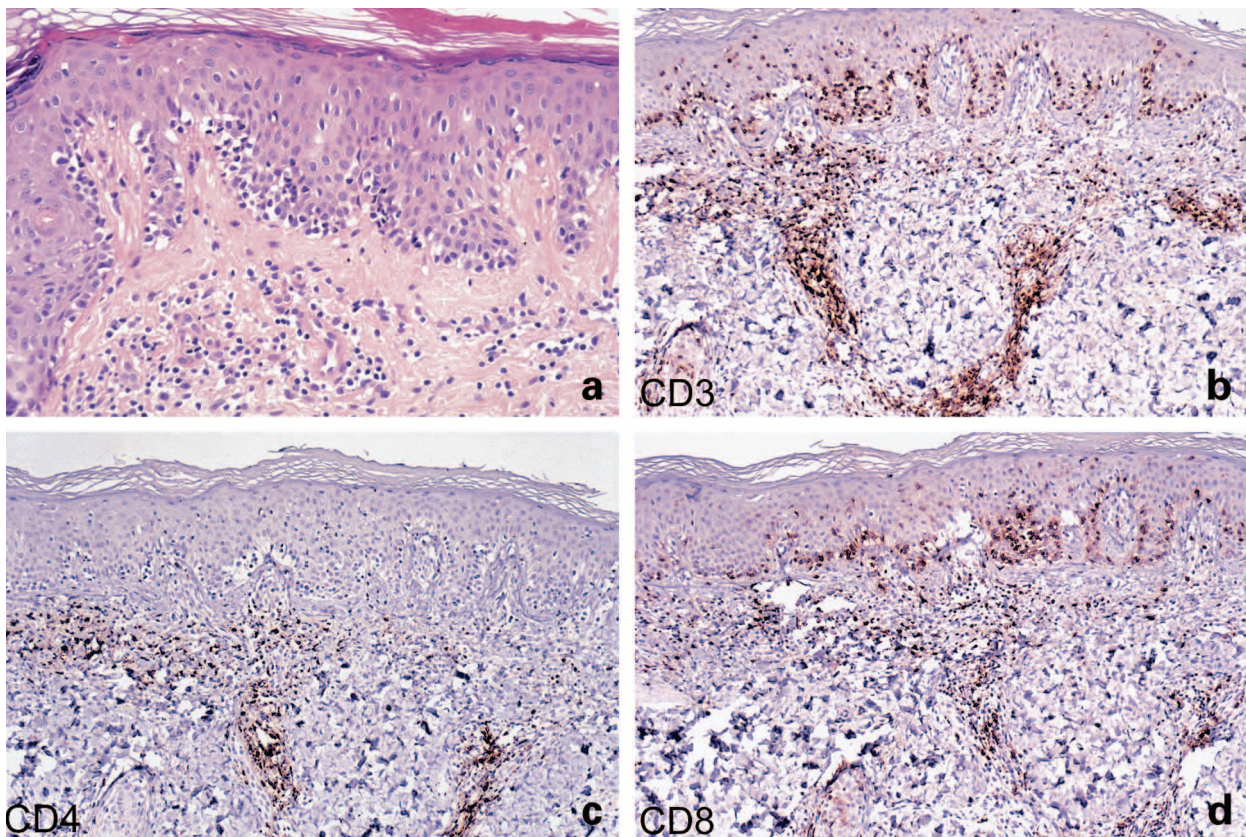


Fig. 4. (a) Lining up of epidermotropic atypical lymphocytes among basal keratinocytes at the dermoepidermal junction in patient no. 4. (H; original magnification $\times 200$). (b-d) Immunohistochemical features (original magnification $\times 100$). Note the presence of CD3+, CD4-, CD8+ lymphocytes in the epidermis with junctional preference, whereas the dermal lymphocytes are predominantly CD3+, CD4+, CD8-.

here 10 patients in whom MF was diagnosed before the age of 18 years.

As previously, the correct diagnosis of MF was delayed, in half of our patients the interval from onset of the eruption to the histopathologic examination and diagnosis was 7 years or longer, and in 2 as long as over 10 years. In half of our patients the initial diagnoses were different types of benign dermatoses, including pityriasis alba, psoriasis, nummular eczema and vitiligo. In many patients with MF described in the literature (7, 9, 16) the cutaneous lesions appeared in childhood, but the correct diagnosis was reached only in adulthood.

Apart from the classical Alibert-Bazin type of MF (patch, plaque, tumour) several unusual variants of MF have been reported in children (12, 17, 18). The hypopigmented variant of MF is known to have a particular propensity for younger patients (9, 19) and is found almost exclusively in individuals with black or dark skin (12, 19). It has been reported present in 20.4% of all paediatric patients with MF (11), usually without any pruritus (12) and in combination with classical lesions of MF. Macular hypopigmentation as the sole manifestation of MF in childhood has been reported in only a few cases (19, 20). In the present series, 7 patients presented with hypopigmented lesions, including 2 with macular hypopigmentation as the sole manifestation. This can be explained by the high percentage of patients with pigmented skin, although 3 of our patients with hypopigmented lesions had light complexions. Hypopigmented MF in light-skinned patients has rarely been described in the literature (21–24).

Most of the reported patients diagnosed to have MF during childhood and adolescence, as in our series, had early-stage disease. In their comprehensive review from 1999, Quaglino et al. (11) found that 91.8% had patch and/or plaque disease, whereas only 8.2% had nodular lesions at onset.

It is of particular interest that 2 of the patients in our series, previously reported by us (25), exhibited a solitary lesion of MF of long duration; one of them presented with a hypopigmented patch and thus represented a hypopigmented variant of unilesional MF. Recently, a solitary lesion of MF was found in one of 10 cases (14) and in another series in 2 of 5 cases of childhood MF (15). It is conceivable that unilesional MF is, in fact, more common in the children than is reflected in the literature. Furthermore, since unilesional MF is an extremely rare presentation of MF in adults (27), it would appear that it may be over-represented in the paediatric group.

Immunophenotypically, the majority of our patients, as well as those in the literature (8), exhibited a CD4+ T helper cell phenotype, similarly to adults with MF. However, in 3 of our patients the epidermis predominantly or exclusively showed CD8+ T-cells. A predominance of CD8+ cells has been found in 5% of

adult patients (26), and some of these had rapidly progressive disease (27), whereas others had a non-aggressive clinical behaviour (28). Whittam et al. (14) described 10 cases of childhood MF in which 6 patients had a CD8+ immunophenotype with an indolent course. Even more recently, El Shabrawi-Caelen et al. (30) reported 15 patients with hypopigmented MF with an indolent course; 9 of these had a CD8+ T-cell phenotype, and of these 7 were under the age of 20 years. On the basis of the two aforementioned reports as well as two previous case reports (16, 22) and our own experience, it can be concluded that CD8+ MF is over-represented in the paediatric age group, as already suggested (14).

Since one of our 3 patients and at least one of 6 patients in a previous report (14) with CD8+ immunophenotype had classical lesions of MF, it would appear that this unusual phenotype of CTCL is not exclusive for the hypopigmented variant of MF. It is of interest that in 2 of our patients there was a CD8+ cell infiltrate showing an exclusive junctional affinity in the epidermis with reactive dermal cells composed predominantly of CD4+ cells; this finding is similar to that described very recently in 3 adult patients with hyperpigmented patches and termed junctional CD8+ cutaneous lymphoma (28).

Whether in cases of CD8+ MF the CD8+ cells represent only tumour cells or whether some are also reactive T cells is a matter for further study. In this regard it is of interest that in MF patients with the usual CD4+ phenotype, CD8+ cytotoxic T lymphocytes were found to play an important role in the anti-tumour response (29).

In the early stage of the disease the neoplastic clone likely resides within the epidermis. By isolating intra-epidermal CD8+ T cells via microdissection and analysing the TCR γ -chain gene, El Shabrawi-Caelen et al. (30) were able to show that the malignant population was derived from CD8+ lymphocytes. It was therefore confirmed that their cases represented CD8+ CTCL. As for our cases, only in one of 3 CD8+ cases were we able to demonstrate clonality. This could be attributed to the very early stage of the disease in which even the PCR technique is below the threshold of detection of clonality. Likewise, El Shabrawi-Caelen et al. (30) were able to detect clonality in less than 50% of their cases (only in 33% among children).

Several types of treatment have been suggested for children and adolescents with MF, but there are no established protocols especially designed for this age group, so their management is the same as for adults. This includes topical nitrogen mustard (7, 8, 13), carmustine (7, 9), topical corticosteroids (14, 18), PUVA and UVB (7, 9, 18). Most recently, topical PUVA has been shown to be effective for patients with juvenile MF with plaque-stage disease (14). In our series the initial treatment was mid to high potent topical steroids, topical nitrogen mustard

and phototherapy. There are few reported cases in which maintenance PUVA or UVB phototherapy was given to children (13). In our patients maintenance therapy was given for only short periods.

Although the natural history of MF has been well described in adults, the data for paediatric MF are scarce and variable. Lamberg et al. (31) suggested that age has no significant effect on prognosis in MF after adjustment for stage of disease. Since all of our patients had early MF (Ia, Ib), at diagnosis their prognosis should conceivably be no different from that of adults.

In conclusion, juvenile MF is characterized by early stage disease, occasionally with unilesional presentation, usually with hypopigmented lesions irrespective of skin colour, and a good response to therapy. On the basis of our experience and review of the literature, the CD8+ phenotype appears to be over-represented in juvenile disease.

REFERENCES

- Weinstock MA, Horm JM. Mycosis fungoides in the United States. Increasing incidence and descriptive epidemiology. *JAMA* 1988; 260: 42–46.
- Agnarsson GA, Kadin ME. Peripheral T cell lymphomas in children. *Semin Diag Pathol* 1995; 12: 314–324.
- Peters MS, Thisbodeau SN, White JW, Winkelmann RK. Mycosis fungoides in children and adolescents. *J Am Acad Dermatol* 1990; 22: 1011–1018.
- Smoller BR, Bishop K, Glusac E. Reassessment of histologic parameters in the diagnosis of mycosis fungoides. *Am J Surg Pathol* 1995; 19: 1423–1430.
- Bergman R, Faclieru D, Sahar D, Sander CA, Kremer H, Ben-Aryeh Y, et al. Immunophenotyping and T-cell receptor γ gene rearrangement analysis as an adjunct to histopathological diagnosis of mycosis fungoides. *J Am Acad Dermatol* 1998; 39: 554–559.
- Bunn PA Jr, Lamberg SI. Report of the Committee on Staging and Classification of Cutaneous T-Cell Lymphomas. *Cancer Treat Rep* 1979; 63: 725–728.
- Koch SE, Zackheim HS, Williams ML, Fletcher V, LeBoit PE. Mycosis fungoides beginning in childhood and adolescence. *J Am Acad Dermatol* 1987; 17: 563–570.
- Hickham PR, McBurney EL, Fitzgerald RL. CTCL in patients under 20 years of age: a series of five cases. *Pediatr Dermatol* 1997; 14: 93–97.
- Zackheim HS, McCalmont TH, Deanovic FW, Odom RB. Mycosis fungoides with onset before 20 years of age. Review of 24 patients and report of a case diagnosed at age 22 months. *J Am Acad Dermatol* 1997; 36: 557–562.
- Crowley JJ, Nikko A, Varghese A, Hoppe RT, Kim YH. Mycosis fungoides in young patients: clinical characteristics and outcome. *J Am Acad Dermatol* 1998; 38: 696–701.
- Quaglino P, Zaccagna A, Verrone A, Dardano F, Bernengo MG. Mycosis fungoides in patients under 20 years of age: report of 7 cases, review of the literature and study of clinical course. *Dermatology* 1999; 199: 8–14.
- Garzon MC. Cutaneous T-cell lymphoma in children. *Semin Cutan Med Surg* 1999; 18: 226–232.
- Tan E, Tay YK, Giam YC. Profile and outcome of childhood mycosis fungoides in Singapore. *Pediatr Dermatol* 2000; 17: 352–356.
- Whittam LR, Calonje E, Orchard GE, Fraser-Andrews EA, Woolford A, Russell-Jones R. CD8 positive juvenile onset of mycosis fungoides: an immunohistochemical and genotypic analysis of six cases. *Br J Dermatol* 2000; 143: 1199–1204.
- Pabsch H, Rutten A, Von Stemm A, Weigel W, Sander CA, Schaller J. Treatment of childhood mycosis fungoides with topical PUVA. *J Am Acad Dermatol* 2002; 47: 557–561.
- Burns MK, Ellis CN, Cooper KD. Mycosis fungoides-type cutaneous T-cell lymphoma arising before 30 years of age. *J Am Acad Dermatol* 1992; 27: 974–978.
- Ko JW, Seong JY, Suh KS, Kim ST. Pityriasis lichenoides-like mycosis fungoides in children. *Br J Dermatol* 2000; 142: 347–352.
- Van Doorn R, Scheffer E, Willemze R. Follicular mycosis fungoides, a distinct disease entity with or without associated follicular mucinosis. A clinico-pathological and follow-up study of 51 patients. *Arch Dermatol* 2002; 138: 191–198.
- Lambroza E, Cohen SR, Phelps R, Lebowitz M, Braverman IM, DiCostanzo D. Hypopigmented variant of mycosis fungoides: demography, histology, and treatment of seven cases. *J Am Acad Dermatol* 1995; 32: 987–993.
- Neuhaus IM, Romos-Caro FA, Hassanein AM. Hypopigmented mycosis fungoides in childhood and adolescence. *Pediatr Dermatol* 2000; 17: 403–406.
- Sigal M, Grossin M, Laroche L, Basset F, Aitken G, Haziza JL, et al. Hypopigmented mycosis fungoides. *Clin Exp Dermatol* 1987; 12: 453–454.
- Amichai B, Grunwald MH, Avinoach I, Halevy S. Hypopigmented mycosis fungoides in a white female. *J Dermatol* 1996; 23: 425–426.
- Di Landro A, Marchesi L, Naldi L, Motta T, Cainelli T. A case of hypopigmented mycosis fungoides in a young Caucasian boy. *Pediatric Dermatol* 1997; 14: 449–452.
- Moulounguet I, Robert C, Baudot N, Flageul B, Dubertret L. Hypopigmented mycosis fungoides in a light-skinned woman. *Br J Dermatol* 1998; 139: 341–343.
- Hodak E, Fenig E, Amichai B, Feinmesser M, Kutar A, Maron L, et al. Unilesional mycosis fungoides. A study of seven cases. *Dermatology* 2000; 201: 300–306.
- Nasu K, Said J, Vonderheid E. Immunopathology of cutaneous T-cell lymphomas. *Am J Pathol* 1985; 119: 4346–4347.
- Agnarsson BA, Vonderheid EC, Kadin ME. Cutaneous T-cell lymphoma with suppressor/cytotoxic (CD8) phenotype: identification of rapidly progressive and chronic subtypes. *J Am Acad Dermatol* 1990; 22: 569–577.
- Dummer R, Kamarashev J, Kempf W, Huffner AC, Hess-Schmid M, Burg G. Junctional CD8+ cutaneous lymphomas with nonaggressive clinical behavior. A CD8+ variant of mycosis fungoides? *Arch Dermatol* 2002; 138: 199–203.
- Vermeer MH, van Doorn R, Dukes D, Bekkenk MW, Meijer CJLM, Willemze R. CD8+ T cells in cutaneous T-cell lymphoma: expression of cytotoxic proteins, Fas ligand, and killing inhibitory receptors and their relationship with clinical behavior. *J Clin Oncol* 2001; 23: 4322–4329.
- El Shabrawi-Caelen L, Cerroni L, Jefferey Medeiros L, McCalmont TH. Hypopigmented mycosis fungoides. Frequent expression of a CD8+ T-cell phenotype. *Am J Surg Pathol* 2002; 26: 450–457.
- Lamberg S, Green S, Byar D, Block JB, Clendenning WE, Douglas MC, et al. Clinical staging for cutaneous T-cell lymphoma. *Ann Intern Med* 1984; 100: 187–192.