

## Connubial Contact Dermatitis: An Unusual Pregnancy Dermatoses

Roland M Strauss<sup>1</sup>, Jens Bäte<sup>1</sup> and David Pring<sup>2</sup>

<sup>1</sup>Department of Dermatology, Leeds General Infirmary, Great George Street, Leeds LS1 3EX, UK and <sup>2</sup>Department of Obstetrics, York General Hospital, York, UK. E-mail: [strauss@strauss.karoo.co.uk](mailto:strauss@strauss.karoo.co.uk)  
Accepted January 16, 2003.

Sir,

Pregnancy is frequently complicated by skin abnormalities, which is a cause of concern for the obstetrician and dermatologist because some pregnancy dermatoses can cause severe illness and even be life-threatening. Most common dermatoses are eczema, polymorphic eruption of pregnancy, pruritic folliculitis, prurigo and pemphigoid gestationis, but no cases of contact dermatitis were noted in a review of 200 patients (1).

We report a 28-year-old and 7-month pregnant primigravida who presented with an acute inflammatory, erythematous, confluent macular skin eruption affecting her legs, lower back and lower abdomen, and ending in a clear-cut line above the umbilicus. Flexure sites such as groins, rima ani and popliteal fossae were spared (Fig. 1). She complained of severe itch, and a pregnancy-related dermatosis was suspected. The rash had started shortly after she had been wearing her husband's dungarees, which because of her increasing waistline were comfortable to wear. It emerged that her husband, a psoriasis sufferer, had been started on home treatment with a short contact dithranol regime. It turned out, however, that he had been only partially

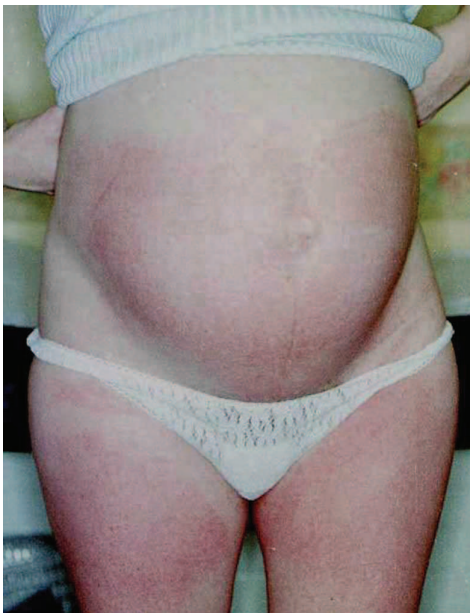


Fig. 1. Acute dermatitic reaction affecting abdomen, back and legs, sparing flexural folds.

compliant with the instructions and at times had failed to wash off the dithranol after 30 min in accordance with the instructions before putting on his dungarees. Dithranol residue found its way onto the inner layer of his trousers and had caused an irritating reaction in his wife. She stopped wearing her husband's trousers and thus halted her involuntary exposure to the irritant. The symptoms settled quickly.

Dithranol is an effective treatment for plaque psoriasis, but also a well-known irritant, with an evaluated irritation dose (ID 50) of 0.046% in 100 psoriatic patients and 0.057% in 100 controls, the difference being statistically not significant (2). For short contact dithranol treatment, concentrations of dithranol between 0.1% and 1% are usually used and therefore have a high potential to cause irritancy.

Connubial contact dermatitis in which contact dermatitis occurs to a substance used by the partner has been described for various substances, most commonly fragrances and hair dye materials, and in these cases an allergic contact dermatitis was reported in the husband of a woman using these substances (3–5).

To our knowledge, this is not only the first case of connubial contact dermatitis in which the causative agent is an irritant, it is also the first case in which the patient affected by contact dermatitis is the female partner.

This case once again emphasizes the importance of a thorough clinical history not just in dermatology but in all medical specialities.

## REFERENCES

1. Vaughan Jones SA, Hern S, Nelson-Piercy C, Seed PT, Black MM. A prospective study of 200 women with dermatoses of pregnancy correlating clinical findings with hormonal and immunopathological profiles. *Br J Dermatol* 1999; 141: 71–81.
2. Haustein UF, Lohrisch I. Irritant potential of dithranol. *Dermatologica* 1986; 173: 288–293.
3. Doooms-Goossens A, Swinnen E, Vandermaesen J, Marien K, Doooms M. Connubial dermatitis from a hair lotion. *Contact Dermatitis* 1987; 16: 41–42.
4. Leroy D, Dompmartin A. Connubial photosensitivity to musk ambrette. *Photodermatology* 1989; 6: 137–139.
5. Swinyer LJ. Connubial contact dermatitis from perfumes. *Contact Dermatitis* 1980; 6: 226.