

Pneumothorax Secondary to Ipsilateral Herpes Zoster Pectoralis

Sung-Wook Park¹, Seung-Hoon Kang¹, Deborah Lee¹, Han-Young Wang² and Ho-Suk Sung¹

¹Department of Dermatology, Busan Paik Foundation Hospital, Inje University Medical College, 633-165, Kaekum-Dong, Busanjin-Ku, Busan 614-735, Korea and ²Wang Han-Young Dermatology Clinic, Busan, Korea. E-mail: alopark@hanmir.com
Accepted February 25, 2003.

Sir,

Herpes zoster manifests as a result of the reactivation of varicella-zoster virus (VZV), in latent infection, in the sensory ganglia of the cerebral and spinal nerves. It is caused by various factors after childhood chicken-pox. The vesicular eruption clusters around the sensory nerve distribution and is accompanied by severe pain. As the skin lesion recovers dependent on the extent of necrotic eschar, sequelae such as depressed scar, Ramsay-Hunt syndrome, hearing loss and impaired vision remain (1).

When cough and dyspnea accompany ipsilateral pain in herpes zoster pectoralis patients, diseases such as pneumothorax should also be considered, and careful physical examination and routine laboratory tests should be carried out. We report a case of secondary pneumothorax which seemed to be caused by herpes zoster pectoralis.

CASE REPORT

A 57-year-old female patient was admitted to our ward because of severe pain and vesicular lesions along the dermatomes on the left chest and back lasting a week (Fig. 1). Her temperature was normal. She also had a mild dry cough and dyspnea that she had not had previously. Famciclovir (750 mg/day) and acetaminophen (1200 mg/day) were given, but with no marked alleviation of the pain or respiratory symptoms. She had had diabetes for about 10 years, which has been treated with tablets. Her complete blood count, liver and kidney function tests, and electrocardiography were all within normal ranges.

Routine chest X-ray taken at the time of admission, but not observed until 9 days later, showed complete collapse of the left lung and pneumothorax with a slight septal shift (Fig. 2A).

Immediately after verifying pneumothorax, a chest drainage tube was inserted into the left lung. After 2 days, dyspnea and cough improved as the lung re-expanded and normalized, while pain ipsilateral to the lesion continued but to some extent alleviated.

After 4 days, the chest drainage tube was removed and there was no recurrence of pneumothorax during the 2.5 year follow-up period. Structural abnormalities of obstructive lung diseases such as local bullae or pulmonary emphysema were not observed (Fig. 2B). Scars remained on the skin after the herpes zoster, but she had no respiratory symptoms such as cough or dyspnea.

DISCUSSION

The main complications of herpes zoster associated with the internal organs are oesophagitis, gastritis, enteritis, pleuritis, peritonitis, pneumonia, hepatitis, myocarditis, endocarditis and arthritis (1–3). A literature search of PubMed showed no reports of pneumothorax as a complication of herpes zoster.

The main causes of primary pneumothorax are ruptures of vesicles or cysts in the superior lobes of the lung and defects of pleura. It is more frequent in young men, with a prevalence six times higher than in women. It is likely to occur more frequently in winter in tall and skinny body types and in smokers, and manifests with sudden chest pain and dyspnea. Secondary pneumothorax is seen in patients with asthma, chronic obstructive pulmonary

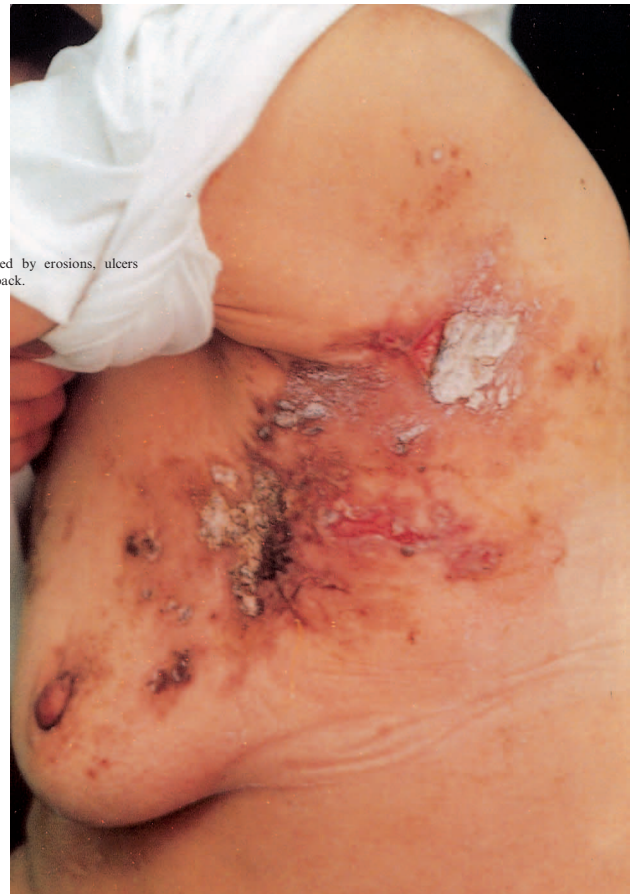

Fig. 1. Numerous vesicles have been replaced by erosions, ulcers and crusts along the left side of the chest and back.

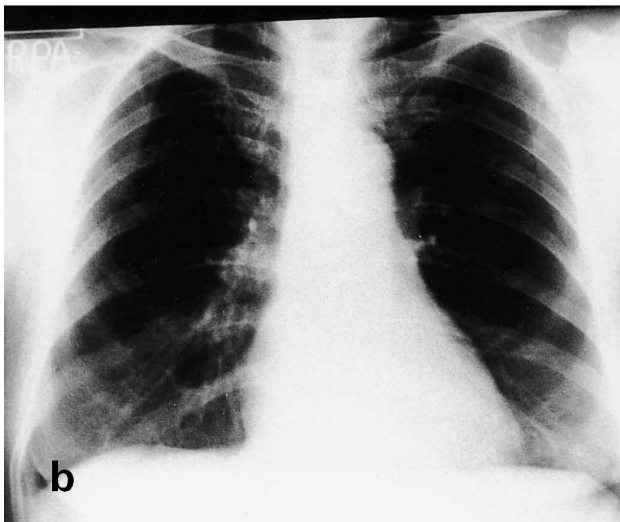
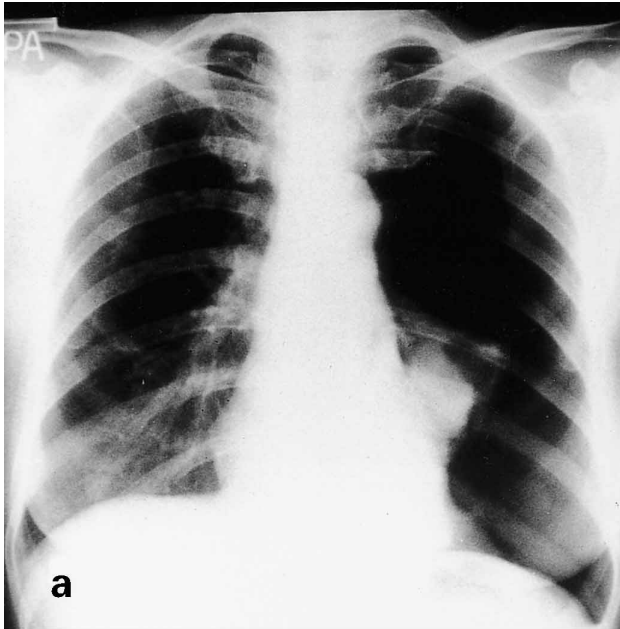


Fig. 2. A. Collapsed lung parenchyme in the left chest. B. Complete remission of the left pneumothorax after chest drainage which was performed 2.5 years previously.

disease, pneumonia, sepsis caused by *Staphylococcus aureus*, pulmonary abscess, tuberculosis, sarcoidosis, lung cancer, etc. (4, 5).

In our patient, secondary pneumothorax seemed to be caused by herpes zoster, which starts with respiratory symptoms and pneumothorax is located ipsilateral. Furthermore, there were no signs of pneumonia on the chest X-ray, physical examinations, or the laboratory findings. Immediately after the lung expansion, there were no structural abnormalities associated with obstructive lung diseases on the chest X-ray taken one month later and no respiratory symptoms at later follow-up. It is possible that the nerves located in the parietal pleura become severely inflamed by VZV, and that this inflammation causes the adhesion of parietal pleura and visceral pleura, which results in the exposure of lung parenchyme causing the secondary pneumothorax. When herpes zoster occurs on the chest, pain caused by diseases such as pleuritis, pneumonia, pulmonary embolism, myocardial infarction or pneumothorax that can occur ipsilaterally may easily be overlooked (6). Careful physical examinations and routine laboratory tests, including chest X-ray, are therefore needed.

ACKNOWLEDGEMENT

We thank Young-Min Lee, MD, of the Department of Pulmonology of Internal Medicine, Kang-Joo Choi, MD, and Hee-Jae Jun, MD, of the Department of Chest Surgery, Inje University, Busan, Korea, for their constructive comments.

REFERENCES

1. Straus SE, Oxman MN. Varicella and herpes zoster. In: Freedberg IM, Eisen AZ, Wolff K, et al., eds. *Dermatology in general medicine*, 5th edn. New York: McGraw-Hill, 1999: 2427–2450.
2. Fleisher G, Henry W, McSorley M, Arbeter A, Plotkin S. Life-threatening complications of varicella. *Am J Dis Child* 1981; 135: 896–899.
3. Triebwasser JH, Harris RE, Bryant RE, Rhoades ER. Varicella pneumonia in adults. Report of seven cases and a review of the literature. *Medicine (Baltimore)* 1967; 46: 409–423.
4. Schramel FM, Postmus PE, Vanderschueren RG. Current aspect of spontaneous pneumothorax. *Eur Respir J* 1997; 10: 1372–1379.
5. Jantz MA, Pierson DJ. Pneumothorax and barotrauma. *Clin Chest Med* 1994; 15: 75–91.
6. Meier-Sydow J. Pulmological aspects of diagnosis of thoracic pain. *Munch Med Wochenschr* 1980; 122: 745–750.