

Deep Dermatophytosis During Topical Tacrolimus Therapy for Psoriasis

Toshiyuki Yamamoto and Kiyoshi Nishioka

Department of Dermatology, Tokyo Medical and Dental University, School of Medicine, 1-5-45 Yushima, Bunkyo-ku, Tokyo 113-8519, Japan. E-mail: yamamoto.derm@med.tmd.ac.jp

Accepted February 20, 2003.

Sir,

Tacrolimus (FK 506) is an immunosuppressive agent isolated from the fermentation broth of *Streptomyces tsukubaensis* (1) and has a spectrum of activity similar to that of cyclosporine. Both systemic and local tacrolimus have been shown to be effective in the treatment of inflammatory skin disorders such as severe psoriasis, pyoderma gangrenosum, atopic dermatitis, lichen planus and alopecia areata (2, 3). We have recently reported that topical application of tacrolimus ointment is effective for treating facial psoriasis (4). Here we describe a case of deep dermatophytosis in the face of a patient suffering

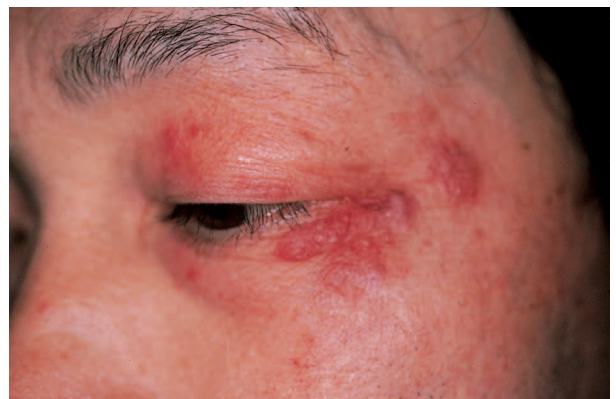


Fig. 1. Several red papules near the lower eyelid.

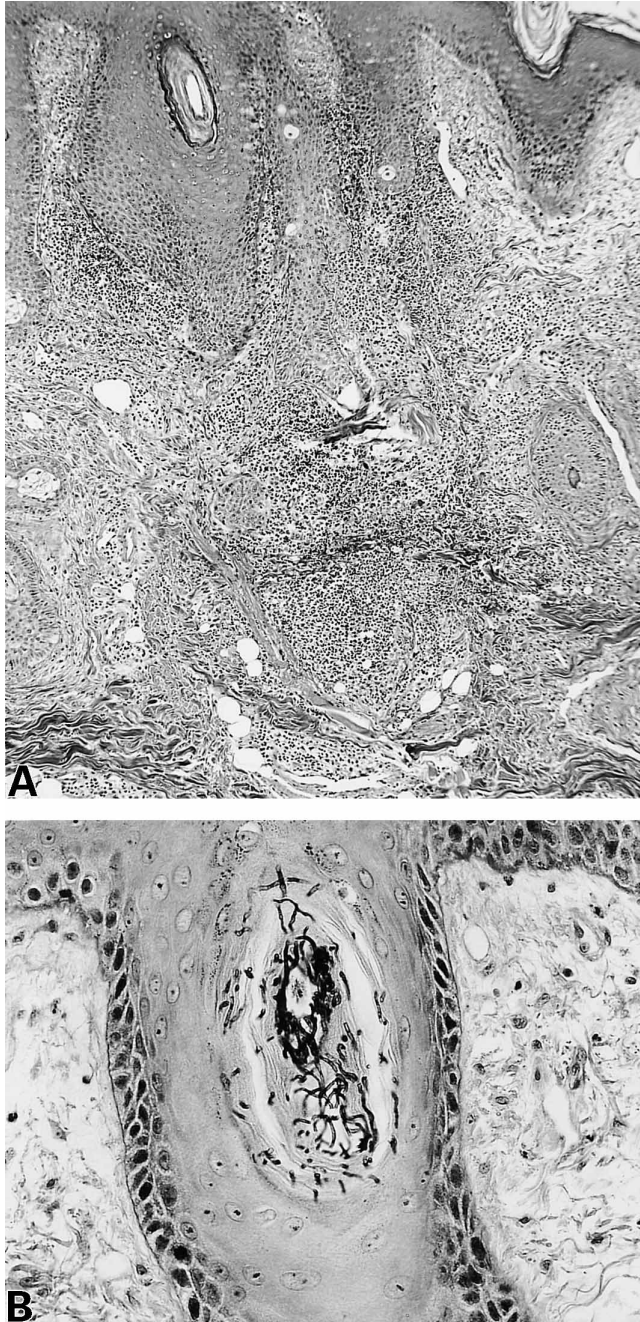


Fig. 2. (A) Dense cellular infiltrates mainly composed of neutrophils in the upper- to mid-dermis. (B) A number of spores in the follicle (PAS stain).

from psoriasis and treated with topical tacrolimus therapy.

CASE REPORT

A 49-year-old male had been suffering from psoriasis vulgaris for more than 10 years and had been treated with oral etretinate combined with topical steroid ointment.

He also had untreated tinea pedis. After informed consent had been obtained, topical 0.1% tacrolimus ointment (Protopic) was applied to his facial psoriasis twice a day. One month later, he complained of itchy papules around the left eye, and physical examination revealed several red papules near the lower eyelid (Fig. 1). Herpes simplex virus infection was suspected and topical tacrolimus was stopped and anti-viral tablets were prescribed. Two weeks later, however, the lesions had not improved, but rather had spread to the cheeks and forehead. Physical examination by the KOH method revealed tinea corporis. A biopsy specimen from the facial lesion revealed dense infiltration of neutrophils in the upper- to mid-dermis (Fig. 2A). Periodic acid Schiff (PAS) staining showed a number of spores distributed in the follicles (Fig. 2B). Oral terbinafine hydrochloride (125 mg/day) improved the cutaneous eruptions within 4 weeks.

DISCUSSION

The most common adverse effects of topical tacrolimus therapy are sensation of skin burning, pruritus, flu-like symptoms, skin erythema and headache (5). Herpes simplex infection is occasionally seen during topical tacrolimus therapy, and after up to 6 or 12 months of treatment with 0.1% tacrolimus ointment, herpes simplex is found in the ratio of 13% (6). Since skin infections are potential complications of topical treatment with immunosuppressive agents, it is speculated that tacrolimus suppresses the local immune balance. Although it is well known that fungal infection is associated not only with systemic but also with topical steroid therapy, deep dermatophytosis has not been reported during topical tacrolimus therapy. It should be kept in mind that deep fungal infection can be induced by topical tacrolimus ointment.

REFERENCES

1. Kino T, Hatanaka H, Miyata S, Inamura N, Nishiyama M, Yajima T, et al. FK-506, a novel immunosuppressant isolated from streptomyces. II: Immunosuppressive effect of FK-506 in vitro. *J Antibiot (Tokyo)* 1987; 40: 1256–1265.
2. Ruzicka T, Assmann T, Homey B. Tacrolimus. The drug for the turn of the millennium? *Arch Dermatol* 1999; 135: 574–580.
3. Skaehill PA. Tacrolimus in dermatologic disorders. *Ann Pharmacother* 2001; 35: 582–588.
4. Yamamoto T, Nishioka K. Topical tacrolimus is effective for facial psoriasis. *Acta Derm Venereol* 2000; 80: 451.
5. Soter NA, Fleischer Jr AB, Webster GF, Monroe EM, Lawrence I, and the tacrolimus ointment study group. Tacrolimus ointment for the treatment of atopic dermatitis in adult patients: Part II, safety. *J Am Acad Dermatol* 2001; 44: S39–S46.
6. Reitamo S, Wollenberg A, Schöpf E, Perrot JL, Marks R, Ruzicka T, et al. Safety and efficacy of 1 year of tacrolimus ointment monotherapy in adults with atopic dermatitis. *Arch Dermatol* 2000; 136: 999–1006.