

Urticaria-Like Follicular Mucinosis Responding to Dapsone

F. Al Harthi, A. Kudwah, A. Ajlan, A. Nuaim and F. Shehri

Department of Dermatology, Riyadh Armed Forces Hospital, P.O. Box 7897, Riyadh 11159, Kingdom of Saudi Arabia.

E-mail: fharthi@yahoo.com

Accepted April 25, 2003.

Sir,

Mucin is a jelly-like amorphous mixture of glycosaminoglycans, mainly hyaluronic acid and dermatin sulphate bound to small amounts of chondroitin sulphate and heparin sulphate. Mucinous infiltration of the skin occurs in disorders in which mucin accumulates either diffusely or focally. The disorders either affect the skin only or are related to systemic disease. Follicular mucinosis can be idiopathic or lymphoma-associated. We report a rare case of urticaria-like follicular mucinosis that responded to dapsone.

CASE REPORT

A 25-year-old man presented with a 2-year history of itchy facial lesions which were recurrent, but had recently become more persistent. On examination, he was found to have multiple red urticaria-like papules and infiltrated plaques on an erythematous background. The lesions involved the face (Fig. 1a), and central areas of the chest and the back. Hairy areas were affected, but there was no alopecia. Other parts of the skin were normal and systemic examination was normal. Sun exposure did not affect the lesions and

there was no significant seasonal variation. The patient was not on any medication prior to the eruption. Laboratory tests, including immunological tests for SLE, uro- and coproporphyrins, and syphilis serology showed no abnormalities. Two skin biopsies, one from the face and another from the back, showed superficial and mid-dermal perivascular and perifollicular lymphocytic infiltrates rich in eosinophils. The epidermis showed spongiosis, irregular elongation of rete ridges with features of vigorous scratching and scale crust formation that were more prominent in the biopsy taken from the face. The hair follicles contained a pool of mucin (highlighted by alcian blue in Fig. 2). There was no evidence of lymphocytic atypia, epidermotropism or any feature of lymphoid malignancy. Previous treatment with local corticosteroids, minocycline and isotretinoin did not help. He was given a course of oral prednisolone, but with no improvement. Dapsone was started 100 mg once daily and within 6 weeks all lesions had disappeared (Fig. 1b).

Later, the dose of dapsone was reduced to 50 mg once daily, but after 2 weeks a few similar lesions recurred on the face; the dose was therefore increased

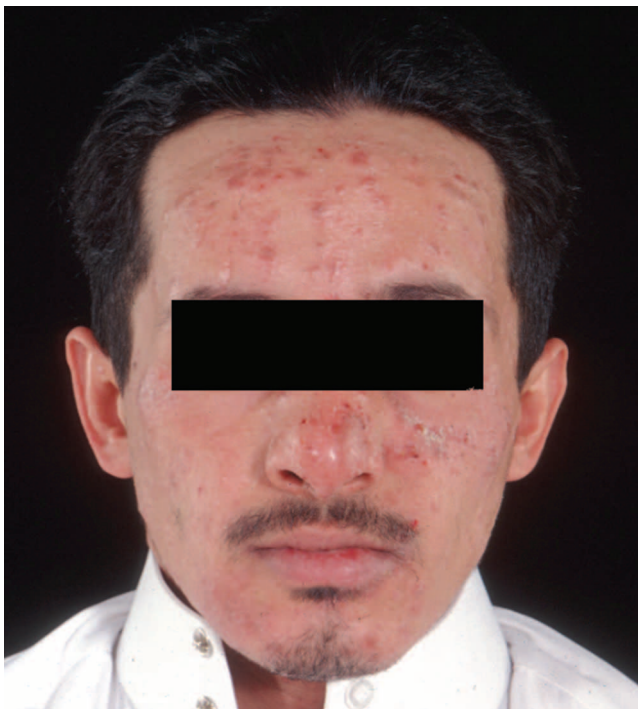

Fig. 1(a). Red urticated papules and plaques on the face (note: hairs are preserved).

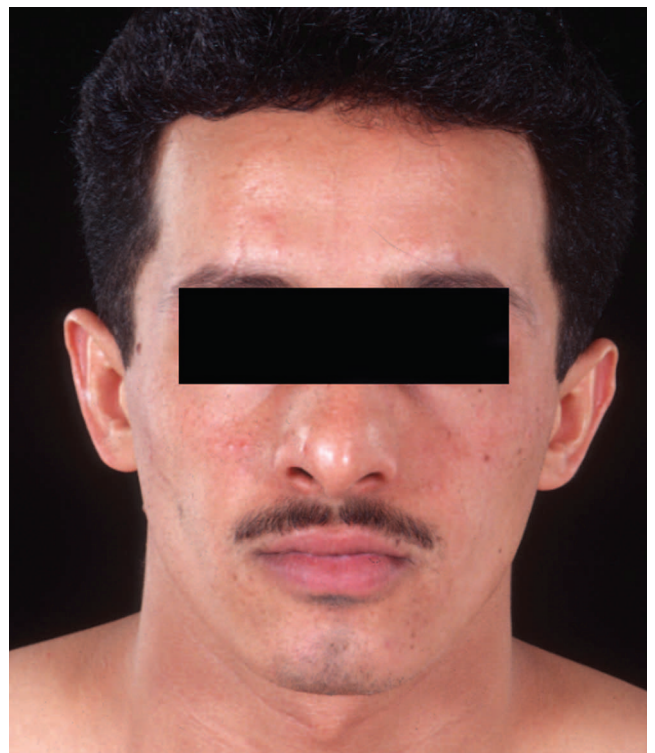

Fig. 1(b). Post-treatment showing complete resolution of the lesions.

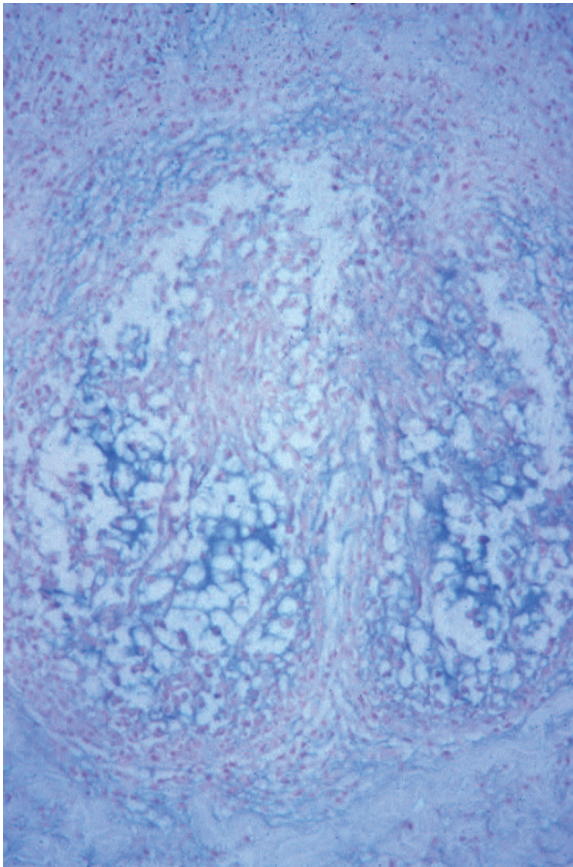


Fig. 2. The alcian blue confirms the mucinous nature of the clear spaces by staining blue (alcian blue $\times 40$).

to 100 mg with complete improvement. The patient is still on dapsone 100 mg once daily and after 5 months there has been no recurrence.

DISCUSSION

Follicular mucinosis can be divided into an idiopathic type, which has a benign course, and a lymphoma-associated type. Criteria previously reported to differentiate between these two types proved ineffective (1). There is no single clinical or histopathologic observation predicting which patients will have a benign course (2).

Urticaria-like follicular mucinosis is a rare form that usually affects middle-aged men and presents with recurrent urticarial pruritic papules or plaques on the head and neck on an erythematous background. Hairy

areas may be affected, but alopecia does not occur. There is no associated lymphoma (3, 4). Some cases of follicular mucinosis improve spontaneously. Treatment with topical, intralesional or systemic steroids, anti-malarials, interferon, dapsone, minocycline and isotretinoin has produced variable results (5–10).

Our patient has urticaria-like follicular mucinosis, which is a rare variant of follicular mucinosis. His urticarial papules and plaques occurred in the seborrhoeic areas on his face, chest and back. His lesions were not associated with alopecia and there were no features of lymphoma. Different types of treatment have been tried, including minocycline, isotretinoin, local and systemic steroids, but all have failed to improve the disease. There was no evidence of spontaneous improvement. Dapsone usage, however, resulted in complete clearance of his lesions.

REFERENCES

1. Cerroni L, Fink-Puches R, Back B, Kerl H. Follicular mucinosis: a critical reappraisal of clinicopathologic features and association with mycosis fungoides and Sezary syndrome. *Arch Dermatol* 2002; 138: 182–189.
2. Gibson LE, Muller SA, Leiferman KM, Peters MS. Follicular mucinosis: clinical and histopathologic study. *J Am Acad Dermatol* 1989; 20: 441–446.
3. Enjolras O, Guillemette J, Hewitt J. Dermatose ortice mucinose folliculaire. *Ann Derm Venerol* 1980; 107: 491–495.
4. Crovato F, Nazzari G, Nunzi E, Rebora A. Urticaria-like follicular mucinosis. *Dermatologica* 1985; 170: 133–135.
5. Kubba RK, Stewart TW. Follicular mucinosis responding to dapsone. *Br J Dermatol* 1974; 91: 217–220.
6. Fairris GM, Kirkham N, Goodwin PG, Leppard BJ, White JE. Erythrodermic follicular mucinosis. *Clin Exp Dermatol* 1987; 12: 50–52.
7. Rustin MHA, Bunker CB, Levene GM. Follicular mucinosis presenting as acute dermatitis and response to dapsone. *Clin Exp Dermatol* 1989; 14: 382–384.
8. Meissner K, Weyer U, Kowalzik L, Alte'nhoff J. Successful treatment of primary progressive follicular mucinosis with interferons. *J Am Acad Dermatol* 1991; 24: 848–850.
9. Yotsumoto S, Uchimiya H, Kanzaki T. A case of follicular mucinosis treated successfully with minocycline. *Br J Dermatol* 2000; 142: 841–842.
10. Guerriero C, De Simone C, Guidi B, Rotoli M, Venier A. Follicular mucinosis successfully treated with isotretinoin. *Eur J Dermatol* 1999; 9: 22–24.