

Subcorneal Pustular Dermatitis and *Mycoplasma pneumoniae* Respiratory Infection

Manuela Papini, Michela Cicoletti and Priscilla Landucci

Dermatology Clinic of Terni, Perugia University, Azienda Ospedaliera S. Maria, Via T. di Joannuccio, IT-05100 Terni, Italy.

E-mail: dermatr@unipg.it

Accepted April 25, 2003.

Sir,

Subcorneal pustular dermatosis (SPD) is an uncommon, chronic/recurrent, pustular eruption characterized by subcorneal sterile pustules involving mainly the abdomen and the large folds. Originally described in 1956 by Sneddon & Wilkinson (1), the condition can be ascribed to the complex group of neutrophilic dermatoses (2). The pathophysiology underlying SPD is presently unknown, but the disease has frequently been described in association with systemic disorders, i.e. myeloproliferative disorders, inflammatory bowel diseases and rheumatoid arthritis (3).

We report a case of SPD possibly triggered by a *Mycoplasma (M.) pneumoniae* respiratory infection.

CASE REPORT

An 8-year-old boy was admitted to the Paediatric Clinic of our hospital because of a severe infection of the respiratory tract with asthmatic symptoms and a body temperature of 39.2°C. Onset of the respiratory problems dated back 10 days, during which he had been unsuccessfully treated with oral amoxicillin/clavulanic acid. Routine haematological analysis showed mild leucocytosis and increased values of the sedimentation rate, C-reactive protein, and IgE (180 kU/ml). Chest X-ray examination revealed interstitial pneumonia with uneven parenchymal dense areas in the middle and lower lobe of both lungs. *M. pneumoniae* enzyme-linked immunosorbent assay was compatible with a recent infection, showing an IgM titre > 64. Serological studies for *Chlamydia*, *Legionella pneumophila* and a respiratory virus panel failed to show any seroconversion. Sputum cultures were negative. The diagnosis of *M. pneumoniae* respiratory infection was made and the patient was treated with oral clarithromycin 250 mg b.i.d. and inhaled corticosteroids. Four days after therapy had been initiated the patient became afebrile and the asthma symptoms were resolved, but an itching vesicular skin eruption arose. The paediatrician prescribed an antiseptic cream. The skin lesions subsided promptly and the patient was discharged from hospital. However, after 48 h a relapse of the skin eruption was observed and the boy was referred to our Dermatology outpatient service.

Crops of flaccid vesicles and pustules up to 1 cm in diameter were present on normal skin of the trunk (Fig. 1). The larger pustules showed a characteristic accumulation of the pus in the lower half of the lesion. Rupture and/or dry up of the pustules resulted in the formation of thin superficial scales and crusts

closely resembling impetigo. Face, scalp, palms, soles, nails and mucous membranes were normal.

Histological examination of an early lesion (Fig. 2) showed a subcorneal blister containing neutrophils and scanty mononuclear cells. The underlying epidermis exhibited minimal spongiosis with a few migrating leucocytes. The dermis contained a perivascular infiltrate comprising neutrophils, occasional eosinophils and mononuclear cells. Direct immunofluorescence failed to show any immunoglobulin deposition. Bacteriological, mycological and virological cultures of pus remained negative. Serum protein electrophoresis was in the normal range and serum immunoblotting did

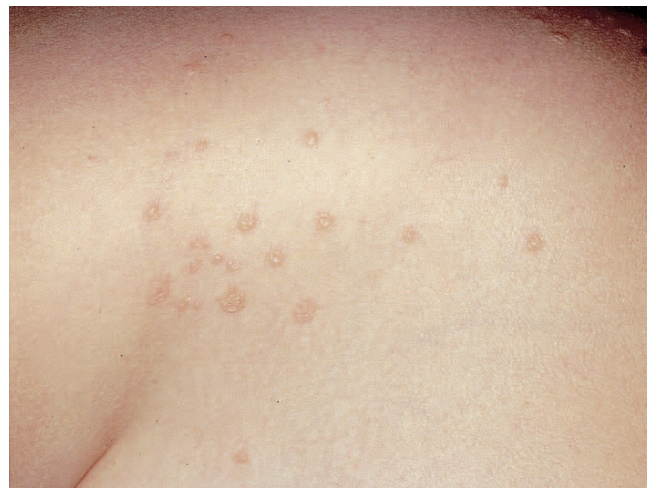

Fig. 1. Flaccid vesicles and pustules up to 1 cm in diameter on normal skin of the trunk.

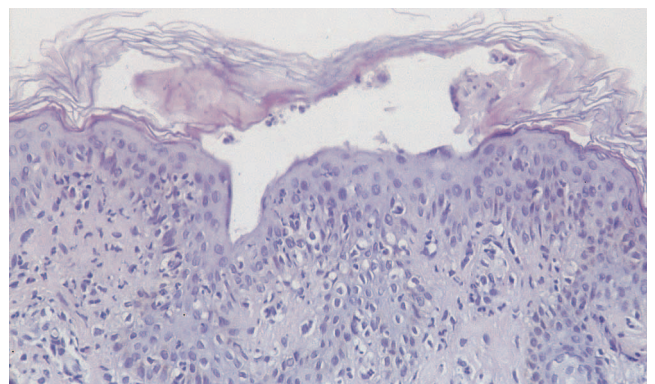


Fig. 2. A subcorneal unilocular vesicle containing neutrophils. The epidermis exhibits minimal spongiosis with a few migrating leucocytes. The underlying dermis shows a perivascular infiltrate with neutrophils, scant eosinophils and mononuclear cells (haematoxylin and eosin; original magnification $\times 250$).

not show any auto-antibody against either epidermal or dermo-epidermal junction antigens.

The diagnosis of SPD was proposed and the patient underwent treatment with dapsone 25 mg/day. The eruption of new lesions stopped in 5 days and a complete cure was obtained in one month. No relapse occurred after dapsone discontinuation and the patient was free of lesions at the 2- and 6-month follow-up. A challenge test with oral clarithromycin was then performed in order to rule out a causal role of this drug. Two doses of 125 mg clarithromycin failed to induce recurrence of the skin lesions.

DISCUSSION

The clinical and histological findings of our patient were typical of the SPD, although in this case the skin lesions did not show a chronic relapsing course. Our case is similar to that observed by Winnock et al. (4) in a 43-year-old man who developed an itching vesicular-pustular eruption compatible with classical SPD during a severe *M. pneumoniae* respiratory infection. The cases reported by Sneddon (5) and Reichert-Penetrat et al. (6) also display similarities with our patient. In both cases, *M. pneumoniae* infection was associated with a complex eruption characterized by unilocular subcorneal pustules compatible with SPD and mucocutaneous lesions typical of a Stevens-Johnson syndrome. Reichert-Penetrat et al. (6) concluded that their patient was affected by a rare clinical form of Stevens-Johnson syndrome, which is well known as a disorder frequently linked to *M. pneumoniae* infection. Our case showed clinical and histological findings typical of SPD and was probably triggered by an acute *Mycoplasma* infection. This presumed association could also explain the acute course of the skin disease without relapse after dapsone discontinuation.

Sneddon-Wilkinson disease is a rare condition that is not easily diagnosed. It should be differentiated from other bullous/pustular eruptions, in particular from acute generalized exanthematous pustulosis, dermatitis herpetiformis, eosinophilic pustular folliculitis, impetigo, pemphigus foliaceus and pustular psoriasis. The relationship between SPD and IgA pemphigus is still being elucidated, but a subgroup referred to as “intraepidermal

IgA pustulosis” and “SPD-type IgA pemphigus” is clinically indistinguishable from classical Sneddon-Wilkinson disease (3). The association of SPD with chronic systemic disorders such as monoclonal gammopathy, inflammatory bowel diseases and rheumatoid arthritis is well recognized, while the association with acute or chronic infections is extremely rare. Although the pathogenesis of this dermatitis is still unknown, elevated levels of TNF- α in monocytes and serum have been reported in patients with SPD (7). *M. pneumoniae* infection induces Th1-polarized CD4+ T-cell immunity associated with an increased level and prolonged expression of several cytokines, including TNF- α (8). So we suggest that a TNF- α dependent neutrophil activation may play a role in this association. However, it remains unclear why an infection as common as *M. pneumoniae* only evokes SPD in rare cases.

REFERENCES

1. Sneddon IB, Wilkinson DS. Subcorneal pustular dermatosis. *Br J Dermatol* 1956; 68: 385–394.
2. Vignon-Pennamen MD, Wallach D. Cutaneous manifestations of neutrophilic disease. A study of seven cases. *Dermatologica* 1991; 183: 255–264.
3. Reed J, Wilkinson JD. Subcorneal pustular dermatosis. *eMedicine Journal* [serial online] 2002 Feb [cited 2002 Feb 27]; 3 (2): [7 screens]. Available from: URL: http://www.emedicine.com/derm/topic_409.htm.
4. Winnock T, Wang J, Suys E, De Coninck A, Roseeuw D. Vesiculopustular eruption associated with *Mycoplasma pneumoniae* pneumopathy. *Dermatology* 1996; 192: 73–74.
5. Sneddon IB. Subcorneal pustules in erythema multiforme. *Br J Dermatol* 1973; 88: 605–607.
6. Reichert-Penetrat S, Barbaud A, Antunes A, Borsa Dorion A, Vidailhet M, Schmutz JL. An unusual form of Stevens-Johnson syndrome with subcorneal pustules associated with *Mycoplasma pneumoniae* infection. *Ped Dermatol* 2000; 17: 202–204.
7. Grob JJ, Mege JL, Capo C, Jancovicci E, Fournier JR, Bongrand P, et al. Role of tumor necrosis factor- α in Sneddon-Wilkinson subcorneal pustular dermatosis. A model of neutrophil priming in vivo. *J Am Acad Dermatol* 1991; 25: 944–947.
8. Opitz O, Pietsch K, Ehlers S, Jacobs E. Cytokine gene expression in immune mice reinfected with *Mycoplasma pneumoniae*: the role of T-cell subsets in aggravating the inflammatory response. *Immunobiology* 1996–97; 196: 575–587.