

## A *de Novo* Mutation in the Keratin 9 Gene in a Family with Epidermolytic Palmoplantar Keratoderma from Northern Sweden

Lena M. Wennerstrand<sup>1</sup>, Melker Häggbom Klingberg<sup>1</sup>, Per-Åke Hofer<sup>2</sup>, Anita Lundström<sup>2</sup> and Lisbet K. Lind<sup>1</sup>

<sup>1</sup>Department of Medical Biosciences, Medical Genetics, Umeå University, SE-901 85 Umeå, Sweden, and <sup>2</sup>Department of Public Health and Clinical Medicine, Dermatology, Umeå University, SE-901 85 Umeå, Sweden. E-mail: lisbet.lind@medbio.umu.se  
Accepted November 5, 2002.

Sir,

Palmoplantar keratodermas (PPKs) constitute a heterogeneous group of skin disorders with the distinctive trait of hyperkeratosis of palmoplantar skin. The disorders are classified clinically by the morphology and distribution of the hyperkeratosis, the presence of associated cutaneous and non-cutaneous features and by the mode of transmission (1, 2).

Familial diffuse epidermolytic PPK (EPPK) is the most studied keratoderma and is characterized by granular and vacuolar degeneration of the cells of the spinous and granular layer. All mutations reported to date, with one exception, are located in the keratin 9 gene (*KRT9*) on chromosome 17(1, 3). The majority of *KRT9* mutations reported are missense mutations in exon 1 of the *KRT9* gene, but there are reports of a stop codon mutation in exon 1 (4) and of a 3 base pair insertion in exon 6 (5). The position most frequently reported to be mutated in *KRT9* is the arginine codon at position 162 in exon 1. In addition to *KRT9* mutations, there is a recent study revealing a splice site mutation in the *KRT1* gene as the cause of mild EPPK (6).

The *KRT9* gene appears to be the only keratin gene whose expression is restricted to palmoplantar epidermis (7, 8). Consequently, individuals that carry a mutation in the keratin 9 gene only display the effect of the mutation in the palmoplantar skin.

Here we report the first observation of a Swedish family with EPPK and the attribution of the disorder to a *de novo* mutation in *KRT9*.

### MATERIALS AND METHODS

Blood and biopsy samples were taken from the subjects after informed consent had been obtained. A punch biopsy from one of the affected individuals in the EPPK family was obtained from the proximal-ulnar aspect of the palm. The specimen was fixed in 4% formaldehyde, dehydrated and embedded in paraffin, sectioned and stained according to the method of van Gieson.

Genomic DNA was extracted from peripheral blood by standard techniques and microsatellite analysis performed according to standard procedures. The *KRT9* gene was studied by PCR amplification of a 394 base-pair fragment containing most of exon 1. PCR products were purified and either cloned into pGEM<sup>®</sup>-T Easy vector (Promega) and the resulting clones sequenced with SP6 and T7 primers, or sequenced directly with an internal keratin 9 primer.

### RESULTS

Two affected persons from the same family were diagnosed with EPPK based on clinical appearance and histologic evidence of epidermolytic hyperkeratosis in a biopsy from the proband S2 (Fig. 1). The affected

individuals showed sharply demarcated diffuse palmoplantar hyperkeratosis surrounded by a narrow erythematous border.

The family members were genotyped with DNA markers from the vicinity of the keratin 9 gene and haplotypes were constructed (Fig. 2). The proband, S2, and her affected father, SA16, carried the same haplotype that was not present in the proband's unaffected siblings, SA18 and SA19. The disease-associated haplotype was also present in the proband's paternal aunt, SA20, even though this woman was not affected by EPPK.

A PCR fragment covering most of exon 1 of *KRT9* from individual SA16 was cloned and sequenced. Three of the five clones sequenced were found to contain the wild-type sequence and two of the clones contained a missense CAG mutation in the CGG arginine codon at position 162. Direct sequencing of PCR fragments prepared from all individuals in the family confirmed that all healthy individuals were homozygous CGG in codon 162, whereas the two affected individuals were heterozygous CAG/CGG (Fig. 3).

### DISCUSSION

Diffuse palmoplantar keratoderma (PPK) is the most common genodermatosis in northern Sweden, but to date only non-epidermolytic PPK has been described (9). However, during our studies of families with PPK type Bothnia we encountered a patient who did not adhere to the type Bothnia phenotype. The hyperkeratosis in this patient was more severe than in typical PPK type Bothnia and also surrounded by a distinct narrow erythematous border. Thus, the clinical appearance of the patient was intermediate of PPK type Bothnia and the rare recessive variant of PPK present

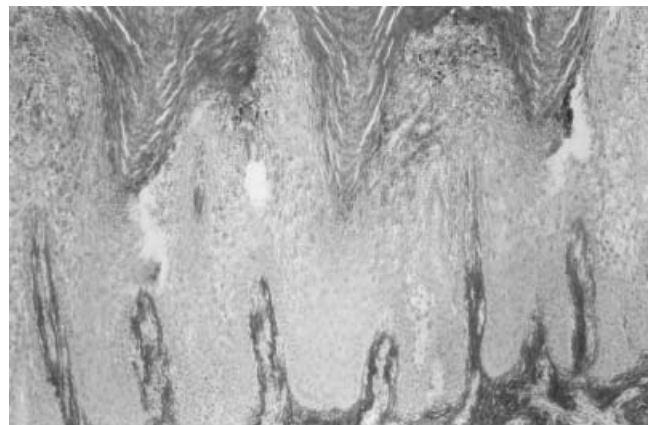


Fig. 1. Histopathology in the proband S2 shows epidermolytic hyperkeratosis with vacuolization and indistinct cellular boundaries in the upper stratum spinosum and in the stratum granulosum ( $\times 116$ ).

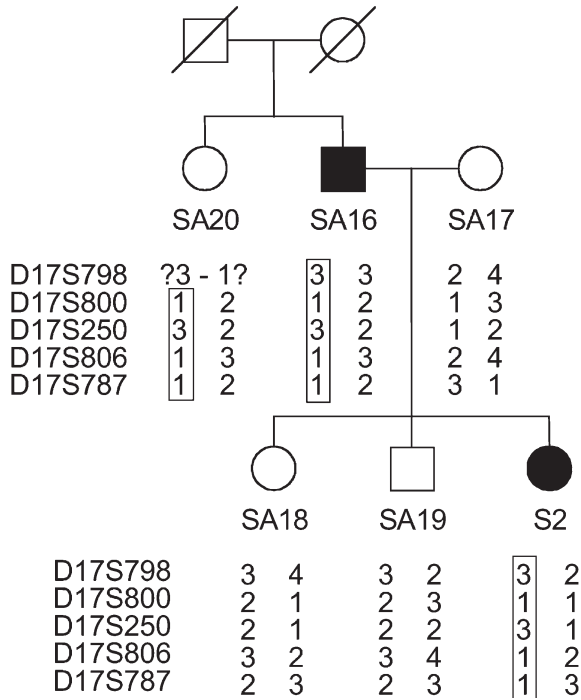


Fig. 2. Pedigree and haplotypes of the Swedish EPPK family. The DNA markers are listed in chromosomal order with D17S798 most proximal and D17S787 most distal. The keratin 9 gene is located between the markers D17S800 and D17S806. Disease-associated haplotypes are boxed. The phase of the D17S798 alleles in individual SA20 could not be determined. Affected individuals are represented by black symbols and non-affected family members by open symbols; deceased individuals are indicated by a slash across the symbols.

in northern Sweden (10). Additional members of the patient's family were contacted and it was discovered that only the proband and her father exhibited the PPK phenotype and there was no additional family history of PPK. When family haplotypes were constructed for markers in the PPK type Bothnia chromosomal region it was found that the PPK in this family was not linked to the chromosome 12q region (data not shown). However, haplotypes constructed for DNA markers from the keratin gene cluster region on chromosome 17 were in agreement with the inheritance of a disease gene from the father to the affected daughter but not to her unaffected siblings. Histopathological examination of a palmar skin biopsy from the proband revealed epidermolytic hyperkeratosis confirming the diagnosis of EPPK.

Because most cases of EPPK result from mutations in KRT9, we cloned the most frequently mutated region of the gene from one of our patients and sequenced the resulting clones to find that approximately half of the clones contained the normal sequence for the arginine codon (CGG) in position 162 and half of the clones contained a mutated glutamine codon (CAG) in the same position. Upon direct sequencing of PCR fragments from all family members it was concluded that the two affected individuals S2 and SA16 were heterozygous for the R162Q mutation, whereas their healthy relatives were homozygous for the normal arginine codon in that position. Individual

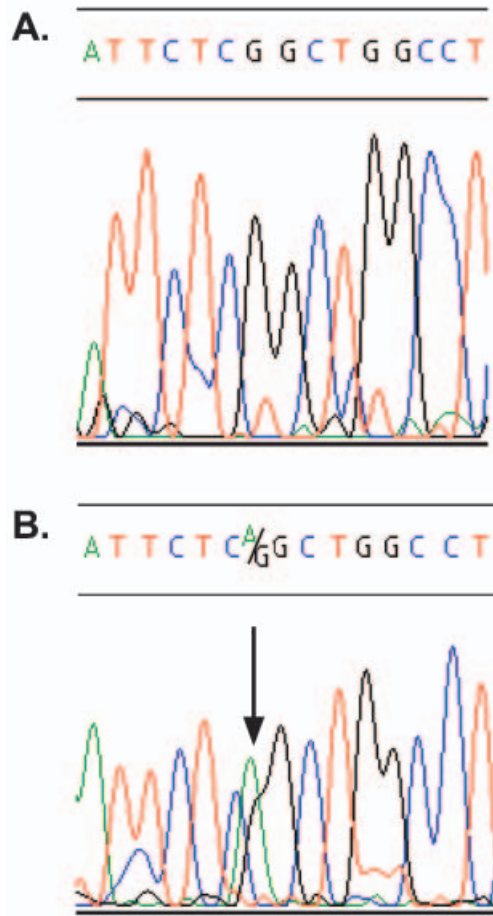


Fig. 3. DNA sequence from the KRT9 gene. A. Unaffected individual, SA18. B. Affected individual, S2. A heterozygous missense mutation in exon 1 of KRT9 changes a G to an A and causes the R162G mutation (indicated by an arrow).

SA20 was found to be homozygous for the normal codon in position 162 of KRT9 although she carried the microsatellite haplotype that was found linked to EPPK in her affected brother, SA16, and niece, S2. This apparent uncoupling of haplotype and KRT9 mutation in addition to the account of no signs of hyperkeratosis in the paternal grandparents of the proband led us to conclude that the EPPK in this family results from a *de novo* mutation in individual SA16. The R162 position of the KRT9 gene is the codon most frequently reported to be mutated in different families with EPPK and appears to be a favourable target for keratin 9 mutations.

In conclusion, we have found a mutation that causes an arginine to glutamine (R162Q) substitution in the sequence encoding the highly conserved 1A rod domain of KRT9 in two patients with EPPK.

ACKNOWLEDGEMENTS

We thank the family for their participation in this study. The work was supported by grants from the Swedish Medical Research Foundation (K98-19X-11623-03AK), the Medical Faculty of Umeå University, the Magn as Bergvall Foundation and the Welander Finsen Foundation.

## REFERENCES

1. Irvine AD, McLean WH. Human keratin diseases: the increasing spectrum of disease and subtlety of the phenotype-genotype correlation. *Br J Dermatol* 1999; 140: 815–828.
2. Kelsell DP, Stevens HP. The palmoplantar keratodermas: much more than palms and soles. *Mol Med Today* 1999; 5: 107–113.
3. Krawczak M, Cooper DN. The human gene mutation database. *Trends Genet* 1997; 13: 121–122. <http://www.hgmd.org>.
4. Szalai S, et al. Keratin 9 mutations in the coil 1A region in epidermolytic palmoplantar keratoderma. *Pediatr Dermatol* 1999; 16: 430–435.
5. Coleman CM, et al. Epidermolytic palmoplantar keratoderma due to a novel type of keratin mutation, a 3-bp insertion in the keratin 9 helix termination motif.
6. Hatsell SJ, et al. Novel splice site mutation in keratin 1 underlies mild epidermolytic palmoplantar keratoderma in three kindreds. *J Invest Dermatol* 2001; 116: 606–609.
7. Langbein L, et al. Molecular characterization of the body site-specific human epidermal cytokeratin 9: cDNA cloning, amino acid sequence, and tissue specificity of gene expression. *Differentiation* 1993; 55: 55–71.
8. Yamaguchi Y, et al. Regulation of keratin 9 in non-palmoplantar keratinocytes by palmoplantar fibroblasts through epithelial-mesenchymal interactions. *J Invest Dermatol* 1999; 112: 483–488.
9. Gamborg Nielsen P, Hofer PÅ, Lagerholm B. The dominant form of hereditary palmoplantar keratoderma in the northernmost county of Sweden (Norrbotten). *Dermatology* 1994; 188: 188–193.
10. Gamborg Nielsen P. Two different clinical and genetic forms of hereditary palmoplantar keratoderma in the northernmost county of Sweden. *Clin Genet* 1985; 28: