

## INVESTIGATIVE REPORT

**Expression of p53 in Normal Sun-exposed and Protected Skin (Type IV–V) in Different Decades of Age**MOETAZ BELLAH EL-DOMYATI<sup>1</sup>, SAMEH ATTIA<sup>1</sup>, FATMA SALEH<sup>1</sup>, NOREEN GALARIA<sup>2</sup>, HESHAM AHMAD<sup>1,2</sup>, FRANCES P. GASPARRO<sup>2</sup> and JOUNI UITTO<sup>2</sup><sup>1</sup>Department of Dermatology, Faculty of Medicine, Al-Minya University, Egypt, <sup>2</sup>Department of Dermatology and Cutaneous Biology, Jefferson Medical College and Jefferson Institute of Molecular Medicine, Thomas Jefferson University, Philadelphia, Pennsylvania, USA

The checkpoint protein p53, which is activated by DNA damage, is involved in the decision whether the cells should stop replication and proceed to repair their DNA or die by apoptosis. We evaluate the expression of p53 and the number of apoptotic cells in normal sun-exposed (face) and protected (abdomen) skin in Egyptians between 6 and 77 years of age. The degree of p53 expression in facial skin significantly increases from a score of  $1.5 \pm 1.5$  (mean  $\pm$  SEM) in the 1st decade to  $4.8 \pm 0.3$  in the 8th decade ( $p = 0.02$ ), while no significant changes are detected in the protected skin ( $p = 0.1$ ). Overall, the level of expression is significantly higher in sun-exposed facial skin than in abdominal skin ( $p = 0.007$ ). However, p53 expression versus age is significantly higher in the facial skin of older age groups in both males ( $p = 0.003$ ) and females ( $p = 0.02$ ). The pattern of staining was found to be dispersed (wild-type) in the majority (97.3%) of biopsies from sun-exposed skin and in all biopsies from non-exposed skin. The expression of wild-type p53 in type IV–V skin therefore correlates with both site and age of the individual. In contrast, the number of apoptotic cells significantly decreases with advancing age in sun-exposed skin ( $p = 0.005$ ). Increased age-associated expression of p53 in sun-exposed skin, but not in protected areas of skin, is found to reflect an accumulation of the wild-type protein, as judged by the staining pattern. The decrease in apoptotic cells with age may suggest the accumulation of senescent cells in the skin and their relative resistance to apoptosis. Such alteration in the proliferation/apoptosis balance could play a role in tumorigenesis.

(Accepted November 5, 2002.)

Acta Derm Venereol 2003; 83: 98–104.

Jouni Uitto, Department of Dermatology and Cutaneous Biology, Thomas Jefferson University, 233 South 10th Street, Suite 450, Philadelphia, PA 19107, USA. E-mail: Jouni.Uitto@mail.tju.edu

Human cells are constantly under assault from a variety of sources. These include the reactive oxygen species (ROS) produced in the mitochondria during oxidative phosphorylation and exposure to radiation and environmental

mutagens, which can damage both nuclear and mitochondrial DNA. Although the cells contain robust systems that both neutralize ROS and repair DNA, cell replacement may be a preferred alternative to DNA repair, particularly when damage is extensive. Replacement requires that the damaged cells die and are replaced by division of nearby functional cells ultimately derived from the stem cell pool (1). Thus, an important cellular process that may play a critical role in cutaneous aging is cell death, which can be separated into two distinct forms: (a) necrotic death and (b) programmed death or apoptosis (2, 3). Necrosis results from massive cell injury and is often accompanied by inflammation, while apoptosis is a programmed suicide that occurs in response to either external or internal stimuli. Apoptosis plays an important role in the elimination of unwanted cells during development, and also as a balancing factor in maintaining proliferative homeostasis (4–7).

p53 is a nuclear phosphoprotein that serves as a tumour suppressor. In its natural form (wild-type), p53 can bind to DNA and prevent cells from entering the S (synthetic) phase of the cell cycle, thus allowing time for DNA repair. Alternatively, p53-dependent events can eliminate the cells by sending them down an irreversible apoptotic pathway (8). Thus p53 allows the DNA either to be repaired or ultimately destroyed before replication events render the damage permanent. In the absence of wild-type p53, the genome becomes unstable (9), and mutations in this gene are present in up to 45% of human cancers. Indeed, the p53 mutation is the most frequent genetic, cancer-associated event demonstrated to date (10).

UV radiation damages DNA molecules (11) and the response of the skin is p53-dependent (9). Both physiological overexpression and mutation of p53 can cause the protein to accumulate in the cell, where it is detectable by routine immunohistochemistry (12). However, the staining patterns are different. In the case of the accumulation of wild-type p53 the pattern is diffused, while in the mutated p53 it is compact and localized (12, 13).

In the present study, we evaluate by immunohistochemistry the expression of p53 in normal sun-exposed and protected skin in individuals representing different

Table I. Characteristics of compact and dispersed patterns of p53 immunoreactivity\*

	Compact pattern	Dispersed pattern
Definition	An uninterrupted row of at least 10 strongly and uniformly immunopositive basally located nuclei	Immunopositive cells are randomly dispersed through the epidermis and/or hair follicle epithelium: there are negative nuclei dispersed among the positive cells
Lateral borders	Distinct	Absent
Variability	No internuclear variation	Significant internuclear variation

\*According to Ren et al. (13). Note: A dispersed pattern could also be considered even if there is a row of 10 consecutive positively stained nuclei if the positivity is not confined to a sharply demarcated area and when the hair follicles also have positive cells (i.e. not bypassed) (13).

decades of age. The number of apoptotic cells that reflect the response of the skin to various apoptotic stimuli is also evaluated in the same samples.

## MATERIALS AND METHODS

The present study was conducted on 36 patients (18 males and 18 females; age range 6–77 years; mean and SD  $40.7 \pm 21.4$ ) attending the dermatology outpatient clinic at the Al-Minya University Hospital, Al-Minya, Egypt. The patients were undergoing cosmetic and/or dermatosurgical procedures. Biopsy specimens were taken after informed consent had been obtained from the patients and/or their guardians. The study was approved by the Committee for Postgraduate Studies and Research of Al-Minya University. The subjects were divided into different age groups by decades. Punch biopsies, 2 or 3 mm, were taken from the face, “sun-exposed area”, and from the abdomen, “sun-protected area”, of each subject. Skin biopsies were fixed in formalin (10%), embedded in paraffin and sectioned into 5- $\mu$ m sections. These sections were used for routine histopathology (H&E) as well as for immunohistochemical staining.

### Immunohistochemical staining

The following protocol was used for immunohistochemical staining of p53: after overnight incubation at 37°C, tissue sections were deparaffinized in xylene and rehydrated in ascending grades of alcohol. Endogenous peroxidase activity was exhausted by incubation of tissue sections in 0.3% H<sub>2</sub>O<sub>2</sub> for 30 min at room temperature. Tissue sections were then treated with DAKO retrieval solution (DAKO® cat. no. S1699). Twenty percent rabbit serum in Tris-buffered saline was used for blocking. The monoclonal antibody DO-7 (DAKO #M7001) in 1:200 dilution in 2% rabbit serum was used to stain p53. This antibody reacts with both the wild-type and the mutant-type of human p53. It was incubated with the samples overnight. Biotinylated rabbit anti-mouse IgG (DAKO cat. no. E0354) was used as a secondary antibody. All tissue sections were stained under similar conditions to ensure equal staining quality. Squamous cell carcinoma tissue was used as a positive control; the primary antibody was not added in the negative control samples.

### Scoring of p53 immunoreactivity

The level of p53 expression was evaluated in accordance with the scoring system devised by Liang et al. (9). This system evaluates the degree of positivity and intensity of staining only in specimens demonstrating a dispersed pattern, i.e. the “wild-type” of p53 expression. The system results in a score ranging from 0 to 3 for both degree of positivity (% of positively stained nuclei of epidermal cells. 0: <1%, 1: 1–10%, 2: 10–50%, 3: >50%) and degree of intensity of staining

(the relative intensity of colour of the positively stained nuclei from faint-brown for score 1 to deep-brown for score 3). The sum of the two scores is taken as representative of the level of p53 expression. The pattern of expression, whether compact or dispersed, was determined according to the system reported by Ren et al. (13) (Table I).

### Quantitative evaluation of apoptotic cells

The relative quantity of apoptotic cells in various tissue sections was determined by counting the number of such cells corresponding to a total linear epidermal length of 2000  $\mu$ m and expressed as a number per mm. An ocular micrometer was used to measure the epidermal length on the standard H&E stained sections. The apoptotic cells are recognized by their morphological criteria, as previously described by Young (14), i.e. cells with pyknotic, deeply basophilic nuclei and with dense, darkly stained eosinophilic cytoplasm, so-called “dark cells” (Fig. 1).

### Statistical analysis

The significance of the differences, age versus score of p53 and apoptosis, and men versus women, was determined using the

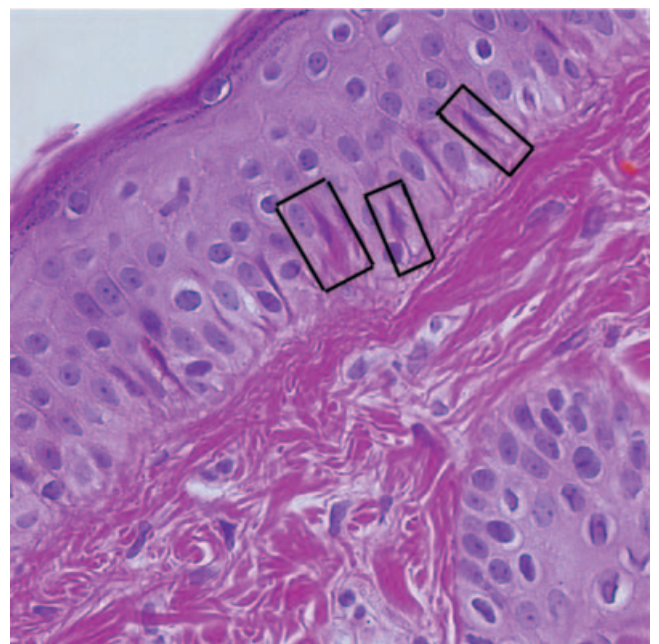


Fig. 1. Identification of apoptotic cells in the epidermis of facial skin from a 20-year-old female. Note the presence of apoptotic cells with characteristic morphology, i.e. cells with pyknotic, deeply basophilic nucleus, and dense, darkly stained eosinophilic cytoplasm (three examples boxed). (H&E stain; original magnification,  $\times 40$ ).

“linear regression test” and presented in scatter plots using the statistical package Graph Pad Prism, version 3.02 (Graph Pad Software Inc., San Diego, CA, USA). Student’s two-tailed *t*-test was performed to identify the difference in mean values. Summary data are expressed as mean  $\pm$  standard error of the mean (SEM). All *p* values are considered significant when less than or equal to 0.05.

## RESULTS

Immunohistochemical staining for p53 in the epidermis of facial skin revealed a dispersed pattern of staining in the majority of cases (97.3%) (Figs 2 and 3) and a compact staining pattern in only one case (2.7%). The degree of p53 expression in facial skin gradually increases from a mean score of  $1.5 \pm 1.5$  in the 1st decade to  $4.8 \pm 0.3$  in the 8th decade ( $p=0.02$ ) (Table II). This increase in p53 expression in facial skin versus age is highly significant in all cases ( $p=0.0001$ ) by the linear regression test. Such an increase is also statistically

significant when tested separately in males ( $p=0.003$ ) and females ( $p=0.02$ ) (Fig. 4). Insignificant changes can be detected in the degree of p53 expression in sun-protected abdominal skin in males ( $p=0.9$ ), females ( $p=0.6$ ) or all cases combined ( $p=0.87$ ) in different age groups (Fig. 4). The expression is always of the dispersed pattern in non-sun-exposed skin. The difference between p53 expression in facial and abdominal skin is statistically significant ( $p=0.007$ ) (Table II; Figs 2–4).

As age increases, positive staining for p53 is observed to extend progressively deeper into the epidermal appendages (Fig. 3). Specifically, while in the early decades positive p53 staining is limited to the epidermis, in older individuals more p53 expression is observed within the hair follicles, sebaceous glands and eccrine sweat glands. In fact, by the 8th decade the entire depth of the hair follicle is involved (Fig. 3).

The number of apoptotic cells in sun-exposed skin

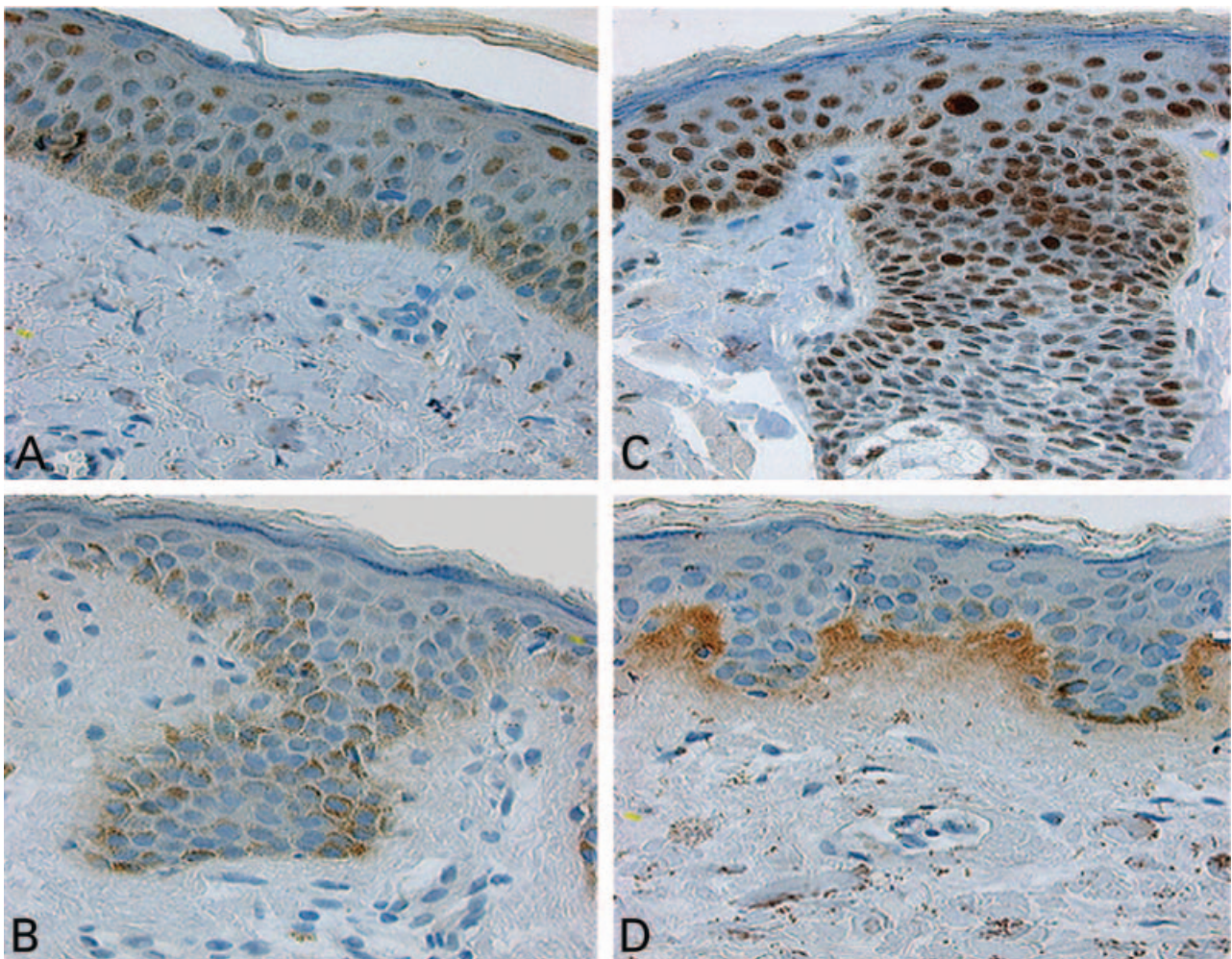


Fig. 2. Expression of p53, as detected by immunohistochemistry, in the facial skin (A, C) and the abdominal skin (B, D) of a 20-year-old female (A, B) and a 77-year-old male (C, D). Note the marked increase in intensity of the nuclear staining in the facial skin of the 77-year-old (C) compared to the 20-year-old individual (A). Also, the intensity of p53 expression in the facial skin is significantly higher than in the abdominal skin from the same individual (C versus D). (Original magnifications,  $\times 40$ ).

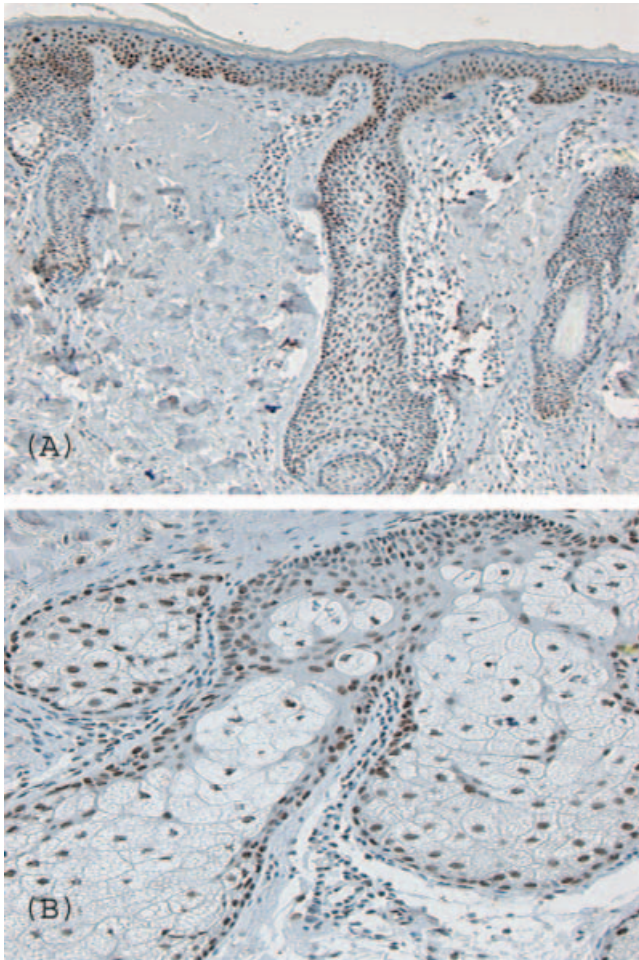


Fig. 3. Extension of p53 staining in the facial skin of the 77-year-old man to the skin appendages (hair follicle in A and the sebaceous gland in B). (Immunoperoxidase; original magnifications:  $\times 10$  in A,  $\times 20$  in B).

Table II. p53 expression in facial and abdominal skin in different decades

Decade*	No. of cases	Facial skin		Abdominal skin	
		Score	SEM	Score	SEM
1st	2	1.5	1.5	1.0	1.0
2nd	4	1.5	1.0	0.4	0.4
3rd	7	1.8	0.8	0.4	0.3
4th	6	2.3	0.7	0.8	0.5
5th	5	1.5	0.6	0.7	0.5
6th	1	4.0	0.0	0.0	0.0
7th	6	4.3	0.3	1.4	0.6
8th	5	4.8	0.3	0.0	0.0

\*Statistical significance of the differences:  $p=0.007$ , facial versus abdominal skin;  $p=0.02$ , 1st versus 8th decade in facial skin;  $p=0.1$ , 1st versus 8th decade in abdominal skin. SEM=Standard error of the mean.

gradually decreases from a mean of  $5.4 \pm 1.11$  in the 1st decade to  $1.0 \pm 0.4$  cells/mm in the 8th decade ( $p=0.005$ ) (Table III). However, such a decrease in the number of apoptotic cells versus age is statistically significant only

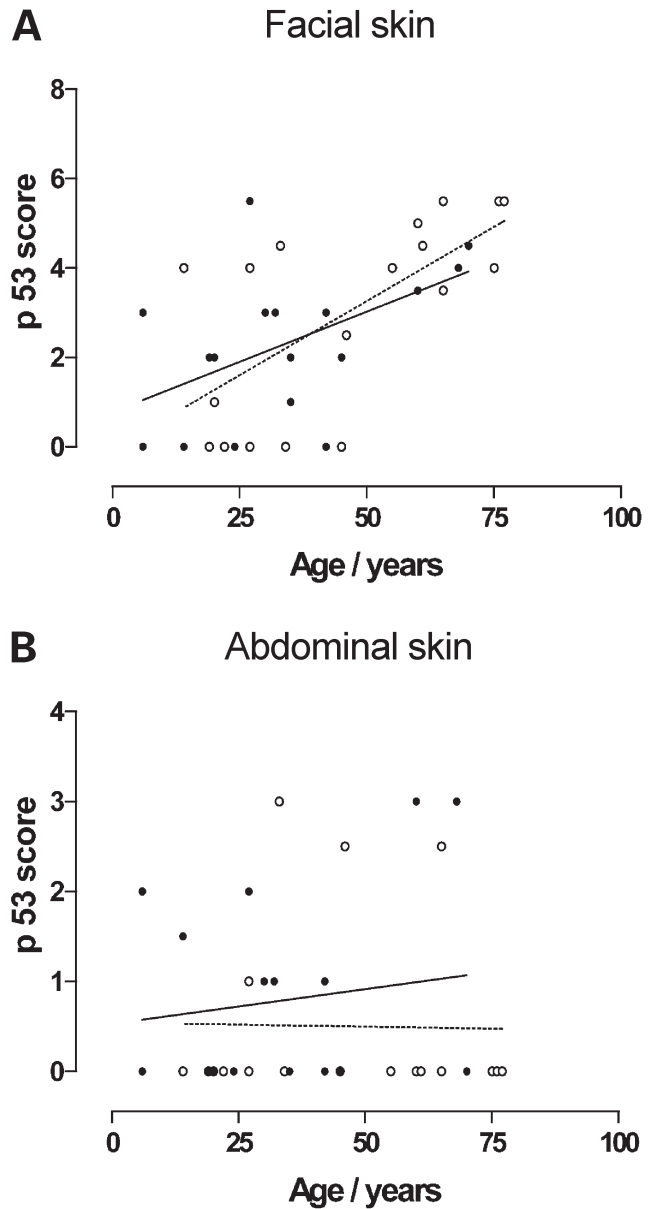


Fig. 4. p53 expression versus age in facial (A) and abdominal (B) skin of males ( $\circ$ , broken line) and females ( $\bullet$ , unbroken line). Facial skin: Males: Slope= $0.07 \pm 0.02$ ,  $r^2=0.4$ ,  $p=0.003$ . Females: Slope= $0.05 \pm 0.02$ ,  $r^2=0.3$ ,  $p=0.02$ . Abdominal skin: Males: Slope= $-0.0009 \pm 0.01$ ,  $r^2=0.0003$ ,  $p=0.9$ . Females: Slope= $0.008 \pm 0.01$ ,  $r^2=0.02$ ,  $p=0.6$ . For all cases: Facial skin: Slope= $0.06 \pm 0.01$ ,  $r^2=0.38$ ,  $p=0.0001$ . Abdominal skin: Slope= $0.001 \pm 0.01$ ,  $r^2=0.001$ ,  $p=0.87$ .

in females ( $p=0.03$ ), i.e. not in males ( $p=0.09$ ) (Fig. 5). There is no statistically significant difference in the number of apoptotic cells versus age in sun-protected abdominal skin in males ( $p=0.6$ ), females ( $p=0.3$ ) or combined ( $p=0.36$ ) (Fig. 5). Overall, the number of apoptotic cells is higher in facial skin than in abdominal skin ( $p=0.01$ ) (Table III; Fig. 5). However, the number of apoptotic cells is inversely proportional to the score of p53 in facial sun-exposed skin at early (1st and 2nd) and late (6th, 7th and 8th) decades (Fig. 6).

Table III. Number of apoptotic cells/millimeter linear length in facial and abdominal skin in different decades

Decade*	No. of cases	Facial skin		Abdominal skin	
		No. of cells	SEM	No. of cells	SEM
1st	2	5.4	1.1	2	0
2nd	4	3.8	1.4	1.7	0.5
3rd	7	2.3	0.8	1.7	0.9
4th	6	1.8	0.7	1.4	0.3
5th	5	2.2	0.3	1.1	0.3
6th	1	0	0	3	0
7th	6	0.9	0.1	1.1	0.4
8th	5	1.0	0.4	0.4	0.1

\*Statistical significance of the differences:  $p=0.005$ , 1st to the 8th decades in facial skin;  $p=0.0002$ , 1st to the 8th decades in abdominal skin;  $p=0.01$ , facial versus abdominal skin.

SEM=Standard error of the mean.

## DISCUSSION

The p53 gene located on the short arm of chromosome 17 acts as a tumour suppressor gene (15). The p53 protein product is a 393-amino acid phosphoprotein that localizes to the nucleus. There is increasing evidence that mutations of the p53 gene are among the most common genetic alterations in human malignancies (15); they have been implicated as important in the pathogenesis of ultraviolet light-induced skin cancer (16). It has been suggested that normal wild-type p53 has a relatively short half-life, and consequently its concentration in the cells is generally below the immunohistochemical detection level (17). However, it has been found that overexpression of the wild-type p53 as well as mutations in this protein cause the p53 to accumulate in the cell, where it becomes detectable by immunohistochemistry (12, 17).

In the present study, a gradual increase with age in the degree of p53 expression was observed in the facial skin in both males and females. This expression is significantly higher than it is in protected abdominal skin. However, such an increase in p53 expression is higher in males than in females, and this may be attributed to the higher degree of sun exposure as a result of the outdoor activity of males in the community, Al-Minya, Egypt, the venue of the study. It was found that the pattern of p53 staining in the skin reflects the type of protein present, whether wild-type or mutated (12, 13). Previous studies in which DNA sequence analysis was done have shown that the dispersed pattern of staining represents the wild-type p53, whereas the compact pattern reflects the presence of mutated p53 (12, 17). In the present study, the pattern of staining was found to be of the dispersed type in the majority of biopsies (97.3%) from sun-exposed skin and in all biopsies from the protected area of skin. The cells are randomly dispersed and not confined to the basal portion of the epidermis, with

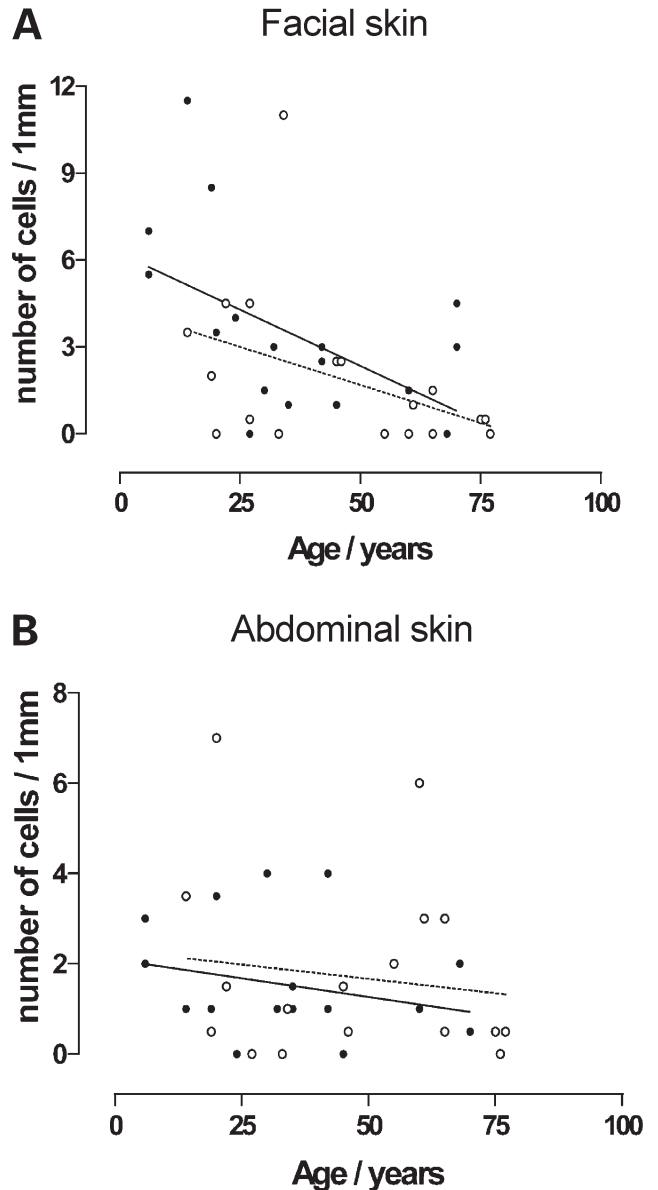


Fig. 5. Number of apoptotic cells versus age in facial (A) and abdominal (B) skin of males ( $\circ$ , broken line) and females ( $\bullet$ , unbroken line). Facial skin: Males: Slope =  $-0.05 \pm 0.03$ ,  $r^2=0.2$ ,  $p=0.09$ . Females: Slope =  $-0.08 \pm 0.03$ ,  $r^2=0.3$ ,  $p=0.03$ . Abdominal skin: Males: Slope =  $-0.01 \pm 0.02$ ,  $r^2=0.02$ ,  $p=0.6$ . Females: Slope =  $-0.02 \pm 0.02$ ,  $r^2=0.07$ ,  $p=0.3$ .

marked internuclear variation. In fact, negative nuclei are seen dispersed among the positive cells and there is no observed distinct lateral border. Also the hair follicles have positive cells (i.e. not bypassed) (13). This suggests that the pattern of staining (dispersed) observed in the present study reflects primarily the accumulation of the wild-type p53.

Irradiation of skin with a light source, emitting a broad band UVB, UVA and near infrared radiation, has been shown to result in p53 accumulation in a dispersed pattern, which peaks within 1 day and subsides within 15 days of irradiation. In addition, "background" p53

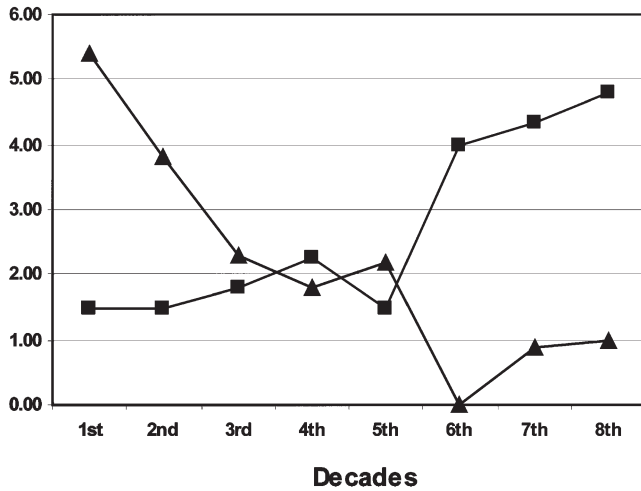


Fig. 6. Mean number of apoptotic cells/mm (▲) and score of p53 expression (■) in facial sun-exposed skin of different decades of age.

positivity in chronically sun-exposed skin has been reported (18). In the present study, many of the subjects have a substantial number of cells with dispersed p53 positivity, which could be due to a steady low level of exposure to UV leading to continuous p53 expression in these individuals. However, since p53 expression appears to increase with age, it is more likely that the positivity is not just a result of a reactive response to recent sun exposure but accumulation over the years (cumulative insult).

Age-dependent p53 accumulation in photo-damaged skin may be partially explained on the basis of altered differentiation of the damaged keratinocytes. It has been noted that the degree of nuclear expression of p53 is inversely correlated with the degree of keratinocyte differentiation (15). This kind of inverse relationship is equally true for normal compact epidermal pattern, dysplastic cells, and cancerous keratinocytes (15). Since photo-damaged keratinocytes seem to have lost, at least in part, their ability to differentiate normally (19), it is possible that accumulation of the wild-type p53 in photo-damaged skin is partially related to altered keratinocyte differentiation.

In addition to differentiation, signal transduction is altered in senescent cells (19). At the same time, the ability of the cells to repair damaged DNA is reduced with age (20). It is therefore plausible that persistent expression of wild-type p53 with age may be due to failure of the senescent epidermal cells to respond to the physiologically produced p53 in response to DNA damage, thus resulting in its continuous expression. At the same time, the senescent cells may fail to lower the expression of physiologically induced protein, thus resulting in its accumulation.

The compact pattern of staining, which reflects the presence of mutated p53, was observed in the facial skin of only one case (2.7%), which is much lower than the previously reported 34% (18). The lower incidence

observed in the present study could possibly be explained by the difference in skin type, which in the individuals included in the present study is Fitzpatrick type IV–V in all cases. The natural melanin pigment in skin type IV–V may offer protection against the UV irradiation-induced DNA damage, and hence lower incidence of UV induced p53 mutations. This interpretation agrees with reports of a lower risk of non-melanocytic skin cancers among dark skinned populations (21). However, since scattered p53-mutated keratinocytes have been reported in normal skin in a recent study (22), further mutation analysis of p53 could detect or exclude the possibility of scattered mutations, which may also explain the lower figure of compact pattern (2.7%) in our specimens compared to other studies (18).

In previous reports, dispersed pattern is positively correlated to site (sun-exposed), and not to the age of the subject (at least after the age of 40 years) (12, 18). Our results also show that the dispersed pattern is positively correlated to the site, face versus abdomen. However, contrary to previous reports, there is also a definitive correlation with increasing age.

As age increases, positive staining for p53 is observed to extend deeper into the skin appendageal structures, so that by the 8th decade the hair follicles as well as sebaceous and eccrine sweat glands are involved in a pattern similar to that of the epidermis in earlier decades. To the best of our knowledge, no previous report has recorded such progression.

In the present study, we have demonstrated that the number of apoptotic keratinocytes/mm linear length of sun-exposed epidermis is significantly decreased with advancing age. Since DNA repair capacity decreases with age (20), it could be expected that the damaged cells prefer to go into apoptosis before cell replication makes DNA damage permanent. To the contrary, our results demonstrate a progressive decrease in the number of apoptotic cells despite the concomitant high level of p53 expression. Resistance of the senescent cells to apoptotic signals induced by p53 may again explain this paradox. Such a view of apoptotic resistance is supported by previous observations (23) suggesting that senescent cells are inherently resistant to apoptosis. Senescent cells may also contribute to increased cancer incidence with age (24). Moreover, the expansion of malignant cells can occur if programmed cell death (apoptosis) is inhibited (25). In this context, the present study is considered as a pilot study, and future studies implying more specific techniques for detection of apoptotic cells, such as TUNEL stain, are required to confirm the latter.

In conclusion, the expression of wild-type p53 in type IV–V skin correlates with both site (sun-exposed) and age (increased age), while the decrease in number of apoptotic cells with age may suggest the accumulation

of senescent cells in the human skin and their relative resistance to apoptosis. This alteration in the proliferation/apoptosis balance could play an active role in tumorigenesis. Mutation analysis of p53 would potentially confirm our findings.

#### ACKNOWLEDGEMENTS

We thank Carol Kelly for her help in preparation of this manuscript. Dr. George Murphy provided guidance in interpretation of histopathology. Dr. Adam Peritz and Mark Pawlowski assisted in immunohistochemistry and Dr. Tarek M. El-Mansoury helped in statistical analysis. This study is submitted in partial fulfilment of the Doctoral Degree by Dr. Ahmad at Al-Minya University and is supported by the Egyptian Cultural and Educational Bureau.

#### REFERENCES

1. Levine AJ. p53, the cellular gatekeeper for growth and division. *Cell* 1997; 88: 323–331.
2. Kerr JFR, Wyllie AH, Currie AR. Apoptosis: a basic biological phenomenon with wide-ranging implications in tissue kinetics. *Br J Cancer* 1972; 26: 239–257.
3. Columbano A. Cell death: current difficulties in discriminating apoptosis from necrosis in the context of pathological processes in vivo. *J Cell Biochem* 1995; 58: 181–190.
4. Vaux DL, Cory S, Adams J. *bcl-2* gene promotes haemopoietic cell survival and cooperates with *c-myc* to immortalize pre-B cells. *Nature* 1988; 335: 440–442.
5. Williams GT. Programmed cell death: apoptosis and oncogenesis. *Cell* 1991; 65: 1097–1098.
6. Thompson CB. Apoptosis in the pathogenesis and treatment of disease. *Science* 1995; 267: 1456–1462.
7. Warner HR, Hodes RJ, Pocinki K. What does cell death have to do with aging? *J Am Geriatr Soc* 1997; 45: 1140–1146.
8. McNutt NS, Saenz-Santamaria C, Volkenandt M, Shea CR, Albino AP. Abnormalities of p53 expression in cutaneous disorders. *Arch Dermatol* 1994; 130: 225–232.
9. Liang S, Ohtsuki Y, Furihata M, Takeuchi T, Iwata J, Chen B, et al. Sun-exposure and aging dependent p53 protein accumulation results in growth advantage for tumor cells in carcinogenesis of nonmelanocytic skin cancer. *Virchows Arch* 1999; 434: 193–199.
10. Soussi T. The p53 tumor suppressor gene: from molecular biology to clinical investigation. *Ann New York Acad Sci* 2000; 910: 121–139.
11. Burren R, Scaletta C, Frenk E, Panizzon RG, Applegate LA. Sunlight and carcinogenesis: expression of p53 and pyrimidine dimers in human skin following UVA I, UVA I+II and solar simulating radiations. *Int J Cancer* 1998; 76: 201–206.
12. Jonason AS, Kunala S, Price GJ, Restifo RJ, Spinelli HM, Persing JA, et al. Frequent clones of p53 mutated keratinocytes in normal human skin. *Proc Natl Acad Sci* 1996; 93: 14025–14029.
13. Ren Z, Ponten F, Nister M, Ponten J. Two distinct p53 immunohistochemical patterns in human squamous-cell skin cancer, precursors and normal epidermis. *Int J Cancer* 1996; 69: 174–179.
14. Young AR. The sunburn cells. *Photo-Dermatol* 1987; 4: 127–134.
15. Fung CY, Fisher DE. p53: from molecular mechanisms to prognosis in cancer. *J Clin Oncol* 1995; 13: 808–811.
16. Li G, Tron V, Ho V. Induction of squamous cell carcinoma in p53-deficient mice after ultraviolet irradiation. *J Invest Dermatol* 1998; 110: 72–75.
17. Shimizu T, Muto M, Murakami T, Furumoto H, Mogami S, Asagami C. Overexpression of p53 protein associated with proliferative activity as evaluated by Ki-67 immunostaining in well-differentiated squamous cell carcinoma of the skin. *Dermatology* 1997; 195: 224–227.
18. Ponten F, Berne B, Ren ZP, Nister M, Ponten J. Ultraviolet light induces expression of p53 and p21 in human skin: effect of sunscreen and constitutive p21 expression in skin appendages. *J Invest Dermatol* 1995; 105: 402–406.
19. Yaar M, Gilchrist B. Aging versus photoaging: postulated mechanisms and effectors. *J Invest Dermatol Symp Proc* 1998; 3: 47–51.
20. Moriwaki S, Ray S, Tarone RE, Kraemer KH, Grossman L. The effect of donor age on the processing of UV damaged DNA by cultured human cells: reduced DNA repair capacity and increased DNA mutability. *Mutat Res* 1996; 364: 117–123.
21. Gallagher RP, Hill GB, Bajdik CD, et al. Sunlight exposure, pigmentary factors, and risk of nonmelanocytic skin cancer. I. Basal cell carcinoma, II. Squamous cell carcinoma. *Arch Dermatol* 1995; 131: 157–169.
22. Ling G, Persson A, Berne B, Uhlen M, Lundeberg J, Ponten F. Persistent p53 mutations in single cells from normal human skin. *Am J Pathol* 2001; 159: 1247–1253.
23. Wang E. Senescent human fibroblasts resist programmed cells death, and failure to suppress bcl2 is involved. *Cancer Res* 1995; 55: 2284–2292.
24. Campisi J. The role of cellular senescence in skin aging. *J Invest Dermatol Symp Proc* 1998; 3: 1–5.
25. Morales-Ducret CR, van de Rijn M, LeBrun DP, Smoller BR. *bcl-2* expression in primary malignancies of the skin. *Arch Dermatol* 1995; 131: 909–912.