

Periungual Keratoacanthoma Preceded by a Wart and Followed by a Verrucous Carcinoma at the Same Site

Robert Baran¹, Antonella Tosti² and David De Berker³

¹Nail Disease Centre, 42 Rue des Serbes, FR-06400 Cannes, France, ²Istituto Di Clinica Dermatologica, Dell'Universita di Bologna, Policlinico S. Orsola, Bologna, Italy and ³Bristol Royal Infirmary, Bristol, UK. E-mail: baran.r@club-internet.fr
Accepted January 7, 2003.

Sir,

Periungual keratoacanthoma can be difficult to diagnose clinically. Its presentation may differ markedly from that of keratoacanthoma found elsewhere on the skin. The same observation concerning presentation is made for squamous cell carcinoma (SCC) of the perionychium and skin. A further distinction from SCC at these sites is the presence of human papilloma virus (HPV) in periungual squamous cell carcinoma and its routine absence at most other sites. We report the presence of oncogenic HPV 31 and 35 in a periungual keratoacanthoma, marked by the manifestation of a wart prior to and a verrucous carcinoma after the presentation of the keratoacanthoma at the same site.

CASE REPORT

A 55-year-old woman presented with a keratotic lesion on the middle of the distal portion of the proximal nail fold (PNF) of her left thumb, of 3 month's duration. The cuticle was thickened and irregular. The region was not manifestly tender. As the diagnosis had not been clearly established, the lesion was excised using a V-shaped excision followed by re-approximation of the edges. Histology showed a wart involving the ventral aspect of the distal PNF.

Six years later, the patient sought advice for a swelling of the proximal nail fold of the same thumb, of 2–3 month's duration. On examination, a firm, tender tumour was visible on the distal two-thirds of the nail fold with a proximal, transverse, clearly defined edge (Fig. 1a). Keratoacanthoma (KA) was suspected and the neoplasm was removed by crescent-shaped excision of the PNF. The clinical diagnosis was confirmed histopathologically (Fig. 1b). Six months later, the patient presented with a papillomatous tumour involving two-thirds of the PNF associated with leuconychia (Fig. 2a). Clinically, this resembled a wart and it was treated with extensive curettage, but the histology of the specimen was that of a verrucous carcinoma (Fig. 2b).

Sections (10 µm) of the paraffin-embedded tissue block from the periungual warts and the keratoacanthoma were analysed for the presence of HPV-DNA sequences with PCR amplification. Amplification products were analysed by dot-blot hybridization with digoxigenin-labelled internal probes specific for the main oncogenic HPV types 6, 11, 16, 18, 31, 33 and 35. A positive result was

found for HPV types 31/35 in the keratoacanthoma sample, but not the preceding or subsequent wart.

DISCUSSION

Swelling of the PNF may be caused by underlying warts (1) and may sometimes present as tender periungual nodules (2). The role of HPV in the development of KAs

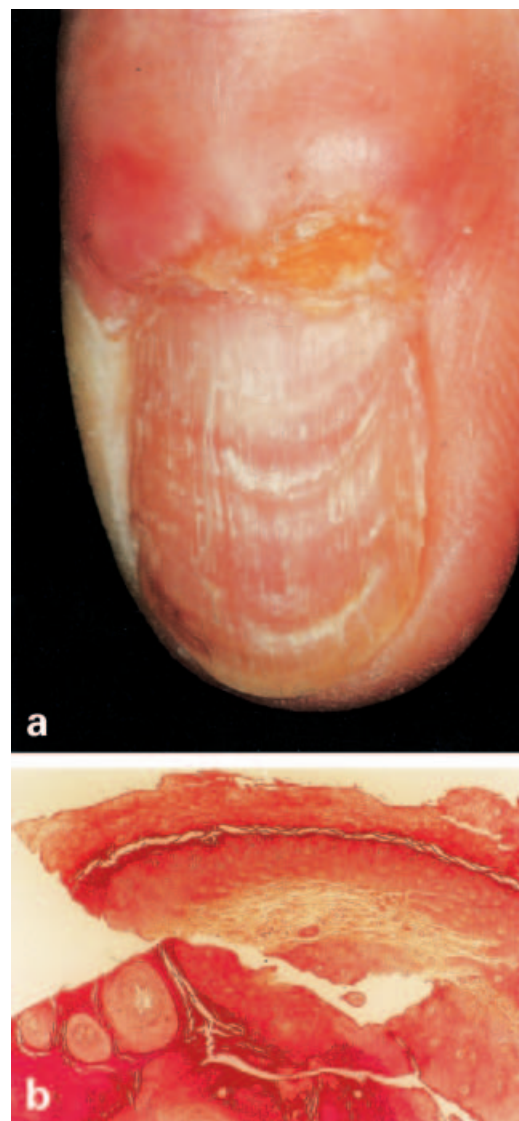


Fig. 1. Clinical presentation of the keratoacanthoma on the proximal nail fold (a). Invaginated lesion with cup-shaped architecture, well demarcated from surrounding tissue (b) ($\times 20$).

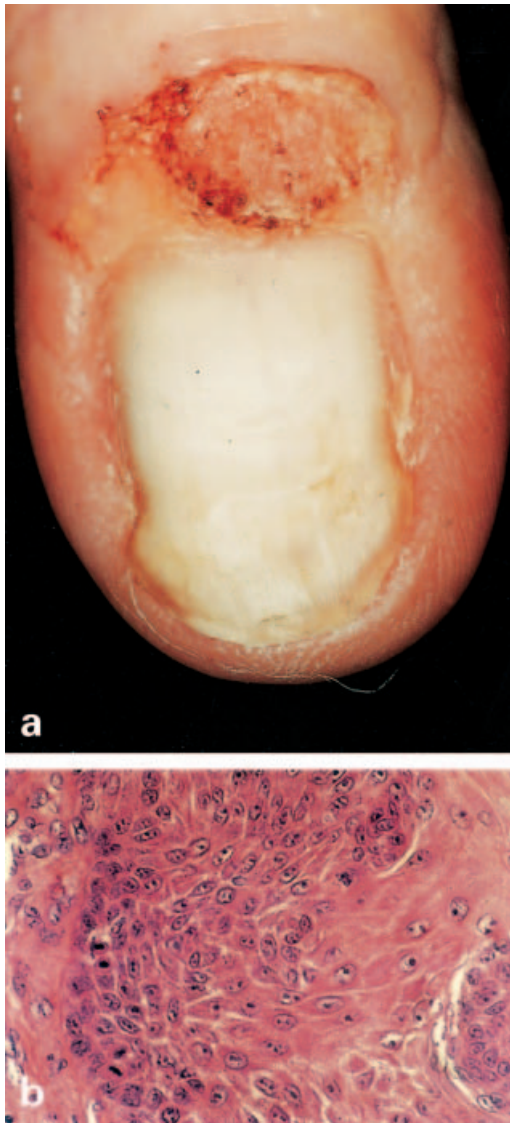


Fig. 2. Warty papillomatous-like lesion on the proximal nail fold, associated with leuconychia (a). Atypia and mitoses in the basal layer (b) (HES $\times 400$).

is still open to question. All of the literature is on KA at non-periungual sites. Lu et al. (3) assessed 80 non-periungual KAs for the presence of HPV by *in situ* hybridization, but with negative findings.

According to Stockfleth et al. (4), HPV is probably not generally associated with the aetiology of KA but may be relevant in individual cases. Hsi et al. (5) analysed DNA extracted from 39 KAs from 22 "at risk" patients and found the presence of HPV types 11, 13, 24, 33 and 57.

Boateng et al. (6) reported on a case of multiple KAs (Witten-Zak type) where HPV subtype 2 was identified in two tumours by *in situ* hybridization.

Our case is interesting because the nail KA harboured infection with HPVs, 31/35 of which are oncogenic. These HPVs were not identified from the nail fold wart that was excised from the same site where KA later developed, or in the verrucous carcinoma which appeared 6 months after

the KA had been removed. The presence of these HPVs was associated with a change in the clinical and histological features within the spectrum between viral wart and SCC. This same pattern is seen in periungual SCC, where the presence of oncogenic HPVs, typically 16, is associated with the dysplastic behaviour seen in "wart-like" lesions (7). However, HPV 35 has also been associated with periungual SCC (8). Making a further distinction between a periungual KA and a periungual SCC can be difficult. Their common ground is acknowledged and this case underlines that there may be common biological processes in their aetiology. Some authorities choose not to make the distinction for fear of missing an SCC that requires more aggressive therapy. However, where that distinction can be made with confidence, the patient could be afforded more limited treatment and a better prognosis.

This report is not conclusive, but raises the question of whether HPV plays a role in the aetiology of periungual KA in a manner analogous to the role of HPV in the aetiology of periungual SCC. Further study on a series of this rare tumour is warranted to address this issue.

ACKNOWLEDGEMENTS

We thank our histopathologists Dr Ch. Perrin (Nice) and Dr J. Varini (Cannes) and our virologist Professor M. Musiani (Bologna) for their help during this study.

REFERENCES

1. Lauchli S, Eichmann A, Baran R. Swelling of the proximal nail fold caused by underlying warts. *Dermatology* 2001; 202: 328–329.
2. Holland TT, Weber CB, James WD. Tender periungual nodules. *Arch Dermatol* 1992; 128: 105–110.
3. Lu S, Syrjanen SL, Havu VK, Syrjanen S. Known HPV types have no association with keratoacanthomas. *Arch Dermatol Res* 1996; 288: 129–132.
4. Stockfleth E, Meinke B, Arndt R, Christophers E, Meyer R. Identification of DNA sequences of both genital and cutaneous HPV types in a small number of keratoacanthomas of nonimmunosuppressed patients. *Dermatology* 1999; 198: 122–125.
5. Hsi ED, Svoboda-Newman SM, Stern RA, Nickoloff BJ, Frank TS. Detection of human papillomavirus DNA in keratoacanthomas by polymerase chain reaction. *Am J Dermatopathol* 1997; 19: 10–15.
6. Boateng B, Hornstein OP, von den Driesch P, Kiesewetter F. Multiple keratoacanthomas (Witten-Zak type) in prurigo simplex subacuta. *Hautarzt* 1995; 46: 114–117.
7. Ashinoff R, Li JJ, Jacobson M, Friedman-Kien AE, Geronemus RG. Detection of human papillomavirus DNA in squamous cell carcinoma of the nail bed and finger determined by polymerase chain reaction. *Arch Dermatol* 1991; 127: 1813–1818.
8. McHugh RW, Hazen P, Eliezri YD, Nuovo GJ. Metastatic periungual squamous cell carcinoma: detection of human papillomavirus type 35 RNA in the digital tumor and axillary lymph node metastases. *J Am Acad Dermatol* 1996; 34: 1080–1082.