

Severe Recalcitrant Necrotizing Leucocytoclastic Vasculitis in Non-Hodgkin's Lymphoma Associated with Hepatitis C: Successful Treatment with the Combination of Antiviral and Immunosuppressive Therapy

Wei Zou, Alexander Kreuter, Renate Schlottmann, Uta Bartke, Peter Altmeyer, Nan Ping Wu and Norbert H. Brockmeyer^{2*}
Institute of Infectious Diseases, the First Hospital of Zhe Jiang University, HangZhou, China and ²Clinic of Dermatology and Allergy, St. Josef-Hospital, Ruhr University, Gudrunstraße 56, D-44791, Bochum, Germany.

*E-mail: N.Brockmeyer@derma.de-Bochum

Accepted February 3, 2003.

Sir,

Leucocytoclastic vasculitis (LV) is a common disorder of small dermal vessels characterized by a polymorphonuclear infiltrate and 'nuclear dust' as well as fibrinoid change. The clinical presentation may be purely urticarial, purpuric or necrotic (1). The sexes are affected equally, the disorder occurs at all ages and some patients with LV have infections and malignant diseases. Here we report a severe recalcitrant necrotizing LV in a patient with non-Hodgkin's lymphoma and hepatitis C infection. The LV was successfully treated with a combination of antiviral and immunosuppressive therapy.

CASE REPORT

A 53-year-old woman with a 2-year history of recurrent palpable purpura and intermittent oedema on both lower limbs was admitted to our hospital because of aggravation over the course of 8 weeks. The patient had no other complaints. In July 1999 she had several blood transfusions due to cytopenia caused by chemotherapy (CHOP) given because of large cell non-Hodgkin's lymphoma (stage IVB). In June 2000, active hepatitis C infection was detected, but therapy was not started at this time. She also had palpable purpura, and oedema on both lower limbs emerged intermittently.

Laboratory tests investigated are as follows: blood: neutrophil and eosinophil counts: 8620/ μ l and 0/ μ l, respectively (normal: 1800–7200/ μ l, 0/ μ l), total white cell count: 10890/ μ l (normal: 4000–10000/ μ l), ESR: 149 mm/h; IgM rheumatoid factor: 348 U/ml (normal: 0–14 U/ml), CRP: 50.8 mg/l (normal: 0–5 mg/l), ANA: 1:10240, circulating immune complexes: 2.2 μ g/ml (normal: 0–1.5 μ g/ml), C4c: <11 mg/dl (normal: 20–50 mg/dl), C3c: 103 mg/dl (normal: 90–180 μ g/ml), cryoglobulins: not detected, IgA, IgE, IgG and IgM: normal; hepatic and renal function: normal; virology tests: HCV viral load in serum: 4 million/ml, HCV genotype: 1b, anti-HCV (+); detection of *Helicobacter pylori* by fast method and gastroscopy: negative.

Histological examination of a biopsy specimen taken from a representative purpuric skin lesion before therapy showed changes characteristic of leucocytoclastic vasculitis, i.e. fibrinoid necrosis of dermal venules, leucocytodiapedesis and leucocytoclasia. The direct immunofluorescence technique showed deposits

of complement (C3), but no immunoglobulins in the vessels of the papillary dermis.

She was treated orally with azathioprine 150 mg/day and prednisolone 60 mg/day for 12 weeks, with no improvement. Four weeks after the start of therapy, a painful ulcer 9.3 cm by 7.5 cm gradually developed (Fig. 1a). During the next 2 months, skin transplantation using full-thickness specimens was performed twice, without success. The therapeutic regimen was then revised: Azathioprine 150 mg/day, cyclosporine 100 mg/day and prednisolone 20 mg/day were combined with pegylated interferon 80 μ g/week subcutaneously and ribavirin 2 g/day orally. One week later, the ulcer stopped deteriorating. After 5 weeks the clinical appearance and the laboratory tests improved dramatically. The ulcer gradually healed. A third and successful skin transplantation was performed (Fig. 1b). After 16 months, when the patient was discharged, all laboratory tests were normal. Maintenance therapy was azathioprine 50 mg/day, cyclosporine 100 mg/day

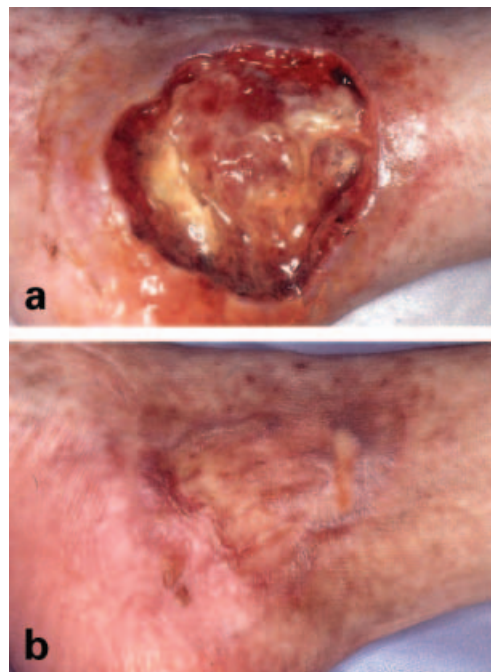


Fig. 1. (a) Appearance of the ulcer before therapy and (b) after combined antiviral and immunosuppressive therapy followed by skin transplantation.

and prednisolone 10 mg/day orally combined with pegylated interferon 80 µg/week subcutaneously. After discharge she was followed as an outpatient. The HCV viral load is now undetectable and the ulcer remains completely healed.

DISCUSSION

A number of cases of LV associated with hepatitis C infection have been reported (2–5). The pathogenesis is unknown. We consider two possible mechanisms that could explain the development of LV in our patient: one is that HCV-anti-HCV antibody immune complex in vessels activated complement and led to vasculitis, even though we did not detect immunoglobulins histopathologically. The other is related to anaplastic large cell non-Hodgkin's lymphoma although complete remission was achieved under chemotherapy for 3 years. We cannot exclude the possibility of this malignancy playing a part in the initiation of the vasculitis.

It is also important to understand the necessity of the combination of antiviral and immunosuppressive therapy in our patient with hepatitis C and LV. In the first 3 months of treatment, LV could not be controlled effectively by immunosuppressive therapy only. But after the addition of antiviral therapy, the condition improved dramatically. We therefore believe that the

deficiency of antiviral therapy played a pivotal role in the failure of the first two skin transplantations in our patient, and caused the HCV infection and the vasculitis to be constantly active. Thus, to some extent, effective prevention and early treatment of hepatitis C infection could possibly decrease the incidence of LV among these patients.

REFERENCES

1. Kobyletzki G, Stucker M, Hoffmann K, Pohlau D, Hoffmann V, Altmeyer P. Severe therapy-resistant necrotizing vasculitis associated with hepatitis C virus infection: successful treatment of the vasculitis with extracorporeal immunoadsorption. *Br J Dermatol* 2000; 138: 926–927.
2. Kapur N, Tympanidis P. Long-term follow-up of a patient with cutaneous vasculitis secondary to mixed cryoglobulinaemia and hepatitis C virus. *Clin Exp Dermatol* 2002; 27: 37–39.
3. Abe Y, Tanaka Y, Takenaka M, Yoshida H, Yatsuhashi H, Yano M. Leucocytoclastic vasculitis associated with mixed cryoglobulinaemia and hepatitis C virus infection. *Br J Dermatol* 1997; 136: 272–274.
4. Mehta S, Levey JM, Bonkovsky HL. Extrahepatic manifestations of infection with hepatitis C virus. *Clin Liver Dis* 2001; 5: 979–1008.
5. Gungor E, Cirit A, Alli N, Karakayali G, Gur G, Artuz F. Prevalence of hepatitis C virus antibodies and cryoglobulinemia in patients with leukocytoclastic vasculitis. *Dermatology* 1999; 198: 26–28.