

## LETTERS TO THE EDITOR

## Multinucleate Cell Angiohistiocytoma: A Report of Four Cases in Finland

Liisa Väkevä, Olli Saksela and Arja-Leena Kariniemi

Skin and Allergy Hospital, Helsinki University Central Hospital, Meilahdentie 2, FIN-00250 Helsinki, Finland. E-mail: lvakeva@helsinki.fi

Accepted January 21, 2003.

Sir,

Multinucleate cell angiohistiocytoma (MCAH) was first described in 1985 by Smith & Wilson-Jones (1). This condition is an unusual skin disorder most commonly affecting middle-aged women. Clinically, the lesions appear as painless multiple small erythematous papules usually located on the limbs, mainly on the dorsum of the hands, but also on the face, legs and chest. Typically, the slowly progressing MCAH papules reach the size of 2–15 mm and may become dome-shaped or flat (2–4). No constant associations with other cutaneous or systemic diseases have been reported. The differential diagnosis includes cutaneous vascular proliferations such as angiofibromas or Kaposi's sarcomas as well as sarcoidosis, lupus erythematosus, insect bite, lichen planus, lymphocytoma and granuloma annulare (5, 6).

We present four cases of MCAH diagnosed at the Helsinki University Central Hospital.

## CASE REPORTS

*Case 1.* A 46-year-old woman with urticaria had a 2-year history of skin lesions on the dorsal part of her fingers on both her hands. The lesions had been biopsied 2 years previously elsewhere, and the initial diagnosis was microvenular haemangioma or other benign vascular proliferation. Clinical examination revealed two erythematous firm papules on the dorsal aspect of her fingers (Fig. 1). The patient was worried because the lesions had grown during the past year and were itching.

*Case 2.* A 62-year-old woman presented with asymptomatic erythematous lesions on her hand. Eight years earlier she had been treated for angiomyolipoma of the kidney, and the hand lesions had appeared at that time. On clinical examination, violaceous papules were present on her fingers and on the

dorsum of her left hand. The biggest lesion measured 3 cm in diameter and was removed surgically. Histopathological examination showed MCAH (see below).

*Case 3.* A 62-year-old woman who had essential hypertension. She gave a one-year history of reddish purple papules on the dorsal aspect of her left hand. No previous local trauma or insect bite was revealed. The biopsy showed multinucleate cell angiohistiocytoma. She was treated with CO<sub>2</sub>-laser. After a follow-up period of 2.5 months the lesions remained cured.

*Case 4.* A 48-year-old man with a previous history of atopic dermatitis. A single erythematous papule had appeared on his chest, and during the next 6 months several similar lesions appeared. Clinically, the papules resembled lichen ruber planus. Histopathological examination showed an increased number of blood vessels in the dermis and a diagnosis of microvenous haemangioma was made. Later, however, the multinucleate cells between the vessels were noticed, and this led to the correct diagnosis of MCAH. The lesions were treated with CO<sub>2</sub>-laser. No relapse was detected within 5 months.

*Histopathological findings.* The biopsy specimens taken from the lesions of all four patients showed similar histological alterations. The epidermis was slightly hypertrophic and hyperkeratotic. The upper and middle parts of the dermis contained a dense network of capillaries and small venules with round lumina. A sparse fibrohistiocytic cell infiltration was seen around the vessels (Fig. 2). Some of these cells were multinucleate giant cells with angulated cytoplasm.

On immunohistochemistry, the endothelial cells were CD31- and CD34-positive. Both mononucleated and multinucleated mesenchymal cells were positive for vimentin. The mononuclear histiocytes were positive for CD68, but the multinucleate cells were negative for this macrophage marker.

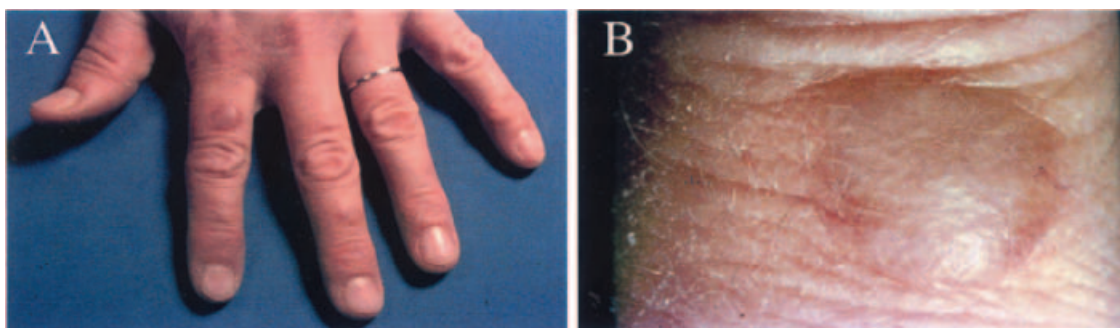


Fig. 1. Patient no.1 presented with erythematous firm papules on the dorsal aspect of her fingers (A); a close-up view (B).

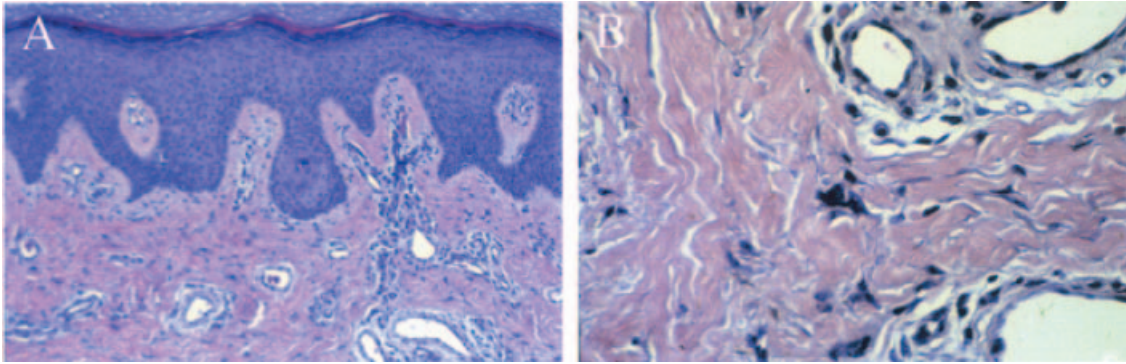


Fig. 2. Microscopic examination of multinucleate cell angiohistiocytoma (MCAH) reveals proliferation of small vessels within the upper and mid-dermis (A). High-power magnification of MCAH lesion showing multinucleate giant cell (B). (Haematoxylin-eosin staining).

## DISCUSSION

A total of 42 cases of MCAH have been reported in the literature, which means that it is most likely under-reported. Clinically, the majority of MCAH lesions present on the extremities, but they can also appear as a painless swelling of the eyelid or an isolated lip lesion (7, 8). The condition develops slowly and treatment is usually not necessary. The lesions can be successfully treated with argon laser (9).

The main histopathological feature is the increased number of blood vessels accompanied by a fibrohistiocytic cell infiltrate with multinucleated cells (10). Based on this, MCAH is distinguishable from other types of haemangiomas and dermal fibrohistiocytic tumours. Microvenous haemangioma is an MCAH-like vascular tumour with a similar type of proliferation of capillaries and small venules. This was also the first histopathological diagnosis made in two of our patients. However, a more careful examination revealed the multinucleate cells typical of MCAH. The angiomatous type of Kaposi's sarcoma can also resemble MCAH, because it may contain a few proliferating spindle cells. The extravasation of red blood cells always seen in Kaposi's sarcoma and lack of multinucleate cells helps to differentiate these two tumours.

The nature of MCAH has remained obscure. Immunohistochemically, the endothelial cells of the capillaries appear normal and stain positive for factor VIII-related antigen, Ulex europaeus I lectin, CD31 and CD34. The multinucleate cells stain positive only with antibodies to vimentin, whereas the mononuclear interstitial cells are positive for CD68, lysozyme and  $\alpha$ 1-antitrypsin, but are negative for S-100 protein and CD1a. Some of them are positive also for monocyte-macrophage marker MAC 387 (10). Because the multinucleate cells are negative for macrophage markers, they are suggested to originate from fibroblasts.

Most investigators have suggested that MCAH is an inflammatory disorder rather than a real tumour. However, in a recent study, Sass et al. could not find human herpesvirus-8 in the skin lesions of two patients

(11). They also cultured cells from MCAH lesions and found that the cultured cells were short-lived and could not be passaged as cells from Kaposi's sarcoma. This finding further supports the view of an inflammatory origin of the MCAH tumours.

In the previous literature, MCAH is considered to be underreported. We believe the situation is similar in Finland, since these are the first reported cases. However, MCAH has distinctive clinicopathological features and is easy to diagnose if it is kept in mind.

## REFERENCES

1. Smith NP, Wilson Jones E. Multinucleate cell angiohistiocytoma: a new entity. *Br J Dermatol* 1985; 113: 15.
2. Smolle J, Auboeck L, Gogg-Retzl I, Soyer H-P, Kerl H. Multinucleate cell angiohistiocytoma: a clinicopathological, immunohistochemical and ultrastructural study. *Br J Dermatol* 1989; 121: 113–121.
3. Wilson Jones E, Cerio R, Smith NP. Multinucleate cell angiohistiocytoma: an acquired vascular anomaly to be distinguished from Kaposi's sarcoma. *Br J Dermatol* 1990; 122: 651–663.
4. Duncan LM, Howard PB. Vascular papules on the dorsum of the hands. *Arch Dermatol* 1996; 132: 703–708.
5. Annessi G, Girolomoni G, Giannetti A. Multinucleate cell angiohistiocytoma. *Am J Dermatopathol* 1992; 14: 340–344.
6. Zelger BW, Steiner H, Kutzner H. Clear cell dermatofibroma. *Am J Surg Pathology* 1996; 20: 483–491.
7. Jones AG, Mullins D, Jimenez F. Multinucleate cell angiohistiocytoma of the upper lip. *Oral Surg Med Pathol* 1994; 78: 743–747.
8. Shields JA, Eagle RC, Shields CL, Sohmer K. Multinucleate cell angiohistiocytoma of the orbit. *Am J Ophthalmol* 1995; 120: 402–403.
9. Kopera D, Smolle J, Kerl. Multinucleate cell angiohistiocytoma: treatment with argon laser. *Br J Dermatol* 1995; 133: 308–310.
10. Requena L, Sanguenza OP. Cutaneous vascular proliferations. Part III. Malignant neoplasms with significant vascular component, and disorders erroneously considered as vascular neoplasms. *J Am Acad Dermatol* 1998; 38: 143–175.
11. Sass U, Noel JC, Andre J, Simonart T. Multinucleate cell angiohistiocytoma: report of two cases with no evidence of human herpesvirus-8 infection. *J Cutan Pathol* 2000; 27: 258–261.