

CLINICAL REPORT

Cutaneous Infection Caused by *Ulocladium chartarum* in a Heart Transplant Recipient: Case Report and ReviewMARÍA TERESA DURÁN¹, JESÚS DEL POZO², MARÍA TERESA YEBRA³, MARÍA GENEROSA CRESPO⁴, MARÍA JESÚS PANIAGUA⁴, MARÍA ANGELES CABEZÓN⁵ and JOSEP GUARRO⁶*Departments of ¹Microbiology, ²Dermatology, ³Pathology, ⁴Cardiology, and ⁵Plastic Surgery, Complejo Hospitalario Universitario Juan Canalejo, A Coruña, Spain, ⁶Unit of Microbiology, Facultat de Medicina i Ciències de la Salut, Universitat Rovira i Virgili, Reus, Tarragona, Spain*

A cutaneous mycoses caused by *Ulocladium chartarum* in a heart transplant recipient is reported. The infection cleared after complete surgical excision and 6 months of oral itraconazole therapy. *In vitro* activity of amphotericin B, fluconazole, itraconazole, voriconazole, ravuconazole and terbinafine against the clinical isolate is shown. Key words: dermatomycoses; immunocompromised host; skin diseases.

(Accepted February 3, 2003.)

Acta Derm Venereol 2003; 83: 218–221.

M^a Teresa Durán Valle, Servicio de Microbiología, Complejo Hospitalario Universitario Juan Canalejo, Xubias de Arriba s/n. 15006, A Coruña, Spain. E-mail: tduran@canalejo.org

Ulocladium spp. are dematiaceous fungi found as ubiquitous saprobes on rotten plant material and soil. They have low pathogenicity and have rarely been reported as human opportunistic pathogens.

Up to now, two species have been isolated from clinical specimens on several occasions: *Ulocladium chartarum* and *U. botrytis*; however, the pathogenicity of the latter has not been proven. Previously, *U. chartarum* had been included in *Alternaria* as *A. chartarum* and *A. stemphylioides*. Currently, these two names are considered synonymous, as has been stated by Simmons (1).

Only four cases of infection caused by *U. chartarum* have been described in the literature, and three of these have been incorrectly reported as being alternariosis. We describe the first case of cutaneous infection caused by *U. chartarum* in a heart transplant recipient and review the literature.

CASE REPORT

A 62-year-old male heart transplant recipient came to the hospital for a routine endomyocardial biopsy 1 year after transplantation. Over the previous 4 weeks he had noticed a painless, flesh-coloured cutaneous lesion on his right toe. He did not report any fever, malaise or sweating. There was no history of trauma. His immunosuppressive therapy included tacrolimus 2 mg/day, azathioprine 100 mg/day and prednisone 10 mg/day.

On physical examination, a 6-cm² sharply demarcated plaque on the dorsal area of his right big toe was noticed. The lesion had a granular surface and a vermiculate consistency (Fig. 1). No additional lesions were observed.

A cutaneous biopsy was obtained. The histopathologic examination of the biopsy revealed a granulomatous dermal infiltrate and scarce stellate abscesses. The granuloma and the margins of the abscesses were composed of lymphocytes, histiocytes, epithelioid cells and multinucleated giant cells. In tissue sections stained with hematoxylin-eosin, numerous rounded, refringent, hyaline or slightly eosinophilic thick-walled fungal structures were present in the granuloma and within the giant cells. Scarce elongated budding yeast-like forms and branched septate hyphae were also present. Fungal elements were strongly stained with periodic acid-Schiff (PAS) (Fig. 2) and Grocott-Gomori methenamine-silver

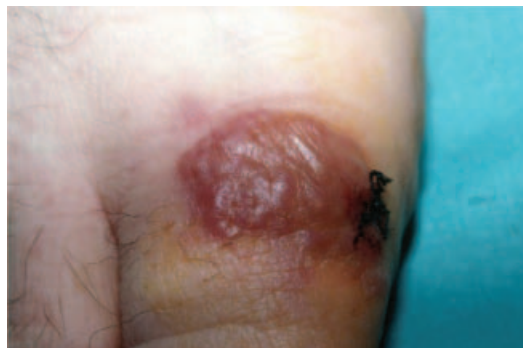

Fig. 1. Sharply demarcated granular plaque on the dorsal area of the right big toe with a vermiculate consistency.

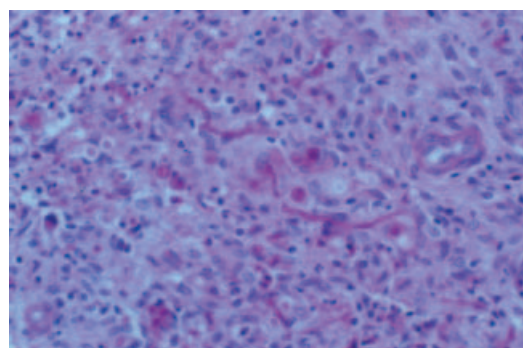


Fig. 2. PAS-positive branched septate hyphae and conidia ($\times 400$).

nitrate stains. Brown pigment was not present in fungal cell walls after Masson-Fontana stain.

A total surgical resection of the lesion was done and the biopsy was sent to pathology and microbiology laboratories for examination. The histopathology was similar to that observed in the previous biopsy. The biopsy was homogenized for culture and stains in the microbiology laboratory. The homogenate was inoculated on bacteriologic (blood, chocolate and McConkey agars and thioglycolate broth) and mycologic media (Sabouraud dextrose agar with and without chloramphenicol and gentamicin and brain heart infusion agar with 5% of blood) that were incubated at 35°C and 30°C, respectively.

Blood cultures were collected and a sample of serum for cryptococcal antigen was obtained. Calcofluor white stain of the homogenate showed branched septate hyphae and budding yeast-like forms.

After 2 days of incubation, a large number of colonies of a mould began to grow on all the mycologic and bacteriologic media. The isolate was in pure culture. The mould was subsequently cultured on potato dextrose agar (PDA) and mycobiotic agar at 30°C and 35°C. The colonies reached 6 cm on PDA after 7 days of incubation at 30°C, being powdery to lanose and black to olivaceous black; the mould grew more slowly at 35°C; and there was no growth on mycobiotic. Microscopic examination of slide cultures on PDA showed a mycelium with pale yellow or brown septate hyphae. The conidiophores were erect, geniculate, simple or branched and golden brown. The conidia were brown and verrucose with transverse and longitudinal septa, solitary or in chains through apical production of short conidiophores (false beaks) (Fig. 3). On the basis of these characteristics the mould was identified as *U. chartarum*. No other species of fungus was recovered after 30 days of incubation on the mycologic media. Blood cultures and serum cryptococcal antigen were negative.

Antifungal susceptibility testing of the isolate was carried out using the broth microdilution method in

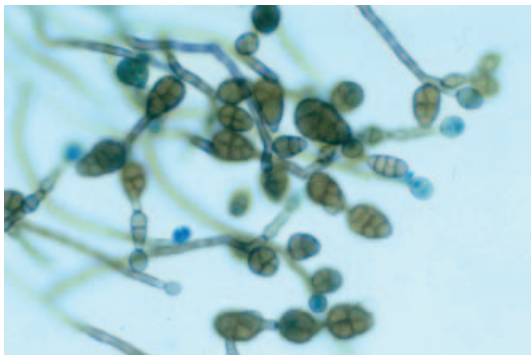


Fig. 3. Slide culture of *Ulocladium chartarum* on PDA (Lactophenol blue $\times 650$). Verrucose conidia, chains of conidia and apical production of short conidiophores (false beaks).

accordance with the recommendations of the National Committee for Clinical Laboratory Standards (M38-P) (2) with the modifications introduced by Pujol et al. (3), a temperature of incubation of 32°C and reading at 72 h. Minimal inhibitory concentrations (MICs) of antifungal agents were: 2 µg/ml of amphotericin B, 1 µg/ml of fluconazole, 2 µg/ml of itraconazole, 2 µg/ml of voriconazole, 1 µg/ml of ravuconazole and 2 µg/ml of terbinafine.

Empirical treatment with oral itraconazole (400 mg/day) was started after complete surgical removal of the lesion, and was continued for 6 months. The patient required dose adjustment of tacrolimus at 1 mg/day because of interaction with itraconazole. The prednisone dose was decreased to 8.75 mg/day and 3 months later to 7.5 mg/day, following protocol rules. Azathioprine was switched to mycophenolate mofetil.

Four months after the completion of treatment, no relapse of the lesion was observed and the surgical wound had fully healed.

DISCUSSION

In the review of the literature we found four cutaneous infections caused by *U. chartarum* described by Altmeyer & Schon (4), Verret et al. (5), Blanc et al. (6) and Magina et al. (7), but three were erroneously named alternariosis. All, including our case report, occurred in immunocompromised patients. The five cases are described in Table I.

Cutaneous mycoses caused by dark-pigmented saprobic fungi are rare diseases that usually follow a local trauma. With the increasing immunosuppressed population, numerous reports are emerging and *Alternaria* is among the genera documented as causal agents (8), although infections by several other agents have been reported. Isolates of *U. chartarum* may be confused with those of *A. alternata*, because both share certain microscopic similarities, such as the formation of brown multiseptate conidia, and because both can cause non-specific and similar cutaneous infections.

Morphologically, the isolates of the genus *Ulocladium* are different from those of *Alternaria* by having conidia obovoid with tapered and narrow bases, and with no or very short apical beaks (false beak). Additionally, the conidia of *Ulocladium* are in short chains or non-catenate. *U. chartarum* differs from *A. alternata*, the species that it is most likely confused with, by having conidia that are coarsely verrucose and have a short, spindle-shaped apex, as is described by De Hoog et al. (9).

Ulocladium spp. and *Alternaria* spp. also differ in their antifungal susceptibility. Both genera are resistant to flucytosine, but *Ulocladium* spp. show a higher degree of *in vitro* resistance to miconazole, ketoconazole, itraconazole, amphotericin B and fluconazole than *Alternaria* spp., as has been shown by Pujol et al. (3). Our isolate showed high MICs of amphotericin B,

Table I. Cases of infections caused by *Ulocladium chartarum* reported in the literature

Reference	Sex/age	Immunosuppression underlying disease and predisposing factors	Clinical presentation and localization	Histopathology	Treatment/evolution
4	F/58	Brill-Symmer's disease Corticosteroids.	Symmetric bilateral papular lesions on arms.	Unicellular budding spores and short hyphal fragments with thick cell walls. Cutaneous granulomatous tissue.	No specific treatment. Died from cardiac failure without curing the lesions.
5	M/67	Unrecognized Cushing's disease.	Vegetating and crusted tumor. Right knee.	Intracellular round structures PAS +. Inflammatory dermal granuloma, including epithelioid and giant cells.	Electrocoagulation, curetage and oral griseofulvine 1 g/day during 1 month. Resolution. No recurrence after 12 months.
6	M/46	Immunosuppressive treatment for renal transplant. Renal transplant 6 months before.	Nodular lesion on the antero-inferior face of the right thigh.	Round, filamentous forms, PAS and Grocott +. Fungal inclusions within histiocytes with thick cell walls.	1. Minimal excision. Recurrence 3 months later. 2. Ketoconazol 400 mg/day, 2 months. No resolution. 3. Large excision. Resolution. No recurrence 3 months later.
7	F/63	Methylprednisone, azathioprine and cyclosporine. Renal transplant 1 year before.	Nodule in nasal septum. Erythematous nodule in the right knee. Erythematous plaque+ fine scale in the left leg.	Granulomatous infiltrate in the dermis with rounded PAS positive inclusions. Fungal spores within histiocytes.	Oral itraconazole 100 mg twice a day during 3 months, methyl prednisone interrupted and azathioprine dose decreased. Cured.
Present report	M/62	Tacrolimus, azathioprine and prednisone. Heart transplant 1 year before.	Plaque. Right toe.	Granulomatous infiltrate in the dermis. Numerous rounded slightly eosinophilic fungal bodies with thick walls. Scarce budding spores and some branching and septate hyphae in hematoxylin-eosin stain. PAS and Grocott +.	Oral itraconazole 400 mg/day, 6 months. Complete surgical excision. Prednisone and tacrolimus dose decreased. Azathioprine switched to mycophenolate mofetil. No relapse 4 months later.

itraconazole, voriconazole and terbinafine but a low MIC of fluconazole. Nevertheless, the breakpoints for these antifungal agents have not been defined for this type of infection.

Phaeohyphomycoses are characterized by the presence of brownish hyphal and/or yeast-like elements in tissue, as was stated by Ajello (10), which are stained with Fontana-Masson. In our case, we could not find these dark-pigmented elements after Fontana-Masson staining, and thus could not characterize histologically the infection as being a phaeohyphomycosis. The authors of previously reported cases do not mention either the presence of the dark-pigmented forms in the infected tissues or the use of specific stain to show them.

Successful treatment of the previous infections by *U. chartarum* was reached with electrocoagulation, curettage and oral griseofulvine in the case described by Verret et al. (5) and with oral itraconazole and a decreasing dose of immunosuppressive therapy in the case by Magina et al. (7). In the case reported by Blanc et al. (6), minimal excision of the lesion or treatment with ketoconazole failed, but eventually the lesion healed after a large excision. Our patient responded to oral itraconazole with total surgical resection of the lesion.

In summary, this is the fifth clinical case of *U. chartarum*. This was a localized cutaneous infection in an immunocompromised patient. Diagnosis was based on cultural and histological examination of the cutaneous biopsy, and the dematiaceous nature of the mould was not shown until the fungus was grown on culture. Therapy consisted of total surgical excision of the lesion in combination with oral itraconazole. From this review of the literature we conclude that *U. chartarum* should be considered to cause cutaneous

mycoses in immunocompromised patients that are different from those caused by *Alternaria* spp.

REFERENCES

1. Simmons EG. Typification of *Alternaria*, *Stemphylium* and *Ulocladium*. *Mycologia* 1967; 59: 67–92.
2. National Committee for Clinical Laboratory Standards. 1998. Reference method for broth dilution antifungal susceptibility testing of conidium-forming filamentous fungi. Proposed standard. NCCLS document M38-P. National Committee for Clinical Laboratory Standards, Wayne, Pa.
3. Pujol I, Aguilar C, Gené J, Guarro J. *In vitro* antifungal susceptibility of *Alternaria* spp. and *Ulocladium* spp. *J Antimicrob Chemother* 2000; 46: 337–338.
4. Altmeyer P, Schon K. Kutane Schimmelpilzgranulome durch *Ulocladium chartarum*. *Hautarzt* 1981; 32: 36–38.
5. Verret JL, Gaborieau F, Chabasse D, Rohmer V, Avenel M, Smulevici A. Alternariose cutanée révélatrice d'une maladie de Cushing, un cas avec étude ultrastructurale. *Anna Derm Vénéreol* 1982; 109: 841–846.
6. Blanc C, Lamey B, Lapalu J. Alternariose cutanée chez un transplanté rénal. *Bull Soc Fr Mycol Méd* 1984; 13: 213–216.
7. Magina S, Lisboa C, Santos P, Oliveira G, Lopes J, Rocha M, et al. Cutaneous alternariosis by *Alternaria chartarum* in a renal transplanted patient. *Br J Dermatol* 2000; 142: 1261–1262.
8. Rinaldi MG. Phaeohyphomycosis. *Dermatol Clin* 1996; 14: 147–153.
9. De Hoog GS, Guarro J, Gené J, Figueras MJ. *Ulocladium chartarum* (Preuss) Simmons. In: *Atlas of Clinical Fungi*, 2nd edn. Centraalbureau voor Schimmelcultures, Utrecht, The Netherlands and Universitat Rovira i Virgili, Reus, Spain, 2000: 1000–1001.
10. Ajello L. Hyalohyphomycosis and phaeohyphomycosis: two global disease entities of public health importance. *Eur J Epidemiol* 1986; 2: 243–251.