

## CLINICAL REPORT

## Skin Reaction in Antiviral Therapy for Chronic Hepatitis C: A Role for Polyethylene Glycol Interferon?

FRANCESCA COTTONI<sup>1</sup>, SILVIA BOLOGNINI<sup>1</sup>, ANGELO DEPLANO<sup>2</sup>, GIOVANNI GARRUCCIU<sup>2</sup>, NOEMI ELISABETTA MANZONI<sup>2</sup>, GIOVANNA FRANCESCA CAREDDU<sup>2</sup>, MARIA ANTONIA MONTESU<sup>1</sup>, ANDREINA TOCCO<sup>2</sup>, AMELIA LISSIA<sup>3</sup> and ANTONIO SOLINAS<sup>2</sup>

Departments of <sup>1</sup>Dermatology, <sup>2</sup>Internal Medicine and <sup>3</sup>Anatomic Pathology and Histopathology, University of Sassari, Italy

**In the past decade, different modalities of antiviral therapy have been adopted aimed at eradicating hepatitis C virus infection. Initially, interferon was used in monotherapy, then interferon combined with ribavirin and amantadine. Recently, interferon has been conjugated with polyethylene glycol to allow optimization of its pharmacokinetic properties and to improve its antiviral activity. This study focused on the characteristics of the skin reactions that we observed in 27 patients with naïve hepatitis C who received polyethylene glycol interferon-ribavirin-amantadine or polyethylene glycol interferon-ribavirin and in 10 previous non-responders to interferon monotherapy who were retreated with triple therapy. In 9 patients (7 on triple therapy) dermatitis-like lesions were observed, and in 5 the severity of the lesions necessitated withdrawal from therapy. Key words: antiviral therapy; HCV; PEG interferon; skin reaction.**

(Accepted September 15, 2003.)

Acta Derm Venereol 2004; 84: 120–123.

Francesca Cottoni, Department of Dermatology, Viale San Pietro 43,b, IT-07100 Sassari, Italy. E-mail: fcottoni@uniss.it

Hepatitis C virus (HCV) infection is a common cause of morbidity and mortality worldwide. In industrialized countries, chronic hepatitis C accounts for 40% of cases of end-stage cirrhosis, 60% of hepatocellular carcinoma and 30% of liver transplants (1).

Currently, therapeutic options for chronic hepatitis C consist of interferon (IFN) alone, IFN plus ribavirin, pegylated interferon (PEG-IFN) alone and PEG-IFN plus ribavirin. IFN monotherapy, however, leads to a sustained response in fewer than 20% of patients, whereas the combination IFN and ribavirin is effective in 40% of cases (2–4).

Conjugation of IFN with polyethylene glycol (PEG) further improves its pharmacokinetic properties and its antiviral activity (3, 4). Two different types of PEG IFN are available: PEG IFN- $\alpha$ -2a and PEG IFN- $\alpha$ -2b.

In previously untreated patients the combination PEG-IFN and ribavirin achieves a sustained response ranging from 54% to 56% (3, 5).

It is not known whether a triple therapy consisting of PEG-IFN, ribavirin and amantadine would further improve the virologic response rate both in previously untreated patients and in those who do not respond to previous courses of antiviral therapy.

The safety profile of IFN alone or in combination with ribavirin is well known. Side effects include fatigue, influenza-like symptoms, neuropsychiatric symptoms and haematologic abnormalities.

Cutaneous side effects consist of itching, skin dryness, as well as overt lesions such as eczema, lichenoid eruptions and malar erythema. Their incidence seems increased in patients treated with IFN in combination with ribavirin compared with patients treated with IFN monotherapy (6, 7).

The safety profile of the combination of PEG-IFN and ribavirin seems to be similar to that of IFN and ribavirin. Namely, dermatitis has been reported in 21% of patients treated with PEG IFN- $\alpha$ -2a and ribavirin and in 18% of patients treated with IFN- $\alpha$ -2b and ribavirin (8).

In December 2001, we undertook a controlled randomized study aimed at evaluating the efficacy and safety profile of the combination PEG IFN- $\alpha$ -2b, ribavirin and amantadine (triple therapy) versus the standard therapy PEG-IFN- $\alpha$ -2b and ribavirin (double therapy). In the same period, we also undertook an open study to evaluate the efficacy of PEG IFN- $\alpha$ -2b, ribavirin and amantadine in a group of patients who had relapsed after a course of high dosage IFN monotherapy. This report focused on the cutaneous side effects that we observed in these patients.

### PATIENTS AND METHODS

Twenty-seven patients with previously untreated (naïve) chronic hepatitis C have so far been enrolled in the study aimed at evaluating the efficacy of the triple therapy (PEG IFN- $\alpha$ -2b, ribavirin and amantadine) versus the double therapy (PEG IFN- $\alpha$ -2b and ribavirin). The diagnosis of chronic hepatitis C was based on aminotransferase (ALT) levels at least twice above the normal level, the presence of HCV-RNA detectable in serum by polymerase chain reaction (PCR), and liver histology evidence of chronic hepatitis.

These patients were randomized to receive: 1) PEG IFN- $\alpha$ -2b 1.5  $\mu$ g/kg body weight, up to a maximum of

100 µg, once weekly plus ribavirin 800–1200 mg/daily, plus amantadine 200 mg/daily versus 2) PEG IFN- $\alpha$ -2b plus ribavirin at the same doses as above. In addition, we enrolled 10 other patients with chronic hepatitis C who had failed to achieve a sustained response to a previous therapy with high-dose IFN monotherapy and who now received the triple therapy according to the above schedule. In agreement with recently published guidelines, the duration of treatment was 48 weeks for patients with HCV genotypes 1 and 4, and 24 weeks for patients with genotypes 2 and 3. Patients positive for HCV RNA at week 24 were considered non-responders and were withdrawn from therapy.

This study protocol was approved by our ethics committee, and informed consent to participate in the study was obtained from all patients.

Naïve patients treated with the double therapy were similar to those treated with the triple therapy in regard to ALT activity, histological severity of the liver disease, HCV RNA serum levels and HCV genotype distribution. Among retreated patients, 9 of 10 were infected with HCV genotype 1b. Efficacy of treatment was based on virologic response determined by standard PCR and transcription mediated assay (TMA)-based techniques.

## RESULTS

At the time of writing, only 7 patients with genotype 2 or 3 have completed the per protocol established treatment period. In the remainders the period of therapy ranged from 1–11 months. So far, HCV RNA has become undetectable in 20 patients. Ten out of 37 cases, however, have been withdrawn from therapy: 2 were non-responders after 24 weeks of treatment; one had psychiatric side effects; one had intolerable asthenia; one because of the occurrence of a perianal abscess; and 5 cases because of serious skin reactions. A further 4 patients have shown cutaneous side effects but not enough to warrant withdrawal from therapy.

### *Characteristics of the cutaneous lesions observed in 9 patients*

Of the 9 patients, 7 were in treatment with the triple therapy (5 previously untreated and 2 previously non-responders) and 2 were under double therapy. On average, initiation of the cutaneous side effects has occurred after 2 months of therapy (ranging between 1 week and 4 months). Skin lesions were characterized by erythematous eczematous itching lesions over the whole body (2 cases), and by erythematous papules and desquamative patches (6 cases) localized at the abdomen and lower limbs (1 case), at the knees (1 case), at the forehead and at the back of the neck (1 case), at the lower limbs and trunk (1 case), at the upper limbs and face (1 case) and at the upper and lower limbs (1 case) (Fig. 1). One patient, affected by Darier's disease, suffered a worsening of previous lesions over the whole surface of the skin.

In addition, in 8 of 9 cases there was an erythematous wheal lesion at the site of injection of PEG-IFN, which

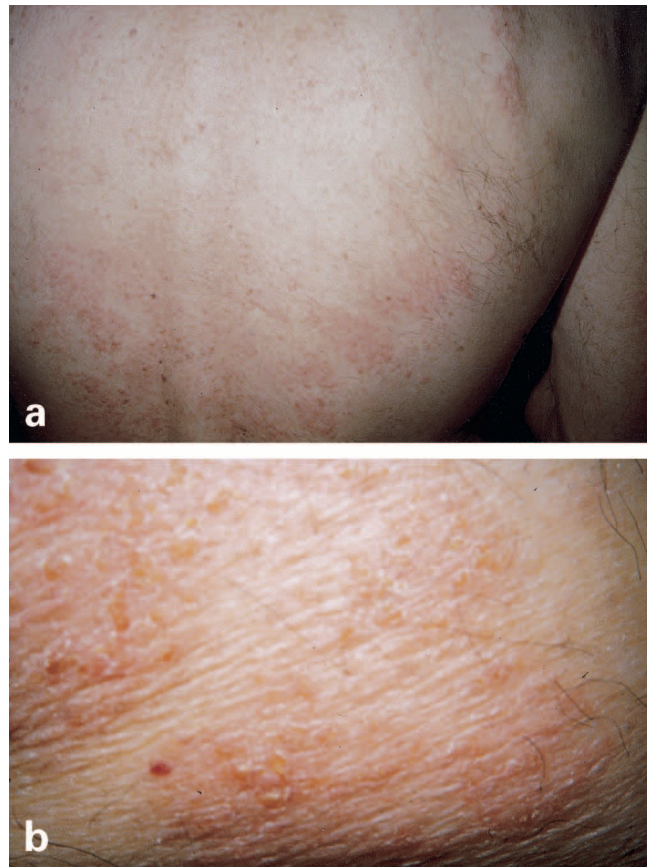


Fig. 1. Eczematous lesions on the back (a) with erythematous-desquamative papules (b).

occurred within 2 h after the injection and faded after several days. A similar reaction at the site of injection, on the other hand, was observed in 14 patients who did not develop skin side effects.

Of the 9 patients with skin reactions, 6 had cutaneous biopsies done. All biopsy specimens except the one concerning the patient with Darier's disease showed focal spongiosis of the epidermis with occasional lymphocytic exocytosis. At the superficial dermal level there was oedema and a perivascular lymphocytic infiltrate with various degrees of intensity. There were also rare eosinophils.

Besides the typical pattern of the underlying disease, the cutaneous biopsy of the patient suffering from Darier's disease showed a modest perivascular lymphocytic infiltrate in the dermis. Immunohistochemistry performed on 2 biopsies showed that the lymphocytic infiltrate consisted mainly of CD4 positive cells. In addition, in 2 of the 6 patients a cutaneous biopsy was made at the injection site, and a histological picture similar to the one in the other biopsy specimens was found.

### *Outcome of the cutaneous lesions*

The antiviral therapy was withdrawn in 2 patients with diffuse eczematous itching, in 2 patients with

erythematous papules and in one patient who showed eczematous lesions and worsening of Darier's disease. Apart from the latter case, recovery from the skin lesions was slow, up to 4 weeks, after withdrawal of antiviral therapy. One patient was given oral prednisone because of the seriousness of the clinical picture. In the 4 cases in whom the therapy was continued, skin lesions gradually subsided during topical therapy with corticosteroids and, in one case, dose reduction of ribavirin.

## DISCUSSION

Cutaneous side effects have been reported in the course of therapy for HCV chronic hepatitis either with IFN- $\alpha$  alone or in association with ribavirin. In particular, a significant increase in adverse skin reactions with combined therapy compared to IFN monotherapy has been shown.

A study by Manjon-Haces et al. (6) considered 210 patients with HCV chronic hepatitis under treatment with IFN- $\alpha$ -2b plus ribavirin: skin lesions appeared in 27 cases. Of the 27 patients, 16 presented eczematous lesions, 4 disseminated prurigo-type lesions, 2 lichenoid eruption, 2 seborrhoeic dermatitis, 2 maculopapular exanthem and 1 developed thoracic herpes zoster. In no cases was it necessary to stop the therapy because of the cutaneous side effects.

Another study (7) compared the incidence of skin reactions in 33 patients treated with IFN- $\alpha$  plus ribavirin with those in a group of 35 patients receiving IFN- $\alpha$  alone. Of the 33 patients treated with the combination therapy, 11 developed cutaneous lesions: 3 presented eczematous lesions, 3 lichenoid eruption, 2 malar erythema, 2 rashes, and 1 developed lichen planus. One patient had to be withdrawn from therapy because of adverse cutaneous effects. On the other hand, of the 35 patients treated with IFN- $\alpha$  alone, only 2 presented lichenoid eruption.

Dereure et al. (9) reported a series of 20 patients who developed eczema-like skin lesions during therapy with IFN and ribavirin: in half of them the treatment had to be discontinued. In the present study, we treated 37 HCV-positive patients: 27 previously untreated and 10 already treated. Twenty-four patients were treated with triple therapy (PEG IFN- $\alpha$ -2b, ribavirin and amantadine) and 13 with double therapy (PEG IFN- $\alpha$ -2b and ribavirin). We observed the appearance of side effects in 12 patients, 9 of them showing cutaneous side effects: 7/24 (29%) were in triple therapy (5 previously untreated and 2 in retreatment) and 2/13 (15%) in double therapy ( $p=0.44$ ). Because of the severity of the cutaneous side effects, 5 patients had to suspend the treatment. Of these 5, 4 were in triple therapy, whereas the only patient in double therapy who had to stop the treatment was the one with Darier's disease.

Treatment withdrawal is the only course to take in

the setting of adverse skin reaction, but it has rarely been reported during antiviral therapy. Of note in the present study is the elevated number of patients whose treatment had to be suspended because of side effects, mostly eczema-like lesions which occurred particularly under triple therapy.

In our opinion, an explanation for such severe skin reactions could lie in a possible synergic action between the drugs that we used for eradicating the virus. The addition of amantadine might increase the percentage of cutaneous side effects. A further point to consider is the pathogenetic role of PEG-IFN. PEG is often used as an additive in products such as topical drugs and cosmetics (10–13), and the literature refers to several cases of unwanted cutaneous side effects, particularly contact dermatitis, caused by this additive. Indeed, histological findings, which were available in 6 of 9 of our patients suggest that antiviral therapy led to skin lesions similar to those observed in contact dermatitis rather than to allergic drug reaction. In fact all biopsies, including those from the injection site, revealed an infiltrate characterized by lymphocytes, whereas eosinophil infiltrate, which is typical of allergic drug reactions, was scanty in all cases. Furthermore, in 2 cases the immunohistochemistry showed that the majority of lymphocytes were CD4 positive. Altogether, these findings suggest that the skin reactions we observed pertain to immunologic sensitization; the mechanism whereby contact dermatitis-like lesions spread all over the body remains to be clarified.

## REFERENCES

1. EASL international consensus conference on hepatitis C Paris 26–28, February 1999 consensus statement. European Association for the Study of the Liver. *J Hepatol* 1999; 30: 956–961.
2. Leung NW. Management of viral hepatitis C. *J Gastroenterol Hepatol* 2002; 17 Suppl.: 146–154.
3. Manns MP, McHutchison JG, Gordon SC, Rustgi VK, Shiffman M, Reindollar R, et al. Peginterferon alfa-2b plus ribavirin compared with interferon  $\alpha$ -2b plus ribavirin for initial treatment of chronic hepatitis C: a randomized trial. *Lancet* 2001; 358: 958–965.
4. Lindsay KL, Trepo C, Heintges T, Shiffman ML, Gordon SC, Hoefs JC, et al. A randomized, double-blind trial comparing pegylated interferon alfa-2b to interferon  $\alpha$ -2b as initial treatment for chronic hepatitis C. *Hepatology* 2001; 34: 395–403.
5. Fried MW, Shiffman ML, Reddy KR, Smith C, Marinos G, Goncales FL, Jr, et al. Peginterferon alfa-2a plus ribavirin for chronic hepatic infection. *N Engl J Med* 2003; 348: 259–260.
6. Manjon-Haces JA, Vazquez-Lopez F, Gomez-Diez S, Hidalgo-Garcia Y, Perez-Alvarez R, Soler-Sanchez T, et al. Adverse cutaneous reactions to interferon alfa-2b plus ribavirin therapy in patients with chronic hepatitis C virus. *Acta Derm Venereol* 2001; 81: 223.
7. Sookoian S, Neglia V, Castano G, Frider B, Kien MC, Chouela E. High prevalence of cutaneous reactions to interferon  $\alpha$  plus ribavirin combination therapy in

- patients with chronic hepatitis C virus. *Arch Dermatol* 1999; 135: 1000–1001.
8. Fried MW. Side effects of therapy of hepatitis C and their management. *Hepatology* 2002; 36: S237–S244.
  9. Dereure O, Raison-Peyron N, Larrey D, Blanc F, Guilhou J-J. Diffuse inflammatory lesions in patients treated with interferon  $\alpha$  and ribavirin for hepatitis C: a series of 20 patients. *Br J Dermatol* 2002; 147: 1142–1146.
  10. Fisher AA. Immediate and delayed allergic contact reactions to polyethylene glycol. *Contact Dermatitis* 1978; 4: 135–138.
  11. Andersen KE, Roed-Petersen J, Kamp P. Contact allergy related to TEA-PEG-3 cocamide sulfate and cocamidopropyl betaine in a shampoo. *Contact Dermatitis* 1984; 11: 192–193.
  12. Daly DM. Bacroban allergy due to polyethylene glycol. *Contact Dermatitis* 1987; 17: 48–49.
  13. Ranchoff RE, Taylor JS. Contact dermatitis to anaerobic sealants. *J Am Acad Dermatol* 1985; 13: 1015–1020.