

Lichenoid Drug Eruption with HMG-CoA Reductase Inhibitors (Fluvastatin and Lovastatin)

Bela Sebök¹, Margit Tóth², Bela Anga³, Ferenc Harangi¹ and Imre Schneider⁴

¹Section of Dermatology, Dorozsmai & Co. Medical Ltd, Pécs, ²Section of Internal Medicine, City Hospital, Mohács, ³Department of Pathology, County Hospital Pécs and ⁴Department of Dermatology, University of Pécs, Hungary. E-mail: sebela@vnet.hu
Accepted September 10, 2003.

Sir,

Cutaneous drug reactions have a wide variety of clinical features. Lichenoid drug eruptions (LDE) are rare and it may be difficult to differentiate them from idiopathic lichen planus (1, 2). Gold, quinine, quinidine and penicillamine are well-known inducers of such eruptions (1, 2), but there are only a few reports of lichenoid eruption induced by 3-hydroxy-3-methyl-glutaryl co-enzyme A (HMG-CoA) reductase inhibitors (2, 3). Here we report a case of fluvastatin- and lovastatin-induced lichenoid eruption.

CASE REPORT

A 59-year-old woman suffering from hypertension and hypercholesterolaemia presented with a 4-week history of a bilateral pruritic, papulous eruption on the dorsal aspects of her forearms, hands, on the volar surfaces of her wrists, on the soles and to a lesser extent on her trunk and thighs. Examination revealed multiple lentil-sized, shiny, violaceous papules and larger (up to 1 × 1 cm in size) plaques (Fig. 1). Wickham's striae were seen on the surface of the single papules. She had yellowish-white, lacework forming streaks on the oral mucosa. There was neither other mucosal nor nail or scalp involvement. The patient had begun taking fluvastatin (20 mg/day) for hypercholesterolaemia 4 weeks prior to the eruption. The itching-burning sensations caused by the skin signs were usually most pronounced in the evenings after the drug had been taken. Topical corticosteroids improved the lesions only temporarily. Although the skin and mucosal lesions were characteristic of idiopathic lichen planus, we hypothesized that fluvastatin could be a causative factor. The fluvastatin therapy was stopped and the

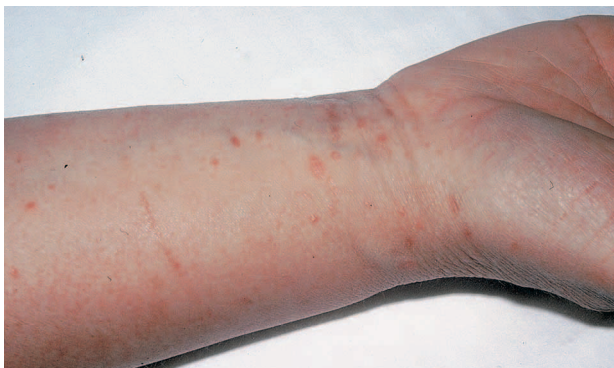

Fig. 1. Multiple erythematous, shiny papules on the volar surface of the right wrist.

eruptions were treated by mometason-furoate ointment (once daily, for 2 weeks). The antihypertensive treatment (perindopril, 4 mg/day) remained unchanged. The rash and the mucosal signs cleared slowly, within 3 weeks after cessation of fluvastatin, but the cholesterol level rose again and she was prescribed lovastatin (20 mg/day). After 2 weeks the eruption recurred and a skin biopsy showed features of a lichenoid dermatitis with "band-like" lymphocytic infiltrate in the upper dermis as well as vacuolar alteration along the dermo-epidermal junction in the epidermis. A hyperkeratotic stratum corneum and colloid bodies were also observed (Fig. 2). A diagnosis of lichenoid drug reaction was made and lovastatin stopped. The rash cleared within 3 weeks, leaving mild post-inflammatory hyperpigmented macules.

DISCUSSION

The HMG-CoA reductase inhibitors are widely used and are effective drugs in the treatment of hypercholesterolaemia. In the literature, cutaneous side effects of this group of drugs ("statins") have rarely been described. Krasovec et al. (4) and Feldmann et al. (5) reported patients with eczematous skin rashes possibly due to simvastatin and pravastatin. There are only two reported cases of lichenoid eruption due to HMG-CoA reductase inhibitors. One is induced by simvastatin, the other by pravastatin (2, 3).

Differentiating LDE from idiopathic lichen planus is not easy. There are data showing that the absence of

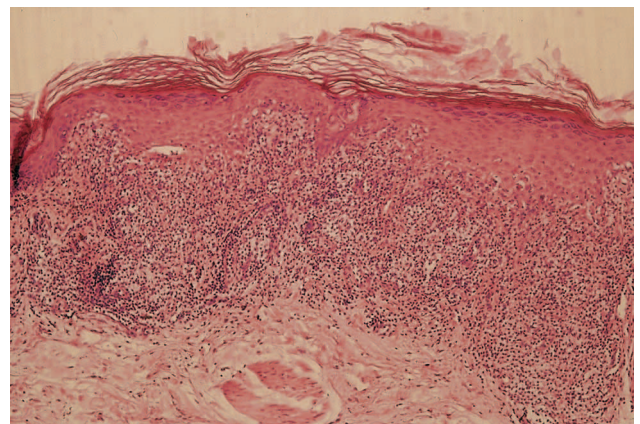


Fig. 2. Histological examination revealed "band-like" lymphocytic infiltrate in the upper dermis as well as vacuolar alteration along the dermo-epidermal junction in the epidermis. Hyperkeratotic stratum corneum and colloid bodies were also observed (H&E staining).

Wickham's striae, eosinophils as well as plasma cells in the cellular infiltrate and focal parakeratosis are frequent features in LDE (2, 6). Although we observed neither eosinophils and plasma cells in the infiltrate nor focal parakeratosis in the biopsy of our case, based on the following points we believe that she had a "statin"-induced lichenoid eruption: (a) the skin signs appeared 4 weeks after the initiation of fluvastatin therapy; (b) after discontinuation of fluvastatin the rash disappeared; (c) after a nearly 5-week period without any medical treatment for hypercholesterolaemia there was a similar (identical?) lichenoid eruption within 2 weeks after initiating lovastatin therapy and; (d) the rash disappeared again after discontinuation of the therapy. Interestingly, the two drugs differ structurally from each other. Lovastatin is a prodrug and requires hydrolysis for the effective antilipaemic activity, while fluvastatin exists in an active hydroxy acid form. Both drugs (lovastatin after a hydrolytic process, that means in its active form), however, are structurally similar to HMG-CoA, and compete with this compound for interaction with HMG-CoA reductase.

The HMG-CoA reductase inhibitors are frequently used drugs. In view of our patient and the other published cases, a possible association between lichenoid eruptions and these drugs should be kept in mind.

REFERENCES

1. Halevy S, Shai A. Lichenoid drug eruptions. *J Am Acad Dermatol* 1993; 29: 249–255.
2. Keough GC, Richardson TT, Grabski WJ. Pravastatin-induced lichenoid drug eruption. *Cutis* 2000; 61: 98–100.
3. Roger D, Rolle F, Labrousse F, Brosetti A, Bonnetblanc JM. Simvastatin-induced lichenoid drug eruption. *Clin Exp Dermatol* 1994; 19: 88–89.
4. Krasovec M, Elsner P, Burg G. Generalized eczematous skin rash possibly due to HMG-CoA reductase inhibitors. *Dermatology* 1993; 186: 248–252.
5. Feldmann R, Mainetti C, Saurat J-H. Skin lesions due to treatment with simvastatin (Zocor[®]). *Dermatology* 1993; 186: 272.
6. Orfanos CE, Garbe C. *Therapie der Hautkrankheiten*. 2. Aufl. Berlin, Heidelberg, New York: Springer Verlag, 2002: 430–431.