

Facial Majocchi's Granuloma Caused by *Trichophyton tonsurans* in an Immunocompetent Patient

Hsuan-Hiang Chen and Hsien-Ching Chiu

Department of Dermatology, National Taiwan University Hospital, 7, Chung-Shan South Road, Taipei, Taiwan

E-mail: hcc@ha.mc.ntu.edu.tw

Accepted September 4, 2002.

Sir,

Majocchi's granuloma is a cutaneous dermatophyte infection of dermal and subcutaneous tissue mostly localized at trauma-prone areas in healthy individuals (1, 2). Various species of dermatophytes can cause Majocchi's granuloma, both in immunocompetent and immunocompromised hosts (3–7). We describe an immunocompetent patient developing Majocchi's granuloma caused by *Trichophyton tonsurans* on the right cheek, which, to the best of our knowledge, has never been reported.

CASE REPORT

A 53-year-old man presented with a 1-week history of progressive, asymptomatic plaques that began on the lower part of his right ear and subsequently spread to the right cheek. The patient had a long history of a generalized eczema of unknown cause prior to the development of the plaques. He had been treated with topical and oral corticosteroids off and on for more than 14 years. He had regularly shaved the mustache area, but denied any history of facial trauma or previous cutaneous fungal infections. Physical examination revealed ill-defined, erythematous, indurated plaques surmounted with 1–5 mm, skin-coloured to reddish, non-tender papules on the right side of the face, spanning from the lower part of the right ear to the right cheek (Fig. 1). No cervical or axillary lymphadenopathy was noted. A biopsy specimen was obtained from one of the papules on the right cheek.

Histopathologic examination of the biopsy specimen demonstrated minimal hyperkeratosis with irregular acanthosis. There was a dense perifollicular suppurative granulomatous inflammation in the dermis (Fig. 2A). The pilary complex was markedly involved with endothrix spores found within the hair fragment and arthrospores lined up vertically along the cuticle. Gomori methenamine silver (GMS) stain showed many yeast-like organisms in the hair fragment and among the perifollicular granulomatous dermal infiltrate (Fig. 2B). Cultures of the biopsy specimen grew *T. tonsurans* characterized by colonies with a suede-like powdery surface and a red-brown undersurface. The slide culture showed pyriform, club-shaped and balloon-shaped microconidia on short sterigmata. A diagnosis of Majocchi's granuloma caused by *T. tonsurans* was established. A 2-month course of griseofulvin 1g daily was given. The skin lesions resolved completely and there has been no recurrence in the following 9 months.

DISCUSSION

Majocchi's granuloma is a well-recognized infection of dermal and subcutaneous tissue by dermatophytes, which usually infect the superficial epidermis (1). Most of them presented as perifollicular papules on the areas prone to trauma or with a long-standing history of occlusion in healthy individuals with chronic dermatophytosis (2). Occasionally, it may manifest as nodular plaque lesions or abscesses in immunocompromised hosts (3–7). Typically, the lesions of Majocchi's granuloma are located on the extremities. Its occurrence on the face is rarely seen. Only two cases with Majocchi's granuloma on the head have been reported. One of them, a patient with chronic obstructive lung disease treated with oral corticosteroids, had abscess formation on the face (5). The other one without any underlying medical problem had the lesion on the jaw (5). The causative fungi in these two cases were not known.

The most common organism associated with

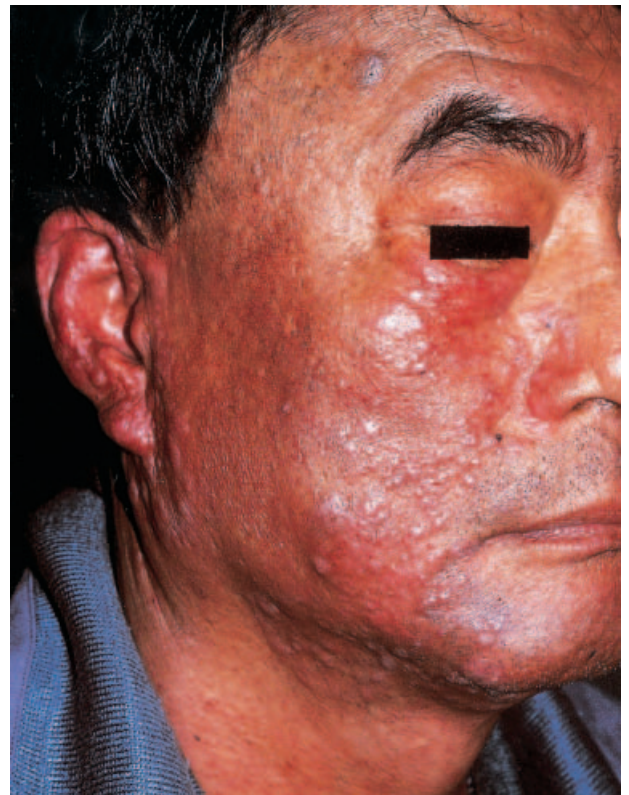

Fig. 1. Ill-defined, erythematous, indurated plaques surmounted with skin-coloured to reddish, non-tender papules on the right side of the face.

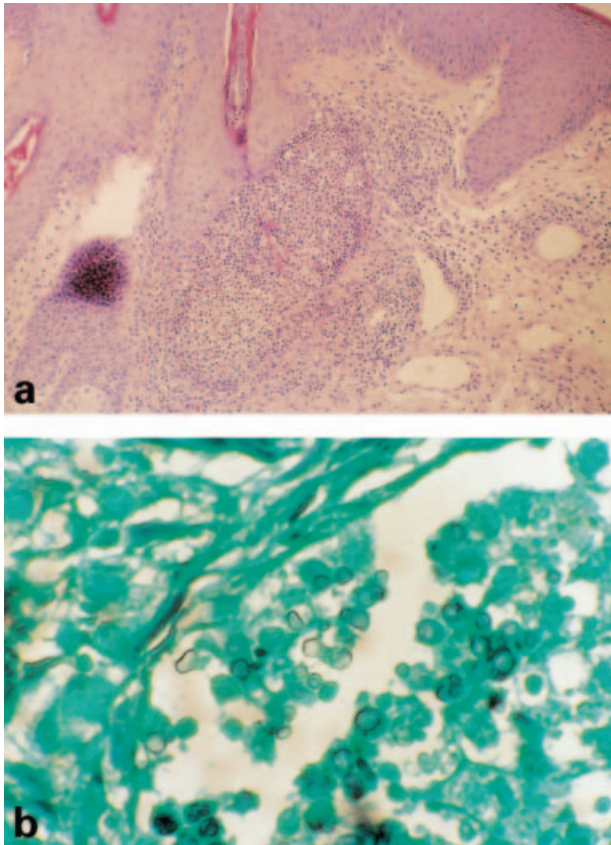


Fig. 2. A dense perifollicular suppurative granulomatous inflammation in the dermis. The pilary complex was markedly involved with endothrix spores found within the hair fragment (a) (haematoxylin and eosin; original magnification $\times 100$). Many yeast-like organisms in the perifollicular granulomatous dermal infiltrate (b) (Gomori methenamine silver stain; original magnification, $\times 400$).

Majocchi's granuloma is *T. rubrum*, both in immunocompromised and immunocompetent groups. Other dermatophytes including *T. mentagrophytes*, *T. epilans*, *T. violaceum*, *Microsporum audouinii*, *M. gypseum*, *M. ferrugineum* and *M. canis* have also been reported to cause Majocchi's granuloma (5).

T. tonsurans is an anthropophilic dermatophyte and a natural pathogen of humans. It was rarely described as a causative agent in Majocchi's granuloma and was rarely responsible for glabrous skin infection. Its distribution is restricted mainly to the USA and Mexico, and it is the most common cause of tinea capitis in the USA (8). Typically, the clinical appearance of *T. tonsurans* infection is an annular scaly patch with a raised margin and slight inflammation. Nodular and plaque lesions caused by *T. tonsurans* have only been reported in two cases previously (6, 7), one receiving cardiac transplant and the other with HIV infection.

The histological features of Majocchi's granuloma

include variable acanthosis, diffuse granulomatous dermal infiltration of lymphohistiocytic cells with focal collection of neutrophils, follicular disruption, capillary proliferation, vascular ectasia and extravasated red blood cells. The periodic acid-Schiff and GMS stains demonstrate hyphae and arthrospores within hairs and hair follicles and in the inflammatory infiltrate of the dermis. The Splendore-Hoeppli phenomenon can occasionally be seen (5). There are no clear-cut histologic features characterizing the lesions caused by specific organisms or the degree of immunologic compromise of the infected person. Follicular disruption with passive introduction of the fungi into the dermis, changes in the dermal environment by introduction of foreign material, and morphologic changes in the organisms including the production of sialomucin in the capsules of the arthrospores may help the organisms persist in areas other than the epidermis (5). In our case, a long-term use of topical steroids may help disrupt the epidermis and cause this disease (9), although the possibility that shaving-induced trauma plays some role could not be ruled out.

In summary, our case is unique in the unusual facial localization of Majocchi's granuloma in an immunocompetent host with an unusual causative agent, *T. tonsurans*.

REFERENCES

1. Elgart ML. Tinea incognito: an update on Majocchi granuloma. *Dermatol Clin* 1996; 14: 51–55.
2. Wilson JW, Plunkett OA, Gregersen A. Nodular granulomatous perifolliculitis of the legs caused by *Trichophyton rubrum*. *Arch Dermatol* 1954; 69: 258–277.
3. Radentz WH, Yanese DJ. Papular lesions in an immunocompromised patient. *Arch Dermatol* 1993; 129: 1189–1190.
4. Gupta S, Kumar B, Radotra BD, Rai R. Majocchi's granuloma trichophyticum in an immunocompromised patient. *Int J Dermatol* 2000; 39: 140–141.
5. Smith KJ, Neafie RC, Skelton III HG, Barrett TL, Graham JH, Lupton GP. Majocchi's granuloma. *J Cutan Pathol* 1991; 18: 28–35.
6. Liao YH, Chu SH, Hsiao GH, Chou NK, Wang SS, Chiu HC. Majocchi's granuloma caused by *Trichophyton tonsurans* in a cardiac transplant recipient. *Br J Dermatol* 1999; 140: 1194–1196.
7. Hadacek BM, Nassif A, Roux A, Desplaces N, Huerre M, De Bievre C, et al. *Trichophyton tonsurans* dermatophyte granuloma in an HIV-1 infected patient. *Br J Dermatol* 1999; 140: 749–782.
8. Roderick J. Dermatophytosis and other superficial mycosis. In: Mandell GL, Bennett JE, Dolin R, editors. *Mandell, Douglas and Bennett's principles and practice of infectious disease*. London: Churchill Livingstone, 1995: 2375–2386.
9. Jacobs PH. Majocchi's granuloma (due to therapy with steroid and occlusion). *Cutis* 1986; 38: 23.