

Mycosis Fungoides Restricted to the Palms: Efficacy of Methotrexate

Pierre-Dominique Ghislain¹, Isabelle Morant¹, Isabelle Alcaraz¹, Pierre de Beer¹, Colette Creusy² and Philippe Modiano¹
 Departments of ¹Dermatology and ²Pathology, Saint-Philibert Hospital, Catholic University of Lille, Centre Hospitalier Saint-Philibert, Service de Dermatologie, 115 rue du Grand But, F-59160 Lomme, France. E-mail: PierreDominique.Ghislain@advalvas.be
 Accepted September 4, 2002.

Sir,

We report a case of cutaneous T-cell lymphoma (mycosis fungoides) with palmar lesions only, resolved after treatment with methotrexate.

CASE REPORT

A 73-year-old patient was seen in 1995 for scaly hyperkeratotic plaques that had appeared 3 years previously on the palms, with lesions of dry pulpitis on 2 fingers (Fig 1). The plaques were well-defined and had a main diameter of 2–5 cm. Topical treatments (high-potency corticosteroids, emollients, keratolytic agents) made no significant improvement. Pruritus was moderate to severe. No other skin lesion was seen; the soles were not affected. The patient was not atopic and had never suffered from contact dermatitis; he took spironolactone for arterial hypertension and gliclazide for non-insulin-dependent diabetes. There was no personal or familial history of psoriasis or palmoplantar keratoderma. There was evidence of an old nicotinic intoxication (one pack a day for 42 years) that disappeared in 1981 when the patient stopped smoking.

The biopsy showed a hyperkeratotic epidermis, with acanthosis and hypertrophy of interpapillary ridges. A

lymphoid proliferation was observed in the superficial dermis, with exocytosis and beginning epidermotropism. Most of the lymphocytes had an irregular and cerebriform nucleus suggestive of Sézary cells. The bigger lymphoid cells had nuclei with nucleoli and showed an immunoblastic form. No Pautrier's pseudo-abscess was visible. Immunolabelling evidenced a proliferation of CD3(+) and CD4(+) T lymphocytes. The diagnosis of palmar mycosis fungoides was established. The patient was lost to follow-up. A second biopsy, performed 2 years later, produced the same images, with a larger number of large-sized cells. General examination was reassuring. The treatment included a betamethasone dipropionate ointment and a topical PUVA therapy. Since this protocol was too difficult for the patient, it was replaced by topical mechlorethamine. Again, the patient stopped this treatment after a few applications. New thorough investigations were carried out in 2000. The clinical aspect was identical to that of previous visits. The biopsy was similar to the first two biopsies, with a more perivascular lymphoid infiltrate (Figs 2 and 3). The majority (80%) of cells expressed CD3, CD2, CD5 and CD7 markers, and included small, medium and large cells, some of which showed a cerebriform nucleus. Some cells were also observed in the epidermis, but always isolated. Only a small percentage of cells were of the CD8(+) and T-cell intracellular antigen-1 (TiA-1)(+) types. The lymphoid infiltrate was accompanied by a Langerhans' cell hyperplasia and a macrophage hyperplasia. Haematopoietic marrow was normal (conventional histology and immunohistochemistry). General condition was good, without lymph nodes. The patient requested treatment, this time stating that he was determined to follow it. Oral methotrexate (7.5 mg once a week) gave complete

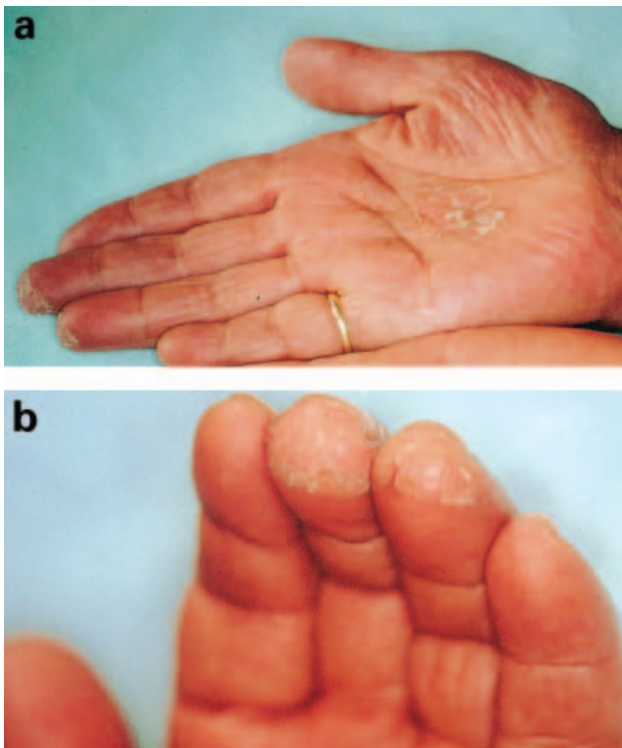


Fig. 1. Well-circumscribed hyperkeratotic plaque on the palm (a) and dry 'pulpitis' on the fingers (b).

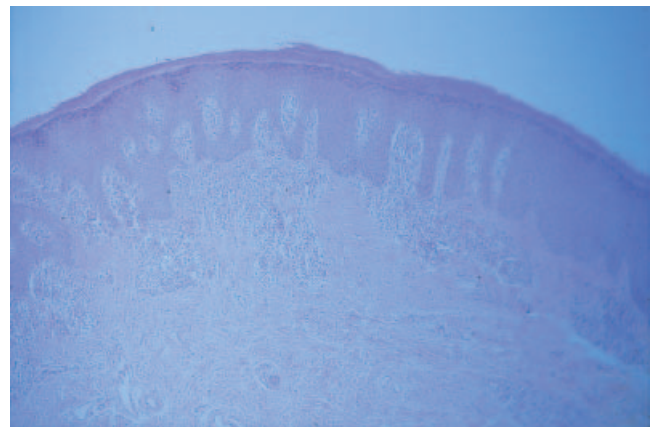


Fig. 2. Infiltrate of small lymphocytes with exocytosis (Haematoxylin-Eosin stain × 10).

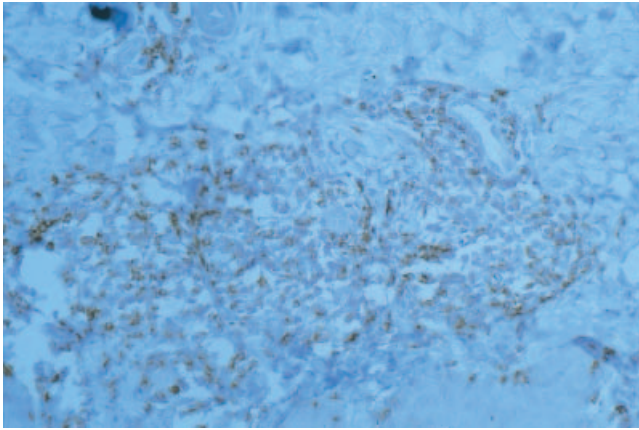


Fig. 3. Dense infiltrate of CD3-positive cells in dermis and epidermis (UCHL1 stain $\times 40$).

remission within a few weeks and without recurrence after 18 months. Methotrexate was continued at the same dose.

DISCUSSION

Palmoplantar keratoderma, observed in 11.5% of mycosis fungoides cases (1), is generally a secondary sign occurring together with plaques and nodules of the trunk and extremities. More rarely, in 0.6% of cases (1), clinical lesions are circumscribed to or prevail on the palms and soles, forming a so-called 'mycosis fungoides palmaris et plantaris' (MFPP). Stasko et al. (2) published the first observation of MFPP: a 45-year-old patient had presented with hyperkeratotic lesions of the palms, soles and palmar aspects of the fingers 6 months previously, with histological findings consistent with mycosis fungoides; Worringer-Kolopp disease was excluded clinically. Keratolytic treatments and topical corticosteroids were of little or no effect. The condition disappeared after treatment with mechlorethamine.

Resnik et al. (1) published a study with four new observations of MFPP and a review of the literature. Lesions were palmoplantar or only palmar, initially suggestive of common dermatoses. This condition developed very slowly. The diagnosis of cutaneous T-cell lymphoma was made via the histological examination, after a few months or years of evolution. There were no extracutaneous signs. There was no late generalization, but in some publications, the follow-up period was too short (3).

The differential diagnosis includes 'unilesional mycosis fungoides' (in which atypical lymphocytes and Pautrier's microabscesses are frequently absent (4)), pseudolymphomas (such as lymphomatoid contact dermatitis (5, 6)) and pagetoid reticulosis of Worringer-Kolopp (4, 7–10). The reasons for these distinctions are clinical and histological, although some authors try to integrate these pathologies in a single nosological entity (1, 11–16).

With regard to treatment, the literature has reported successes with topical or intralesional corticosteroids, mechlorethamine, PUVA therapy, electron therapy,

radiotherapy, laser CO₂, surgery of circumscribed lesions (14, 17). Salicylate ointments are sometimes added to the treatment.

ACKNOWLEDGEMENT

We express our sincere thanks to Pr. Diebold, and Dr. Molina, MD, for their assistance (Service Central d'Anatomie et de Cytologie Pathologiques, Hôtel-Dieu, Paris, France).

REFERENCES

1. Resnik KS, Kantor GR, Lessin SR, Kadin ME, Chooback L, Cooper HS, Vonderheid EC. Mycosis fungoides palmaris et plantaris. *Arch Dermatol* 1995; 131: 1052–1056.
2. Stasko T, Vander Ploeg DE, De Villez RL. Hyperkeratotic mycosis fungoides restricted to the palms. *J Am Acad Dermatol* 1982; 7: 792–796.
3. Hannah M, Jacyk WK. Palmoplantar hyperkeratotic plaques. Hyperkeratotic mycosis fungoides restricted to the palms and soles. *Arch Dermatol* 1998; 134: 1021–1024.
4. Cerroni L, Fink-Puches R, El Shabrawi-Caelen L, Soyer HP, LeBoit PE, Kerl H. Solitary skin lesions with histopathologic features of early mycosis fungoides. *Am J Dermatopathol* 1999; 21: 518–524.
5. Kossard S. Unilesional mycosis fungoides or lymphomatoid keratosis? *Arch Dermatol* 1997; 133: 1312–1313.
6. Verret JL, Rousselet MC, Peria P. Mycosis fungoide unilésionnel en plaque: 3 cas. *Ann Dermatol Venereol* 1997; 124: 527–530.
7. Evans LT, Mackey SL, Vidmar DA. An asymptomatic scaly plaque. Unilesional mycosis fungoides (MF). *Arch Dermatol* 1997; 133: 231–234.
8. Jones RR, Chu A. Pagetoid reticulosis and solitary mycosis fungoides. Distinct clinicopathological entities. *J Cutan Pathol* 1981; 8: 40–51.
9. Oliver GF, Winkelmann RK. Unilesional mycosis fungoides: a distinct entity. *J Am Acad Dermatol* 1989; 20: 63–70.
10. Haghighi B, Smoller BR, LeBoit PE, Warnke RA, Sander CA, Kohler S. Pagetoid reticulosis (Worringer-Kolopp disease): an immunophenotypic, molecular, and clinicopathologic study. *Mod Pathol* 2000; 13: 502–510.
11. Heald PW, Glusac EJ. Unilesional cutaneous T-cell lymphoma: clinical features, therapy, and follow-up of 10 patients with a treatment-responsive mycosis fungoides variant. *J Am Acad Dermatol* 2000; 42: 283–285.
12. Smoller BR. Mycosis fungoides palmaris et plantaris [letter; comment by Resnik KS]. *Arch Dermatol* 1996; 132: 468–469.
13. Smoller BR, Stewart M, Warnke R. A case of Worringer-Kolopp disease with Ki-1 (CD30) + cytotoxic/suppressor cells. *Arch Dermatol* 1992; 128: 526–529.
14. Goldberg DJ, Stampien TM, Schwartz RA. Mycosis fungoides palmaris et plantaris: successful treatment with the carbon dioxide laser. *Br J Dermatol* 1997; 136: 617–619.
15. Burns MK, Chan LS, Cooper KD. Worringer-Kolopp disease (localized pagetoid reticulosis) or unilesional mycosis fungoides? An analysis of eight cases with benign disease. *Arch Dermatol* 1995; 131: 325–329.
16. McNiff JM, Schechner JS, Crotty PL, Glusac EJ. Mycosis fungoides palmaris et plantaris or acral pagetoid reticulosis? *Am J Dermatopathol* 1998; 20: 271–275.
17. Sandwich JT, Davis LS. Mycosis fungoides palmaris et plantaris. *Arch Dermatol* 1996; 132: 971.