

## Areolar Sebaceous Hyperplasia

A. Krisp and W. Krause

Department of Andrology and Venerology Philipp-University Marburg, Deutschhausstr. 9, DE-35033 Marburg, Germany.

E-mail: krisp@mail.uni-marburg.de

Accepted September 2, 2002.

Sir,

Sebaceous hyperplasia is a common disorder of the face in adults, particularly men. The lesions, which are usually found on the forehead, cheeks and nose, consist of yellowish papules with central umbilication representing a widely dilated infundibular ostium (1). In 1985, Catalano & Ioannides (2) reported the case of a 37-year-old woman who noticed the development of extensive yellow plaques on both areolae shortly after giving birth. Histological examination showed normal-appearing sebaceous glands connected to multiple hairless short canals.

To our knowledge, only a few cases of this entity have been reported and there is only one case report of the appearance in male (3).

### CASE REPORT

A 52-year-old man presented with eczema of both nipples lasting for over 2 years (Fig. 1). His medical history was uneventful, apart from an arterial hypertension. Physical examination revealed an asymptomatic yellowish thickening of both areolae, which showed a papillated surface raised above the surrounding skin (Fig. 1). The lesions were asymptomatic and were first

mentioned 2 years previously. No lesions suspected as being sebaceous hyperplasia were present on his face, while the remainder of his physical examination was within normal limits. In a clinical diagnosis of superficial sebaceous hyperplasia of the areolae, there were no pathological findings in clinical chemistry, including the endocrinological parameters.

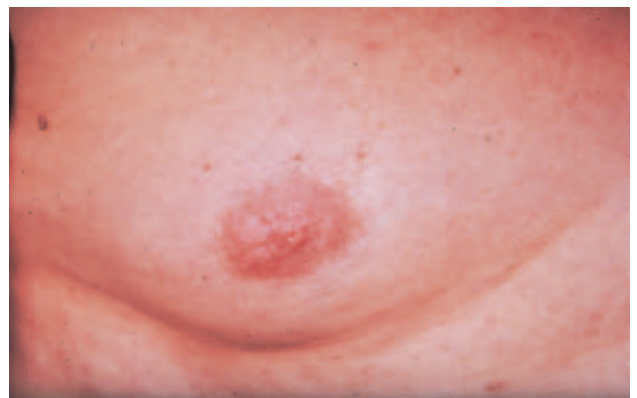

Fig. 1. Areolar sebaceous hyperplasia with the clinical appearance of yellowish thickened papules and plaques.

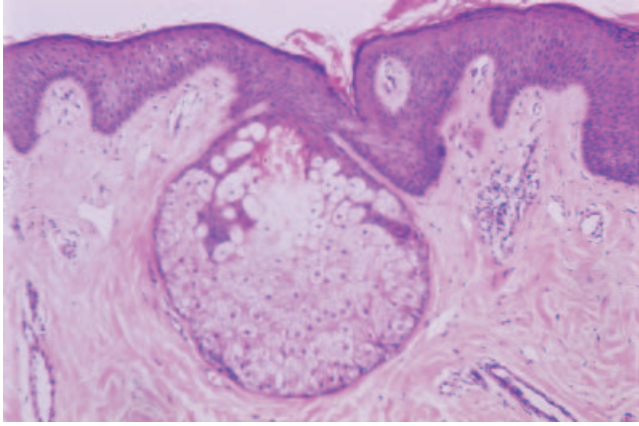


Fig. 2. Histopathological examination reveals a fully differentiated sebaceous gland with lobules closely arranged in a band-like pattern directly connected with the skin surface through short infundibula

A biopsy was performed from the periphery of the right areola. Histopathological examination demonstrated multiple large sebaceous glands in the upper dermis. (Fig. 2).

## DISCUSSION

Sebaceous glands occur over much of the body. They are not normally found on the palms or soles, however, and are sparse on the dorsa of the hands and feet. They are largest and most numerous on the forehead and face, the mid-line of the back, the external auditory meatus and the anogenital region. In a number of sites, sebaceous glands open directly on the surface of the skin, and not via a hair follicle; for example, the Meibohmian glands of the eyelids and Tyson's glands of the prepuce. Similar 'free' sebaceous glands are found on the mucocutaneous surfaces of the female and male genitalia, and as Fordyce spots on the vermilion of the lips and bucal mucosa. Less commonly, ectopic sebaceous glands occur in sites such as the tongue, cervix uteri and parotid gland (4).

Focal sebaceous hyperplasia is a common entity that occurs on the face and, occasionally, the neck of middle-aged and older persons. Clinically, these lesions occur as one or more yellowish, umbilicate papule that correlate to the histopathological findings consisting of one or more enlarged mature sebaceous glands grouped around a central wide sebaceous duct (5).

In the areola, sebaceous glands occur as Montgomery's tubercles. This is true at least in the female, while

according to Steffen & Ackermann (6) males lack Montgomery tubercles.

The existence of sebaceous glands especially at the tip of the nipple was demonstrated by Perkins & Miller (7). Catalano & Ioannides, who first reported the areolar sebaceous hyperplasia in a women, described the lesions as consisting microscopically of compactly and closely arranged large lobules of normal appearing sebaceous glands which are directly connected to the skin surface through short infundibula. In the following years the occurrence of areolar sebaceous hyperplasia was mainly reported in women. The only case report of the entity occurring in a male was published by Farina et al. in 1996 (3). These authors state that areolar sebaceous hyperplasia may represent hyperplasia of Montgomery tubercles. Since men lack Montgomery tubercles, areolar sebaceous hyperplasia in the male might be better interpreted as a malformation than as a hamarthoma, a hyperplasia or an adenoma (6).

As areolar sebaceous hyperplasia is a rare entity, one should consider the occurrence of a nipple eczema, acanthosis nigricans (8), hyperkeratosis and papillomatosis of the nipple (9) for differential diagnosis.

## REFERENCES

1. Braun-Falco O, Thianpravit M. Über die circumskripte senile Talgdrüsenhyperplasie. *Arch Clin Exp Dermatol* 1965; 221: 207–231.
2. Catalano PM, Ioannides G. Areolar sebaceous hyperplasia. *J Am Acad Dermatol* 1985; 13: 867–868.
3. Farina MC, Soriano ML, Escalonilla P, Pique E, Martin L, Barat A, et al. Unilateral areolar sebaceous hyperplasia in a male. *Am J Dermatopathol* 1996; 18: 417–419.
4. Hyman AB, Guidicci AA. Ectopic sebaceous glands. In: Montagna W, et al., editors. *Advances in biology of the skin*, vol. 4. Oxford: Pergamon, 1963: 78–93.
5. Prioleau PG, Santa Cruz DJ. Sebaceous gland neoplasia. *J Cutan Pathol* 1984; 11: 396.
6. Steffen C, Ackerman AB. Fordyce's spots and Montgomery's tubercles. In: *Neoplasms with sebaceous differentiation*. Philadelphia: Lea & Febinger, 1994: 71–86.
7. Perkins OC, Miller AM. Sebaceous glands in the human nipple. *Am J Obstet Gynecol* 1926; 11: 789–794.
8. Forman L. Acanthosis nigricans with discrete warts and marked mucous membrane changes in a patient with vitiligo. *Proc R Soc Med* 1943; 36: 611.
9. Kuhlmann DS, Hodge SJ, Owen LG. Hyperkeratosis of the nipple and the areola. *J Am Acad Dermatol* 1985; 13: 596–598.