

Perineurioma: A Tendon Sheath Fibroma-like Variant in a Distal Subungual Location

Robert Baran and Christophe Perrin

Nail Disease Centre, 42, rue des Serbes, FR-06400 Cannes, France and Department of Dermatopathology, Hôpital Pasteur, Voie Romaine, Nice, France. E-mail: baran.r@club-internet.fr
Accepted September 2, 2002.

Sir,

In recent years, a number of new entities of neural tumours have been described and advances in immunohistochemistry and electron microscopy have improved our understanding of the cytological differentiation of these neoplasms (1).

CASE REPORT

A 59-year-old woman presented with a growth involving the hyponychium, the distal groove and the area distal to the groove in the ulnar portion of the left index finger. This red, pea-size nodule was round and well demarcated (Fig. 1).

The past history indicated that the tumour had first appeared 9 years previously. It had been cauterized by a dermatologist, probably using electrocautery. The tumour recurred after about one year and was treated in the same manner. However, it recurred and began to increase progressively and more rapidly than in the previous 2 years.

It was not tender to light pressure but was painful after trauma to the lesion. X-ray was normal, there was no other abnormality and the patient was in good health. After a ring block anaesthesia, the distal third of the nail plate was removed, the tumour was excised using a transverse fusiform incision down to the bone, then sutured. Healing was uneventful. The histology specimen demonstrated a polypoid formation.

The lesion has circumscribed multinodular outlines and an array of split-like spaces (Fig. 2). Some areas are cellular with small, epithelioid or short plump

spindle cells in a storiform growth pattern. The stroma is composed of variably abundant collagen with focal hyalinization and dilated vascular channels.

The mitotic index is low, with neither abnormal mitoses nor necrosis. The vascular network is pronounced. Immunohistochemistry shows negativity for protein S 100, HMB 45, total cytokeratin, Kp1, actin and CD 34. Conversely, vimentin is diffusely expressed and epithelial membrane antigen (EMA) is expressed on 80% of the spindle shaped-cells (Fig. 3). At several sites, the lateral and deep limits of the lesion are not delineated by normal tissue. Further recurrence may therefore be anticipated.

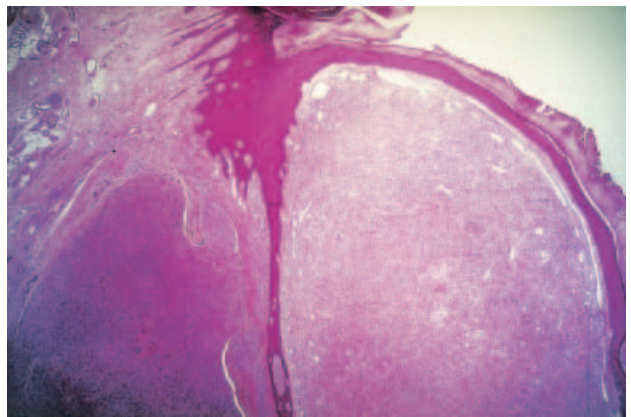


Fig. 2. Polypoid formation of the tumour. Note superficially dilated vascular channels and, in deep situations split-like spaces, a fixation artifact: two features commonly seen in fibroma of the tendon sheath $\times 16$.

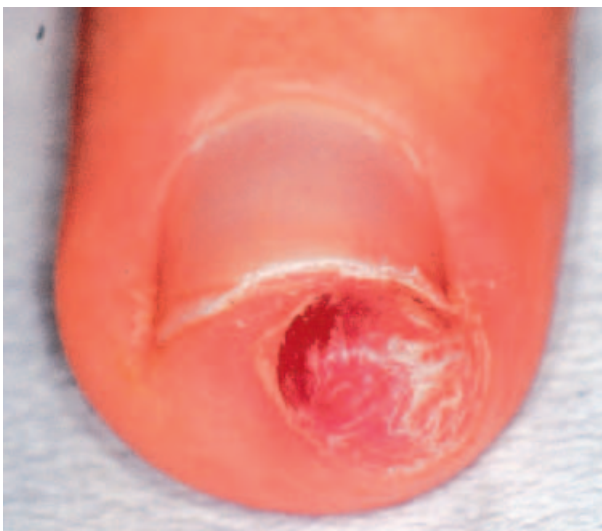

Fig. 1. Red, pea-size nodule.

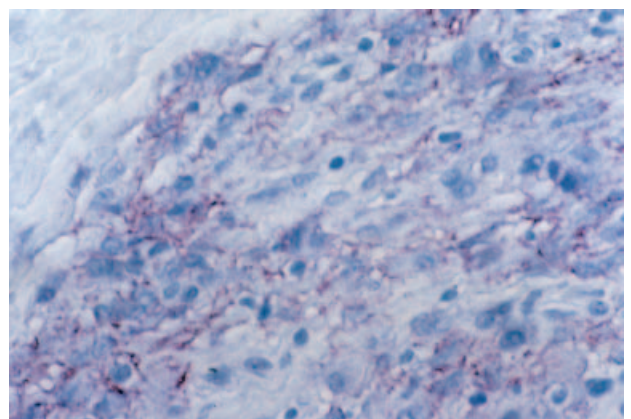


Fig. 3. Epithelial membrane antigen expressed on 80% of the spindle-shaped cells.

DISCUSSION

Immunohistochemical findings indicate that benign peripheral nerve sheath tumours should be placed in at least three categories: schwannoma, neurofibroma and perineurioma (1–3). Soft tissue perineurioma is a rare tumour of nerve sheath derivation, uncommonly found in the nail area (4). It is a benign peripheral nerve sheath neoplasm composed of cells that stain positively for EMA but fail to stain for S-100 protein and neurofilaments.

These tumours classically present as a well-margined subcutaneous or deep-seated soft tissue mass. The cells are generally elongated and form lamellae or whorls interspersed between collagen bundles. Encirclement of collagen bundles by elongated cell processes is a characteristic feature. Two distinct variants within this group have been recognized with a predilection for the hand: (A) Fibrous perineurioma (2) containing both plump and slender elongated spindle cells and more abundant stroma. (B) Reticular perineurioma (3) with a lace-like or reticular growth pattern composed of anastomosing cords of fusiform cells in a variably collagenous to myxoid stroma. A related variant entitled “sclerosing perineurioma” shows a small and heavily collagenized dermal nodule with the features of reticular perineurioma (5). However, these new variants have not been described hitherto in the nail area.

Our case expands both the clinical and histopathologic

spectrum of perineurioma. The superficial location with a polypoid appearance has not so far been observed. Histologically, the tumour is lobulated with narrow cleft-like spaces dividing the lobules, an architecture reminiscent of fibroma of the tendon sheath but not reported in perineurioma, particularly in its fibrous variant; however, the lack of immunoreactivity for smooth muscle actin and the expression of EMA rule out the diagnosis of fibroma of the tendon sheath in our case.

REFERENCES

1. Mentzel T, Die Tos AP, Fletcher CD. Perineurioma (storiform perineurial fibroma): clinico-pathological analysis of four cases. *Histopathology* 1994; 25: 261–267.
2. Skelton HG, Williams J, Smith KJ. The clinical and histologic spectrum of cutaneous fibrous perineuriomas. *Am J Dermatol Pathol* 2001; 23: 190–196.
3. Graadt van Roggen JF, McMenamin ME, Belchis DA, Rosenberg AE, Fletcher CDM. Reticular perineurioma. A distinctive variant of soft tissue perineurioma. *Am J Surg Pathol* 2001; 25: 485–493.
4. Baran R, Perrin Ch. Subungual perineurioma. A peculiar location. *Br J Dermatol* 2002; 146: 125–128.
5. Fetsch JF, Miettinen M. Sclerosing perineurioma. A clinicopathologic study of 19 cases of a distinctive soft tissue lesion with a predilection for the fingers and palms of young adults. *Am J Surg Pathol* 1997; 21: 1433–1442.