

## Erythema ab igne Caused by Frequent Hot Bathing

Sung-Jan Lin, Chih-Jung Hsu and Hsien-Ching Chiu

Department of Dermatology, National Taiwan University Hospital and National Taiwan University College of Medicine, No. 7, Chung-Shan S. Rd., Taipei, Taiwan, 10016.

E-mail: hcc@ha.mc.ntu.edu.tw

Accepted July 23, 2002.

Sir,

Erythema ab igne is an uncommon skin lesion caused by chronic exposure to infrared or moderate heat (1, 2). It is usually induced by thermal irradiation from a hearth, brazier, open fire, hot bottle or heating pad. Erythema ab igne caused by hot bathing has never been reported. Here, we report a case of erythema ab igne with an unusual distribution caused by frequent hot bathing.

### CASE REPORT

An 18-year-old woman, a high school student, had had asymptomatic hyperpigmented lesions on her feet, lower legs, upper thighs and buttocks for 3 months. She was otherwise healthy and was not on medication. She did not apply lotions or medicaments to her skin. She also denied applying hot bottles, heating pads or heating blankets to her skin or using other external heating devices. Physical examination revealed symmetrically distributed reticular hyperpigmentation on a faint erythematous background spanning from the buttocks down to the mid-thighs and from the mid-lower legs down to the feet with sparing of the knees and the surrounding skin (Fig. 1). On further questioning, she reported having started

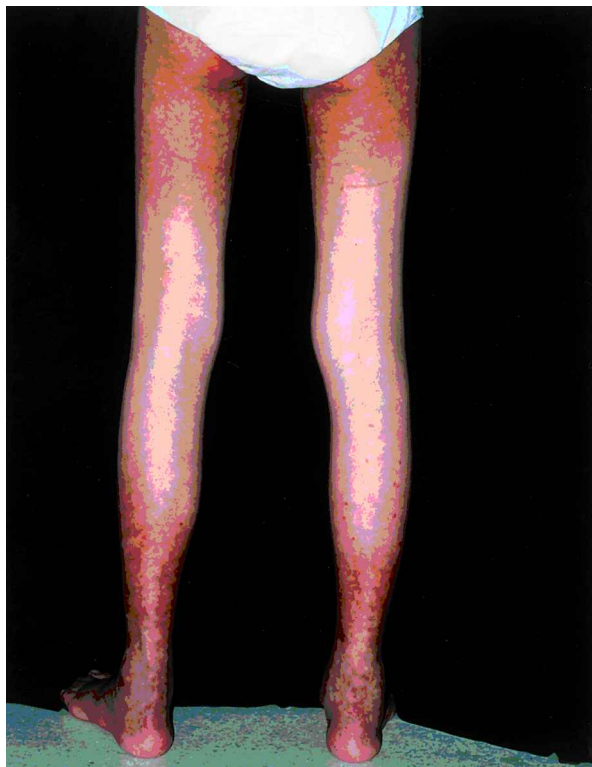


Fig. 1. Reticular hyperpigmentation over the buttocks, upper thighs, lower legs and feet.

to take a hot bath for 60 to 90 min in a bathtub nightly 6 months previously. The bathtub was not deep, so her knees and chest remained above the water when she was bathing, and distribution of the skin lesions corresponded to the areas that were immersed in the water. Skin biopsy specimens were taken from a lesion on her left buttock and left ankle. The microscopic findings of the two specimens were similar, showing hyperkeratosis, epidermal thinning with loss of rete ridges, basal hyperpigmentation and dermal oedema. Slight pigment incontinence and a mild superficial perivascular lymphocytic infiltrate were also revealed. Stain for elastin showed an increased amount of elastic fibres in the upper and middle dermis. Based on the clinical manifestations and microscopic findings, a diagnosis of erythema ab igne was made. The patient was instructed not to take hot baths. Her skin lesions gradually faded during the following months.

### DISCUSSION

Erythema ab igne is a well-known adverse effect of repeated heat exposure. In the past, it has usually been seen on the inner aspects of the thighs and lower legs of women who sit in front of open fires, fireplaces or furnaces. Since the introduction of central heating, it has become rare, but it can still be seen in people who use hot-water bottles or heating pads for pain relief. Skin lesions may not appear for 3 weeks after the start of exposure to heat (3). When the lesion first appears, it may fade if not then submitted to heat exposure, but will tend to persist after prolonged exposure to heat (3). Furniture-induced erythema ab igne has been reported in people who used a therapeutic chair with a built-in heating unit (4). Besides, erythema ab igne developing on unusual areas may be a clue to internal disease or internal malignancy (5, 6).

Though taking a hot bath is not an uncommon habit, there has been no report of erythema ab igne developing on people habituated to hot bathing. Our patient had taken a 60 to 90-min hot bath nightly for 6 months. This length of time and frequency of hot bathing is unusual.

Erythema ab igne is believed to carry a slightly increased risk of malignant transformation (1, 4, 7), especially when hydrocarbons are the source of heat (4). However, there has been no report of malignancy developing on erythema ab igne caused by a warm bottle or hot pad. In addition to inducing erythema ab igne, infrared radiation may contribute to premature aging and enhance the carcinogenic effects of ultraviolet radiation (8). While a hot bath is both refreshing and relaxing, it may be harmful to our skin if taken too frequently.

### REFERENCES

1. Page EH, Shear NH. Temperature-dependent skin disorders. *J Am Acad Dermatol* 1988; 18: 1003–1019.
2. Baruchin AM. Erythema ab igne: a neglected entity? *Burns* 1994; 20: 460–462.

3. Galvin SA, Buchness MR. Rectangular reticulate patches on the pretibial areas. Erythema ab igne. *Arch Dermatol* 1990; 126: 386–387.
4. Meffert JJ, Davis BM. Furniture-induced erythema ab igne. *J Am Acad Dermatol* 1996; 34: 516–517.
5. Butler ML. Erythema ab igne, a sign of pancreatic disease. *Am J Gastroenterol* 1977; 67: 77–79.
6. Ashby M. Erythema ab igne in cancer patients. *J R Soc Med* 1985; 78: 925–927.
7. Arrington JH 3rd, Lockman DS. Thermal keratoses and squamous cell carcinoma in situ associated with erythema ab igne. *Arch Dermatol* 1979; 115: 1226–1228.
8. Kligman LH, Kligman AM. Reflections on heat. *Br J Dermatol* 1984; 110: 369–375.

## An Unusual Manifestation of Linear Atrophoderma of Moulin

Ljubka Miteva and E. Obreshkova

Department of Dermatology and Venereology, Medical University, Zdrave 2 str., BG-1431 Sofia, Bulgaria.

E-mail: mitev@ns.medfac.acad.bg

Accepted July 18, 2002.

Sir,

Moulin et al. (1) first described linear atrophoderma in 1992 and differentiated this uncommon condition from other linear dermatoses. Clinically, it is present as pigmented and atrophic bands or lines that follow Blaschko's lines exactly, with no preceding inflammation or subsequent induration or scleroderma.

To date, 11 cases of linear atrophoderma of Moulin (LAM) have been reported in the literature (1–7). Here, we present a woman with two types of skin lesions: linear atrophic lesions on the right arm and on the left mandibular region along with atrophic areas and telangiectatic macules in linear arrangement following the course of Blaschko's lines on the right buttock and leg.

The expression of the disease in our case does not conform exactly to any of the reported cases with classic cutaneous manifestations characteristic for LAM.

### CASE REPORT

A 20-year-old woman presented with a 4-year history of asymptomatic, unilateral linear skin lesions following the appearance of Blaschko's lines on the arms and legs and on the face. Her medical and family history was unremarkable. The disease had a chronic course without progression or regression.

Physical examination revealed two types of skin lesions: hypopigmented, atrophic, slightly depressed linear lesions on the medial aspect of the right arm, from the axilla to the wrist and on the left mandibular region, and 1-cm wide atrophic band-like lesions along with multiple telangiectatic macules following Blaschko's lines on the right buttock and leg (Fig. 1).

Laboratory findings, including a complete blood count, urinalysis and liver function test, were normal. Complete ophthalmologic, odontologic and radiologic surveys revealed no abnormalities.

A skin biopsy taken from the atrophic lesion with telangiectasias on the right leg revealed moderate psoriasiform epidermal hyperplasia with hyaline eosinophilic bodies in the

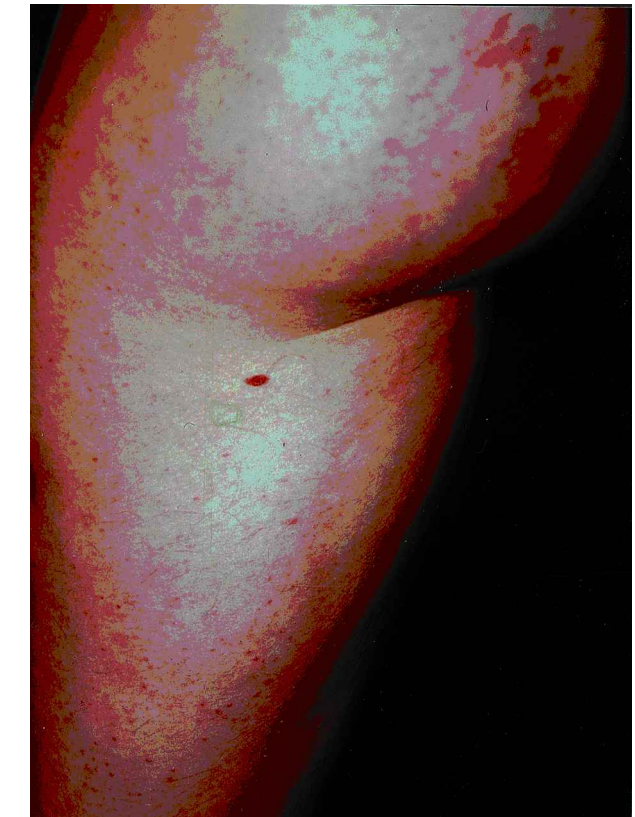

Fig. 1. Linear atrophic telangiectatic lesions on the right buttock and leg. The pattern is consistent with Blaschko's lines.

spinous layer; oedema and dilated small blood vessels in the papillary dermis, some with hyalinization; scant inflammatory infiltrate of lymphocytes and plasma cells and some hyalinization of the collagen in the upper dermis. The elastic tissue is diminished (Fig. 2). These histologic features were considered to be compatible with the diagnosis of LAM.