

## Successful Treatment of Vulvar Intraepithelial Neoplasia with Topical Imiquimod 5% Cream in a Lung Transplanted Patient

Lisa B. Travis<sup>1</sup>, Jeffrey M. Weinberg<sup>1</sup> and Burtin A. Krumholz<sup>2</sup>

<sup>1</sup>Department of Dermatology, St. Luke's-Roosevelt and Beth Israel Medical Centers, 1090 Amsterdam Avenue, Suite 11D New York, NY 10025 and <sup>2</sup>Department of Obstetrics-Gynecology, Long Island Jewish Medical Center, Lake Success, NY, USA. E-mail: jmw27@columbia.edu

Accepted June 18, 2002.

Sir,

Imiquimod, an immune response modifier, has been successful in the treatment of external genital and perianal warts caused by low-risk HPV, usually types 6 or 11 (1). The drug's antiviral and antitumour properties are thought to be due to its induction of cytokines, which stimulate a T-helper 1 or cell-mediated immune response. Recently, it has been shown that imiquimod may potentially be effective in treating genital intraepithelial neoplasia caused by high-grade HPV (2, 3). We report the case of a 27-year-old woman who presented with recurrent genital warts and later found to have cervical intraepithelial neoplasia (CIN) 2 and vulvar intraepithelial neoplasia (VIN) 3. Two separate courses of topical imiquimod cream 5% were used with clearing of the lesions. Topical imiquimod cream 5% may therefore be an effective medical treatment for genital intraepithelial neoplasia.

### CASE REPORT

A 27-year-old white female presented with recurrent genital warts. Her past gynaecological history included genital warts and biopsy proven CIN 2, which recurred after laser ablation of the cervix, vagina and vulva. Past medical history included cystic fibrosis with multiple hospitalizations between 1984 and 1994 for pulmonary and respiratory complications. A bilateral lung transplant was performed at age 23.

During the first visit, multiple hyperkeratotic and macular, pigmented wart-like lesions of the vulva, mons pubis and labia were seen bilaterally. Colposcopic examination revealed focal grade 1–2 acetowhite lesions determined to be CIN 2 on biopsy. A hybrid capture HPV DNA reported high-risk and low-risk HPV. Treatment with topical imiquimod cream 5% applied every other day was started to the cervix and vulvar area, before receiving the cervical biopsy results. The patient felt the cream was not working and discontinued its use after 3 months. Six months later, examination revealed no decrease of the vulvar lesions but a new, diffuse papular eruption in addition, similar in appearance to Bowenoid papulosis. Colposcopy demonstrated that the initial cervical lesions were almost completely resolved.

During the next 3 months the patient did not use any treatment on the vulva. Another pap smear revealed mild dysplasia with parakeratotic changes. On repeat colposcopy the cervical lesions were gone but the vulvar lesions were more extensive with increased pigmentation and a more Bowenoid appearance

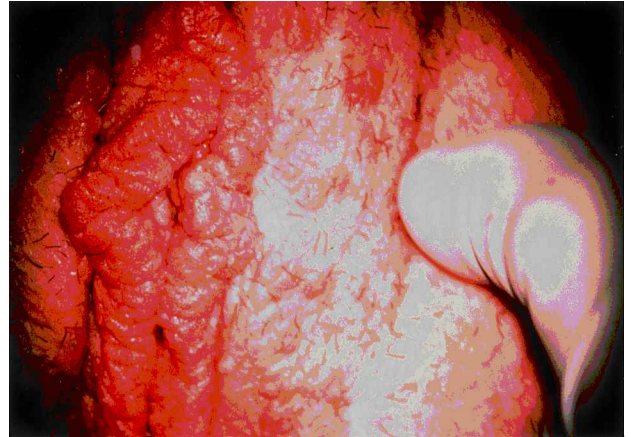


Fig. 1. Verrucous lesions of vulva prior to therapy.

(Fig. 1). A biopsy taken from the right anterior labium majus detected VIN 3.

The available treatments, including simple vulvectomy, were discussed with the patient and a gynaecologist-oncologist was consulted. A second course of imiquimod cream was decided upon. The patient was found to have almost total resolution of the previously noted lesions after using imiquimod for 4 months, during which time she applied the cream three times per week for 2 weeks, stopped for 2 weeks, and then repeated the application. She did have one perianal wart on examination.

She continued to use the imiquimod for another 4 months, at which time she was hospitalized for "rejection" of her transplant. She remained in the hospital for 2 months and received high-dose steroid therapy. A normal papular smear was obtained with no evidence of VIN two months later. At this time, a single wart was observed on the right labium minus. The patient was not seen after this visit.

### DISCUSSION

VIN had initially been classified into non-neoplastic and neoplastic disorders, and then subsequently into viral and non-viral aetiologies (3). Viral VIN is typically seen in younger patients with HPV infection who often display multifocal, warty lesions. Although there is overlap, HPV types 6 and 11 cause most of the apparent condylomas; types 16 and 18 cause most of the subclinical and latent infections and are the viral types most closely associated with neoplasia (4).

Over the past 20 years, the detection rate of viral VIN has doubled. Its multifocal presentation coupled

with the risk of malignancy makes treatment of this disease challenging (5). Since there is no one highly effective treatment for HPV disease, therapies exist that target different components of its pathophysiology, including the virus, the lesion and the immune system.

Both surgical and laser procedures have been associated with pain, bleeding and scarring (2, 5). Cervical stenosis or incompetence have also been noted afterwards, although these side effects are uncommon (2). Recurrence rates for these therapies have been as high as 57%. Other researched treatments not shown to be successful include topical 5-fluorouracil, injected interferon, topical interferon and combined isotretinoin and interferon-alpha (3).

Recent studies have demonstrated the role the immune system plays in HPV disease regression. The cell-mediated immune response (CMI) is believed to play an important role in suppressing the progression of the virus, since HIV-positive patients and transplant recipients have an increased incidence of HPV infection and genital warts (1). Although the immune system's recognition of the virus has been described as inadequate, a significantly higher amount of CD4-positive activated memory lymphocytes has been shown in the epidermis and dermis of spontaneously regressing genital warts as compared to non-regressing lesions (4).

Imiquimod cream 5% has been shown to be a safe and effective treatment for external genital and perianal warts caused by low-risk types of HPV, usually 6 and 11, although it has limitations. In a recent study, complete clinical clearance was observed in 451/943 (47.8%) patients (intent-to-treat (ITT) analysis) during the initial treatment period, with clearance in an additional 52 (5.5%) patients during the extended treatment period beyond 16 weeks (6). The overall clearance rate for the combined treatment periods was 53.3%. The sustained clearance rates (patients who cleared during treatment and remained clear at the end of the follow-up period) after 3 and 6 months were 41.6% and 33.0%, respectively (6).

Imiquimod has demonstrated immunomodulating, antiviral and antitumour activities in animal studies (4). Its acute antiviral and antitumour activity in animals is thought to be due to production of cytokines and the subsequent activation of the immune response (1). Arany et al. (1) demonstrated elevated levels of mRNA for IFN-gamma and CD4<sup>+</sup> Th cells, both important to the CMI, after treatment with imiquimod. This supports the hypothesis that imiquimod's enhancement of the immune response, through cytokine production, is responsible for its antiviral and antitumour properties (1).

Building on imiquimod's effectiveness in the treatment of genital warts, interest has developed to study this drug's ability to treat patients with high-grade vulvar, vaginal and cervical intraepithelial neoplasia (2). Diaz-Arrastia et al. (2) treated eight patients with

genital intraepithelial neoplasia, who had failed previous standard therapies, with topical imiquimod 5%. Included in these eight cases were two patients with cervical dysplasia, two with vaginal dysplasia and four with vulvar dysplasia. These authors found six patients to be responsive, both partially and completely, to treatment. Three patients had recurrences but all were retreated with success using the 5% imiquimod (2).

Davis et al. (3) demonstrated imiquimod to be effective in four cases of documented VIN 3. The authors' post-treatment biopsies of affected areas showed no evidence of VIN 3 or HPV infection. One patient had a recurrence one month after complete resolution, but was successfully treated again with reapplication. This patient was free of disease at one year. The protocol's use of imiquimod only until the lesions cleared, unlike condyloma studies which extend treatment, may be the reason for the early recurrence (3).

We found topical imiquimod 5% cream to be effective in treating both clinical vulvar warts and sub-clinical colposcopically identified CIN 2 and VIN 3 lesions in our patient. The treatment was well tolerated, and no significant side effects were noted. The beneficial results we have shown using imiquimod add to the growing evidence that this drug can be beneficial for genital intraepithelial neoplasia and highlights the need for further investigation in this area.

## REFERENCES

1. Arany I, Tyring SK, Brysk MM, Stanley MA, Tomai MA, Miller RL, et al. Correlation between pretreatment levels of interferon response genes and clinical responses to an immune response modifier (Imiquimod) in genital warts. *Antimicrob Agents Chemother* 2000; 44: 1869–1873.
2. Diaz-Arrastia C, Arany I, Robazetti SC, Dinh TV, Gatalica Z, Tyring SK, et al. Clinical and molecular responses in high-grade intraepithelial neoplasia treated with topical imiquimod 5%. *Clin Cancer Res* 2001; 7: 3031–3033.
3. Davis G, Wentworth J, Richard J. Self-administered topical imiquimod treatment of vulvar intraepithelial neoplasia. A report of four cases. *J Reprod Med* 2000; 45: 619–623.
4. Lacey CJ, Fairley I. Medical therapy of genital human papilloma virus-related disease. *Int J STD AIDS* 1995; 6: 399–407.
5. Abdel-Hady ES, Martin-Hirsch P, Duggan-Keen M, Stern PL, Moore JV, Corbitt G, et al. Immunological and viral factors associated with the response of vulvar intraepithelial neoplasia to photodynamic therapy. *Cancer Res* 2001; 61: 192–196.
6. Garland SM, Sellors JW, Wikstrom A, Petersen CS, Aranda C, Aractingi S, et al. Imiquimod Study Group. Imiquimod 5% cream is a safe and effective self-applied treatment for anogenital warts: results of an open-label, multicentre Phase IIIB trial. *Int J STD AIDS* 2001; 12: 722–729.