

received oral treatment. It is of interest that patients diagnosed with onychomycosis were only offered oral treatment in 50% of the cases.

#### ACKNOWLEDGEMENTS

This study was supported financially by the Icelandic Ministry of Health, Janssen Pharmaceutical Company and Novartis (at that time Sandoz).

#### REFERENCES

1. Evans EG, Sigurgeirsson B. Double-blind, randomised study of continuous terbinafine compared with intermittent itraconazole in treatment of toenail onychomycosis. *BMJ* 1999; 318: 1031–1035.
2. Roberts DT. Prevalence of dermatophyte onychomycosis in the United Kingdom: results of an omnibus survey. *Br J Dermatol* 1992; 126 Suppl 39: 23–27.
3. Heikkilä H, Stubb S. The prevalence of onychomycosis in Finland. *Br J Dermatol* 1995; 133: 699–703.
4. Gupta AK, Lynde CW, Jain HC, Sibbald RG, Elewski BE, Daniel CR, 3rd, et al. A higher prevalence of onychomycosis in psoriasis compared with non-psoriasis: a multicentre study. *Br J Dermatol* 1997; 136: 786–789.
5. Gupta AK, Konnikov N, MacDonald P, Rich P, Rodger NW, Edmonds MW, et al. Prevalence and epidemiology of toenail onychomycosis in diabetic subjects: a multicentre survey. *Br J Dermatol* 2000; 139: 665–671.
6. Gudnadottir G, Hilmarsdottir I, Sigurgeirsson B. Onychomycosis in Icelandic swimmers. *Acta Derm Venereol* 1999; 79: 376–377.
7. Levy LA. Epidemiology of onychomycosis in special-risk populations. *J Am Podiatr Med Assoc* 1997; 87: 546–550.
8. Sais G, Jucgla A, Peyri J. Prevalence of dermatophyte onychomycosis in Spain: a cross-sectional study. *Br J Dermatol* 1995; 132: 758–761.
9. Sigurgeirsson B, Billstein S, Rantanen T, Ruzicka T, di Fonzo E, Vermeer BJ, et al. L.I.ON. Study: efficacy and tolerability of continuous terbinafine (Lamisil) compared to intermittent itraconazole in the treatment of toenail onychomycosis. Lamisil vs. itraconazole in onychomycosis. *Br J Dermatol* 1999; 141 Suppl. 56: 5–14.
10. Hull PR, Gupta AK, Summerbell RC. Onychomycosis: an evaluation of three sampling methods. *J Am Acad Dermatol* 2000; 39: 1015–1017.
11. Hilmarsdottir I, Haraldsson H, Sigurdardóttir A, Sigurgeirsson B. Dermatophyte contamination in an Icelandic swimming pool (poster). *Societe Francaise de mycologie medicale*, 1998.
12. Watanabe K, Taniguchi H, Katoh T. Adhesion of dermatophytes to healthy feet and its simple treatment. *Mycoses* 2000; 43: 45–50.
13. Kamihama T, Kimura T, Hosokawa JI, Ueji M, Takase T, Tagami K. Tinea pedis outbreak in swimming pools in Japan. *Public Health* 1997; 111: 249–253.
14. Zaias N, Tosti A, Rebell G, Morelli R, Bardazzi F, Bielely H, et al. Autosomal dominant pattern of distal subungual onychomycosis caused by *Trichophyton rubrum*. *J Am Acad Dermatol* 1996; 34: 302–304.
15. Cribier B, Mena ML, Rey D, Partisani M, Fabien V, Lang JM, et al. Nail changes in patients infected with human immunodeficiency virus. A prospective controlled study. *Arch Dermatol* 2000; 134: 1216–1220.

---

## Leishmaniasis of the Lip

Stefano Veraldi, Corinna Rigoni and Raffaele Gianotti

*Institute of Dermatological Sciences, I.R.C.C.S., University of Milan, Via Pace 9, 20122 Milan, Italy. E-mail: stefano.veraldi@libero.it*

*Accepted June 20, 2002.*

Sir,

Leishmaniasis of the lips occurs mainly in young subjects (1–6). It is characterized clinically by the slow and progressive enlargement of one or both lips: macrocheilia is the final appearance (1–3, 5, 7). A nodule often present within the swelling undergoes an ulceration which may be covered by a crust (1, 2, 4–6). Bacterial superinfection is possible (5). The consistency of the entire lesion is parenchymatous-hard (2, 7). The swelling is often painful (4, 5). Patients with leishmaniasis of the lips are in good general health (1–3, 6); in particular, regional lymph nodes are never involved (1, 5–7). We present a rare case of cutaneous leishmaniasis on the lower lip in an Italian patient.

#### CASE REPORT

A 71-year-old man was admitted to our Institute because of swelling of the lower lip. The patient stated that he was in good general health and that he was not taking any medication. He also stated that the swelling had appeared approximately one year previously and that it had slowly enlarged to the current morphology and size. Two biopsies had previously been carried out at other hospitals, and in both cases a histopathological diagnosis of macrocheilitis was made. The patient was not treated.

Dermatological examination showed the presence of a swelling that involved the entire lower lip. The surface

of the swelling was irregular; an oval ulcer localized on the right side of the lip was also present. The colour of the swelling ranged from pink to red (Fig. 1a). Consistency was parenchymatous-hard. The patient complained of pain. General physical examination did not show anything pathological; in particular, regional lymph nodes were not involved.

Laboratory and instrumental examinations were within normal ranges or negative. The patient was subjected to a new biopsy. A histopathological diagnosis of leishmaniasis was made (Fig. 2): this diagnosis was surprising, because the patient lived in Carrara (Tuscany, Mid-Western Italy), an area which is not endemic for leishmaniasis; moreover, the patient never travelled outside Italy. Cultural examination on

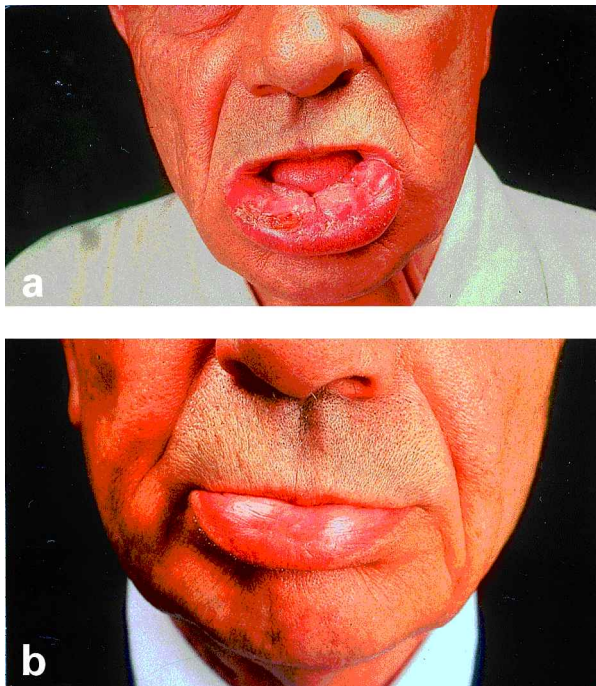


Fig. 1. Swelling involving the entire lower lip before (a) and 1 month after therapy (b).

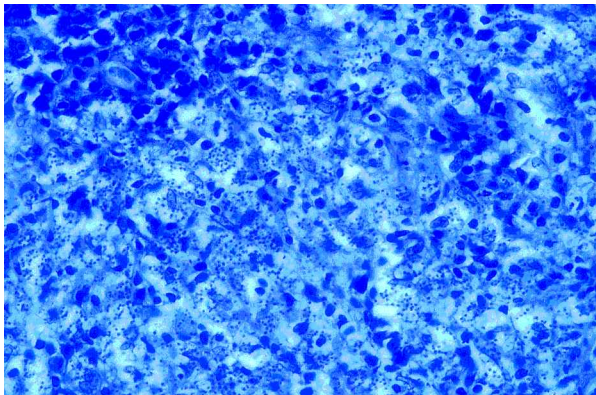


Fig. 2. Diffuse histiocytic infiltrate; most of the cells contain typical *Leishmania* spp. bodies (Giemsa; original magnification  $\times 40$ ).

Novy-MacNeal-Nicolle medium was positive for *Leishmania infantum*.

The patient was treated with i.m. N-methylglucamine antimonate ( $100 \text{ mg kg}^{-1} \text{ day}^{-1}$  for 2 weeks). We did not use this drug intra-lesionally because of the level of pain reported by the patient. The swelling decreased almost completely in approximately 1 month (Fig. 1b). No relapses were observed during follow-up (27 months).

## DISCUSSION

In 1990, Sitheeque et al. (8) reported on a group of 492 patients with cutaneous leishmaniasis localized to the lips and peri-oral regions. Subsequently, El-Hoshy (1) published 12 cases of cutaneous leishmaniasis with localization on the lips, claiming that this is frequent although rarely reported in the literature. However, on the basis of the cases published so far (2–7), cutaneous leishmaniasis of the lips appears to be very rare outside Saudi Arabia. Furthermore, some cases described as leishmaniasis of the lips were actually examples of leishmaniasis of the face (4, 6).

In the rare cases in which it was possible to determine the responsible species, *Leishmania donovani* (7), *Leishmania major* (5) and *Leishmania tropica* (1, 2) were demonstrated. Clinical diagnosis of leishmaniasis of the lips is difficult: the most important diseases that must be taken into consideration in differential diagnosis are syphilitic chancre, cutaneous tuberculosis, granulomatous cheilitis, Melkersson-Rosenthal syndrome and squamous cell carcinoma.

As far as therapy is concerned, with the exception of a case of spontaneous complete remission (3) all the other patients were successfully treated with pentavalent antimony derivatives by the endovenous (6), intramuscular (1, 4, 5) or intralesional route (2, 7). No improvement was observed by means of cryotherapy or oral ketoconazole (1).

## REFERENCES

1. El-Hoshy K. Lip leishmaniasis. *J Am Acad Dermatol* 1993; 28: 661–662.
2. Haim S. *Leishmania tropica* presenting macrocheilia. Report of a case. *Dermatologica* 1975; 150: 292–294.
3. Schewach-Millet M, Kahana M, Ronnen M, Yuzuk S. Mucosal involvement of cutaneous leishmaniasis. *Int J Dermatol* 1986; 25: 113–114.
4. Asvesti C, Anastassiadis G, Kolokotronis A, Zographakis I. Oriental sore: a case report. *Oral Surg Oral Med Oral Pathol* 1992; 73: 56–58.
5. Linss G, Richter C, Janda J, Gantenberg R. Leishmaniose der Lippen unter dem klinischen Bild einer Mykose. *Mycoses* 1998; 41 (Suppl. 2): 78–80.
6. Amin M, Manisali M. Cutaneous leishmaniasis affecting the face: report of a case. *J Oral Maxillofac Surg* 2000; 58: 1066–1069.
7. Borgia F, Vaccaro M, Guarneri F, Manfrè C, Cannavò SP, Guarneri C. Mucosal leishmaniasis occurring in a renal transplant recipient. *Dermatology* 2001; 202: 266–267.
8. Sitheeque MA, Qazi AA, Ahmed GA. A study of cutaneous leishmaniasis involvement of the lips and perioral tissues. *Br J Oral Maxillofac Surg* 1990; 28: 43–46.