

Disseminate and Recurrent Infundibulo-folliculitis

María Isabel Longo¹, Manuel Lecona² and Pablo Lázaro¹

Departments of ¹Dermatology and ²Pathology, Hospital Grogorio Marañón, C/Dr. Esquerdo 46, ES-28007 Madrid, Spain.

E-mail: milongo@arrakis.es

Accepted December 17, 2001.

Sir,

Disseminate and recurrent infundibulo-folliculitis is an infrequent entity of unknown etiology first described in 1968 by Hitch & Lund (1). Most patients are young Black male adults, although it has also been described in Whites and in women (2, 3). Lesions are usually flesh-coloured, small follicular papules with smooth surface and that do not coalesce. They predominate in the trunk and the proximal part of extremities. Symptoms are highly variable, but mild pruritus is commonly referred. The majority of patients lack any personal or family history of skin diseases such as atopic dermatitis. We here describe a case of disseminate and recurrent infundibulo-folliculitis in a Black woman.

CASE REPORT

A 25-year-old Black woman was referred for evaluation of a slightly pruritic, recurrent eruption of 7 months' duration. She had no personal or family history of skin diseases. Physical examination revealed multiple small follicular papules symmetrically distributed over the chest, abdomen and back. In some areas the lesions were arranged following the lines of cleavage (Fig. 1). A biopsy specimen showed follicular spongiosis, exocytosis of lymphocytes and a subtle lymphocytic inflammatory infiltrate around follicles and blood vessels in the superficial dermis (Fig. 2).

DISCUSSION

Disseminate and recurrent infundibulo-folliculitis is a well-characterized entity based on histologic changes



Fig. 1. Follicular papules following the lines of cleavage of the skin.

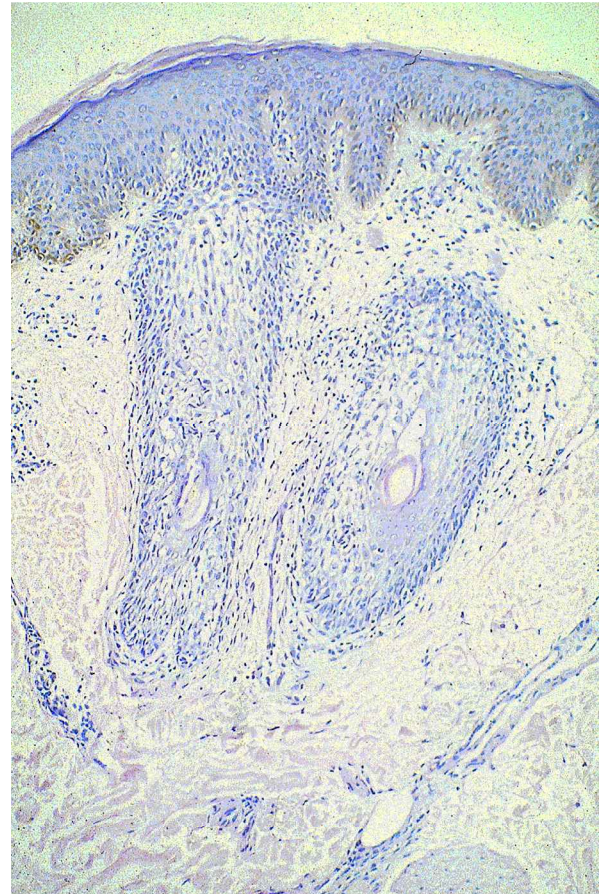


Fig. 2. Follicular spongiosis with exocytosis of lymphocytes and a perifollicular and perivascular lymphocytic infiltrate.

and clinical findings. It is probably overlooked, given the scarce amount of reports. It should be differentiated from other follicular disorders such as keratosis pilaris and lichen spinulosus. Keratosis pilaris is usually associated with ichthyoses and atopic dermatitis. It consists of scaly, follicular papules located on the extensor surfaces of extremities and occasionally the lesions are generalized. Lichen spinulosus presents as hyperkeratotic follicular papules grouped in patches in the neck, extensor surfaces of arms, abdomen, buttocks and thighs. These entities have more scaling and hyperkeratosis is normally absent in disseminate and recurrent infundibulo-folliculitis.

Cases of persistent eruptions in confined sites have led some authors, including Hitch & Lund (4, 5), to question the appropriateness of the actual name. Given

its potential for spontaneous resolution, the assessment of different treatment modalities has been difficult.

REFERENCES

1. Hitch JM, Lund HZ. Disseminate and recurrent infundibulo-folliculitis report of a case. *Arch Dermatol* 1968; 97: 432–435.
2. Wolf M, Tolmach J. Disseminate and recurrent infundibulo-folliculitis. *Arch Dermatol* 1971; 103: 552–553.
3. Barrière H, Litoux P, Bureau B, Stalder JF. Infundibulo-folliculite disséminée et récidivante (Hitch et Lund). *Ann Dermatol Venereol* 1980; 107: 299–302.
4. García RL. Disseminate and recurrent infundibulo-folliculitis: a case report. *Bull Assoc Milit Derm* 1970; 18: 20–21.
5. Hitch JM, Lund HZ. Disseminate and recurrent infundibulo-folliculitis *Arch Dermatol* 1972; 105: 580–583.

Dyshidrotic Eczema Giving Rise to Painful Lower Leg Ulceration as a Result of Smoking?

Carine van der Vleuten and Pieter van der Valk

Department of Dermatology, University Medical Centre Nijmegen, P.O. Box 9101, 6500 HB Nijmegen, The Netherlands.

E-mail: c.vandervleuten@derma.azn.nl

Accepted December 11, 2001.

Sir,

Dyshidrotic eczema is frequent in the hands and feet, and is associated with allergic contact eczema (Ni, Cr), irritant contact dermatitis, atopy, mycotic infection and emotional distress. The more severe forms of dyshidrosis (pompholyx) may give rise to oozing and secondary infection, but these lesions often heal without any problems, along with amelioration of the eczema (1).

Foot ulcers are also common in dermatological practice. Causes of foot and leg ulceration are chronic venous insufficiency and stasis, diabetes mellitus, hypertension, arterial insufficiency, infections and other underlying systemic diseases (2).

A combination of dyshidrosis and lower leg ulceration at the same site has not been described in the literature so far.

In this clinical report we present four young patients with dyshidrotic eczema followed by very painful ulceration of the feet. The ulcers required hospitalization with bed-rest in all four patients. Besides smoking, no other risk factors for ulceration could be distinguished.

CASE REPORTS

Case 1

A 43-year-old man had suffered from recurrent mycosis of the feet for years and dyshidrotic eczema on the hands and feet for a few months. During a holiday to the Maldives, the eczema of the feet exacerbated with vesicles, secondary infection, followed by ulceration interdigitally and on the dorsal side of the left forefoot at the site of the eczema. The ulcers were superficial, covered an area of approximately 4 cm² and were painful. Because of the pain, the patient developed post-traumatic dystrophy of the left leg. He had no atopy and no relevant contact factors were involved in the patient history. He smoked more than 25 cigarettes per day.

Cultures of the ulcer showed growth of *pseudomonas* and *staphylococcus aureus*. Histological investigation showed a non-specific ulcerating dermatitis with several bacterial colonies. Contact allergies for lanolin, epoxy resin, parabenes, fragrance-mix, cocamidopropylbetaine were found, although

no relevance for the perseverance of the complaints could be established. No arterial insufficiency could be established (toe-brachial pressure index = 1).

The patient was admitted to our inpatient department and bed-rest was given. Treatment of the eczema with a potent topical corticosteroid combined with acetic acid topically for the secondary infected ulcer was instituted. The painful ulcer showed a tendency to recur. Continuous therapy with topical corticosteroids was required to prevent exacerbation of the eczema and subsequent ulceration. The patient temporarily stopped smoking.

Recently, an arterial insufficiency was discovered and treated by PTCA. Although we could not establish arterial insufficiency 2 years earlier, the episode of dyshidrosis and ulceration was probably an indication of a developing arterial insufficiency.

Case 2

A 33-year-old man had a history of dyshidrotic eczema of the hands 7 years earlier. His complaints were partly job-related (rose-grower), although no specific contact allergies were established. He changed jobs and became a truck driver. After 6 years, the dyshidrotic eczema relapsed on the hands and mainly the feet, giving rise to very painful ulceration of the feet at the site of the eczema (plantar and also interdigitally). The ulcer was of intermediate depth, with a diameter of 1.5 cm. Arterial pulsation was intact. The patient was not able to work as a truck driver because the ulcer was located just at the ball of the foot, where pressure was required for the accelerator pedal. He had no atopic constitution. The patient smoked 15 cigarettes per day.

Cultures of the ulcer showed growth of *pseudomonas*. There were no signs of a herpes infection. Histological investigations showed changes compatible with non-specific ulceration. We found no contact allergies after elaborate testing. A roentgenogram did not show osteomyelitis.

Treatment was started with topical corticosteroids combined with acetic acid topically for the secondary infected ulcer. The ulcer healed, but the eczema and subsequently the ulcers relapsed after the patient returned to work. The patient was hospitalized for bed-rest and treated with topical corticosteroids and coal tar and analgesics, a regime that was continued after discharge from hospital. In the following 2 years, the lesions appeared and disappeared, requiring another episode of hospitalization. The patient stopped smoking and the eczema has remained abated until now (for 2 years) with intermittent treatment of topical corticosteroids.