

INVESTIGATIVE REPORT

Effect of Latanoprost on Hair Growth in the Bald Scalp of the Stump-tailed Macaque: A Pilot Study

HIDEO UNO¹, MICHELE L. ZIMBRIC², DANIEL M. ALBERT² and JOHAN STJERNSCANTZ³

¹Wisconsin Regional Primate Research Centre and ²Department of Ophthalmology and Visual Sciences, School of Medicine, University of Wisconsin-Madison, Wisconsin, USA and ³Department of Neuroscience, Unit of Pharmacology, Biomedical Centre, Uppsala, Sweden

Latanoprost, a selective FP prostanoid receptor agonist used in the treatment of glaucoma, has a hypertrichotic side effect. Using the macaque model of androgenetic alopecia, we examined the effect of latanoprost on hair growth. Eight monkeys were divided into 2 groups; one group received a daily topical application of 50 µg/ml of latanoprost for 5 months; a control group had a daily application of vehicle. For an additional 3 months, 2 monkeys from each group were given 500 µg/ml latanoprost, while the remaining monkeys continued with the previous treatment. Hair growth was evaluated by monthly photographs and phototrichographic analysis. Fifty µg/ml of latanoprost caused minimal hair growth. Latanoprost at 500 µg/ml induced moderate to marked hair regrowth with 5–10% conversion of vellus hairs to intermediary or terminal hairs. The vehicle group showed no effect. Further evaluation of latanoprost as an agent for treatment of human androgenetic alopecia is indicated. **Key words:** latanoprost; stump-tailed macaque hair growth.

(Accepted December 3, 2001.)

Acta Derm Venereol 2002; 82: 7–12.

Hideo Uno, M.D, 119142 Kantara Way, West Linn, OR 97068, USA. E-mail: huno4@attbi.com

Latanoprost, a prostaglandin F2a analogue, is a selective FP prostanoid receptor agonist. This drug is known to profoundly reduce intraocular pressure and is used as an eye drug to treat glaucoma. Although latanoprost has no major adverse side effects, the patients receiving the medication have noticed an increased number, length, thickness, and darkening of eyelashes and hair in the medial canthal region (1–3). Among numerous reports on clinical and basic pharmacological aspects of latanoprost, the major actions related to hypertrichotic effects are considered to be peripheral vasorelaxation and melanogenesis (1, 4–11). Agents that induce potent hypertrichotic effects are known as peripheral vasodilators that act as potassium-channel openers, such as minoxidil and diazoxide. Minoxidil, used originally for hypertensive treatment, is employed topically for the treatment of human androgenetic alopecia (male-patterned baldness).

Adult stump-tailed macaques (*Macaca arctoides*) develop frontal alopecia and have been used for screening of hair growth agents of hypertrichotic drugs (minoxidil and diazoxide), steroid 5-alpha reductase inhibitors (finasteride), and anti-androgen, RU 58841 (12–20).

In this study, we initially examined the effect of latanoprost (Xalatan TM, 50 µg/ml. Pharmacia-Upjohn Company, Uppsala, Sweden) on hair regrowth in the bald scalp of stump-tailed macaques. In an additional study of some of these animals, we used latanoprost, 500 µg/ml, to observe the augmented effects by using a higher dose of latanoprost. For evaluation of hair growth in these studies, we developed two non-invasive methods which provide us with more objective data than our previous studies, namely: 1) categorical grading of hair growth in sequential global photographs, and 2) phototrichographic analysis of vellus, intermediary and terminal hairs.

MATERIALS AND METHODS

Stump-tailed macaques

Eight adult stump-tailed macaques (4 females and 4 males, age range 5.10–14.5 years) were utilized. All showed a moderate to advanced degree of baldness prior to treatment. These macaques were raised in our colony and kept in indoor single- or double-occupancy cages. The room containing the cages was maintained at 22°C, with 50–70% relative humidity, and illuminated with a 12-h lights-on and lights-off cycle. A commercial monkey diet with supplemental fresh fruits consisting of apples, oranges, or bananas was given daily. Water was supplied ad libitum. Two full-time technicians and a veterinarian provided continuous monitoring and care. The monkeys were treated in accordance with ethical guidelines of the Research Animal Resources Center, University of Wisconsin-Madison. All experimental procedures met the generally accepted international criteria of human treatment, sparing the animals needless pain and requiring that experiments conducted are of actual scientific benefit to mankind.

Experimental groups

For the initial test, the 8 macaques were divided into 2 groups; 4 for treatment with latanoprost at 50 µg/ml and 4 receiving vehicle solution, a mixture of polysorbate 80, 0.5% and bezalkonium chloride, 0.2 mg/ml, in phosphate buffer solution (formulated by Pharmacia & Upjohn, Uppsala, Sweden). A quantity of 0.5 ml of either latanoprost or vehicle was applied per monkey. The solution was dropped on the bald frontal scalp and distributed over the area using a short-haired brush. Treatment was given once per day, 5 days per week. At the

beginning of the 5th month the treatment protocol was altered and a new treatment, latanoprost at 500 µg/ml, was added. Two macaques previously receiving latanoprost 50 µg/ml and 2 previously receiving vehicle were treated for the next 3 months with 0.5 ml of latanoprost at 500 µg/ml applied as described above, once per day, 5 times a week.

Evaluation of hair growth

Global photographic recording of hair growth; categorical grading of sequential changes. Photographs of the entire region of the frontal scalp were taken at baseline (pretreatment) and thereafter at 1-month intervals until the end of the study. Sequential assessment of the monthly photographs was performed at the end of the experiment.

Hair in the bald scalp of macaques is of three distinguishable types: (a) vellus hair is short and fine fuzzy hair, thin-greyish in color, (b) intermediary hair appears medium long and slender with dark brown colored shafts, and (c) terminal hair is characterized by long and coarse hair shafts with periodical stripes – color alternating between yellow and dark brown. Overall thickness of hair shaft in these 3 hair types is less in younger male and female than fully mature male monkeys (16, 17, 28).

Using global photographs of the frontal scalp, grade of hair growth was categorized as follows: 1) type of hair (vellus, intermediary, and terminal), 2) density of hair (increased or decreased covering of hair), 3) size of responding area, and 4) time to first response after initiation of treatment (Table I). The sums of the grading score in the above categorical changes were used for evaluation of global hair growth. The score was evaluated as follows: marked effect = 15–13, moderate effect = 12–10, slight effect = 9–8, minimal effect = 7–3, no effect = less than 2.

Phototrichographic analysis. The primary purpose of phototrichographic analysis is to make it possible to quantitatively

Table I. Grading score for hair growth evaluation*

| | |
|--|-----|
| Change in hair type: | |
| Regression (shorter and thinner) | T-0 |
| No change (maintaining) | T-1 |
| Short vellus to longer vellus hair | T-2 |
| Intermediary to long, thick intermediate | T-2 |
| Vellus to intermediary hair | T-3 |
| Intermediary hair to terminal | T-4 |
| Vellus to terminal | T-5 |
| Change in hair density: | |
| Decrease, thinner | D-0 |
| No change | D-1 |
| Slight increase | D-2 |
| Moderate increase | D-3 |
| Marked increase | D-4 |
| Responded area in scalp: | |
| None | A-0 |
| Partial, limited | A-1 |
| Regional (zone) | A-2 |
| Overall | A-3 |
| Time, responding: | |
| Not ever | R-0 |
| Slow (over 6 months) | R-1 |
| Moderate (3–5 months) | R-2 |
| Early (1–2 months) | R-3 |

*Evaluation (sum of scores): marked effect 15–13; moderate 12–10; slight 9–8; minimal 7–3; no effect > 2.

assess the growth rate of vellus hair in relation to the intermediary type and intermediary hair in relation to the terminal type in the same area of the scalp. The total number of each hair type is recorded by both computer-assisted image analysis and manual counting in the printed image. Increased or decreased populations of the three different types of hairs are compared at zero and at 3 months after the experimental treatment. If the drug is effective, the number of vellus hairs decreases and the numbers of either intermediary or terminal hairs increase.

Hairs in select areas of the bald frontal scalp were cut to about 2 mm length and then dyed. Close-up photographs were taken of hair in a 7 × 10 mm² area in the above-mentioned region of the scalp surface. Photographs of the hair were scanned as digital images. The digitized images were opened and analyzed using the NIH Image 1.61 software package (Center for Information Technology, NIH, USA). Because hair thickness was directly related to grey levels, upper and lower thresholds were established to successively fill in the selected caliber of hair, such as vellus type and label on hair images. The image analysis was performed under 3 separate threshold values for vellus (thinnest hair), intermediary (medium thickness), and terminal hair (thickest diameter). Moreover, the pixel values of upper and lower thresholds were established separately in each animal because of the thickness of hair shafts in each hair type, vellus to terminal smaller in the balding scalp of females when compared to males. Overlapped hairs in these images were manually counted in the printed images and the final count of hair was corrected from the values obtained from the computer image analysis. The differences between 0 and 3 months of treatment represented as the change of rate, increased or decreased percentages, of each hair type.

Physiological and laboratory examinations

During the experimental period, we carefully observed the animals for local side effects. All monkeys were monitored by physical examination and monthly body weight, and standard laboratory examinations for haematological and blood chemistry tests were carried out to rule out possible systemic side effects.

RESULTS

Global photographic evaluation

The grading scores (see Table I) for the 4 categories of sequential changes of types of hair: density, responding areas, and time of response are listed in Table II. During the initial 5 months of treatment with latanoprost at 50 µg/ml, one animal showed a moderate to minimal degree of hair regrowth and 3 showed minimal hair regrowth. In the macaque showing moderate hair growth, the short vellus hairs in the pretreatment time grew into longer intermediary hairs, and the overall density of hair in the bald scalp region had increased by the end of 5 months of treatment (Fig. 1a and b). The other three macaques receiving latanoprost at 50 µg/ml showed minimal changes in all 4 categories of hair growth. The 4 monkeys treated with vehicle alone showed no noticeable effect on hair growth except for one that demonstrated a minimal degree of increased density. As noted in the Methods section, after the 5 months' initial test, 2 macaques receiving latanoprost 50 µg/ml and 2 from the vehicle group were treated with

Table II. Sequential changes of scalp hair based on global photographs

| Treatment of animals | Hair type | Hair density | Area respond | Time respond | Score (average) | Effect |
|--|-----------|--------------|--------------|--------------|-----------------|--------------------|
| Latanoprost (50 µg/ml) 0–5 month | | | | | | |
| No. 1* | T-3 | D-2 | A-1 | R-3 | 9 | moderate (Fig. 1b) |
| No. 2* | T-1 | D-2 | A-1 | R-2 | 6 | minimal |
| No. 3 | T-2 | D-2 | A-1 | R-2 | 7 | minimal |
| No. 4 | T-1 | D-2 | A-1 | R-2 | 6 | minimal |
| | | | | | Ave = 7# | |
| Vehicle 0–5 month | | | | | | |
| No. 5* | T-1 | D-0 | A-0 | R-0 | 1 | no effect |
| No. 6* | T-1 | D-2 | A-1 | R-3 | 7 | minimal |
| No. 7 | T-0 | D-0 | A-0 | R-0 | 0 | no effect |
| No. 8 | T-0 | D-0 | A-0 | R-0 | 0 | no effect |
| | | | | | Ave = 2# | |
| Latanoprost (500 µg/ml) 6–8 month | | | | | | |
| No. 1* | T-4 | D-4 | A-2 | R-3 | 13 | marked (Fig. 1c) |
| No. 2* | T-2 | D-2 | A-3 | R-3 | 10 (11.5#) | moderate |
| No. 5* | T-2 | D-2 | A-2 | R-3 | 9 | slight |
| No. 6* | T-2 | D-2 | A-1 | R-2 | 7 (8#) | minimal |
| Latanoprost (50 µg/ml) 6–8 month | | | | | | |
| No. 3 | T-2 | D-2 | A-1 | R-2 | 7 | minimal |
| No. 4 | T-1 | D-2 | A-1 | R-2 | 6 | minimal |
| | | | | | Ave = 6.5# | |
| Vehicle: 6–8 month | | | | | | |
| No. 7 | T-0 | D-0 | A-0 | R-0 | 0 | no effect |
| No. 8 | T-0 | D-0 | A-0 | R-0 | 0 | no effect |
| | | | | | 0# | |

*After 5 months, switch to latanoprost 500 µg/ml; $p < 0.01$.

#Average score used for Fig. 2.

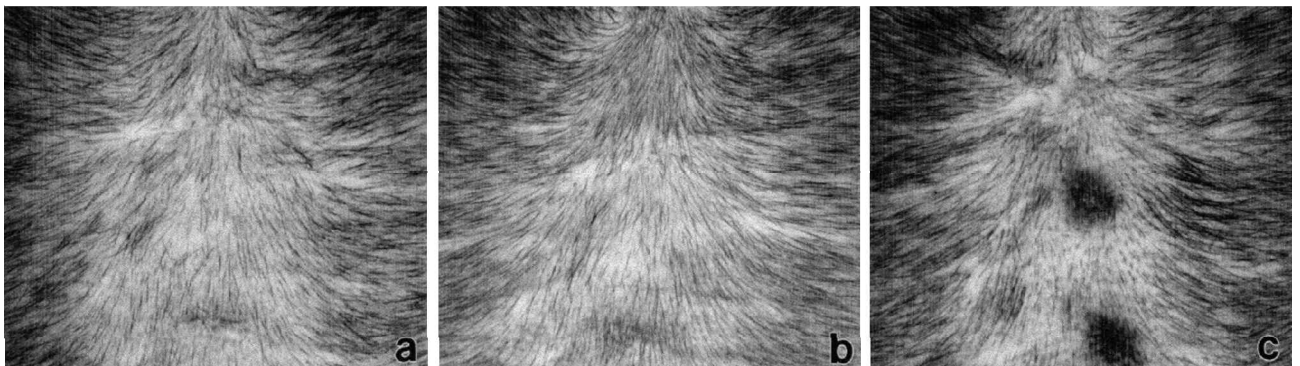


Fig. 1. Frontal bald scalp of a 10-year-old, female, macaque, showing sparse short vellus hairs in the bald scalp at pretreatment time (a). After 5 months of treatment with latanoprost 50 µg/ml, thickness and density of hair increased in upper central and lower lateral regions (b). After 3 months of latanoprost 500 µg/ml thickness and density of hair significantly increased in mid and lower lateral region.

latanoprost 500 µg/ml for the subsequent 3 months. All 4 cases showed an increased degree of hair growth beyond that seen during the initial 5 months of treatment with latanoprost at 50 µg/ml. The 2 monkeys that were previously in the latanoprost group showed marked to moderate hair growth. There was an increase in hair density and conversion of vellus or intermediary hairs (Fig. 1c). The 2 animals from the former vehicle group showed a less marked increase in hair growth. The 2 macaques continued on latanoprost 50 µg/ml and the 2 macaques continued on vehicle for 3 additional months showed no further increased effect. The graph in Fig. 2 represents the average scores of the global category of

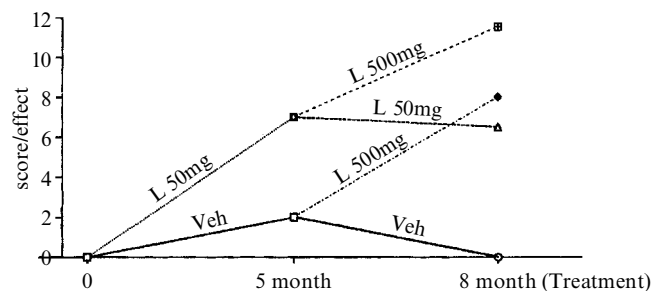


Fig. 2. Sequential changes of average scores of categorical grades of hair growth in latanoprost and vehicle-treated monkeys.

changes of hair growth in all 8 cases during both the initial 5-month treatment period and the additional test. Latanoprost 500 µg/ml induced a significantly increased degree of hair growth compared to the lower concentration of latanoprost and vehicle groups.

Phototrichographic analysis for conversion rates of hair types in Table III shows the increased or decreased rates of all 3 types of hair in the groups of latanoprost 500 µg/ml, latanoprost 50 µg/ml, and vehicle, during the final 3 months of treatment. In 3 of 4 cases in the latanoprost 500 µg/ml group (i.e. animal nos. 1, 2, and 5), the vellus hair decreased in the range 4.5–10.5% and was converted for the most part mostly to intermediary hair (1–8.1%) and to a lesser extent (1.5–4%) to terminal hair. The average rates of increased or decreased population of 3 types of hair were calculated in each treatment group; a total of increased (plus) and decreased (minus) numbers was divided by number of cases in each group (parentheses in Table III). Fig. 3 shows phototrichographic images of hairs in the same scalp region of one case (no. 5); vellus, intermediary, and terminal hairs observed in the scalp region under observation are documented in the inserted high power view in Fig. 3a. One case (no. 6) in the latanoprost 500 µg/ml group showed some intermediary hair that regressed to vellus hair. A few (2.5%) of these intermediary hairs converted to terminal hairs. One of the macaques treated with latanoprost 50 µg/ml (no. 3) during the final 3 months showed that vellus hair mostly converted to intermediary hair. In the other similarly treated animal (no. 4), approximately half of intermediary hair regressed to vellus, while the remainder of the treated macaques grew terminal hair. In the vehicle-treated group, the macaques showed either regression (i.e. increased vellus hair and decreased intermediary and terminal types) or no change of hair types during the last 3 months of treatment.

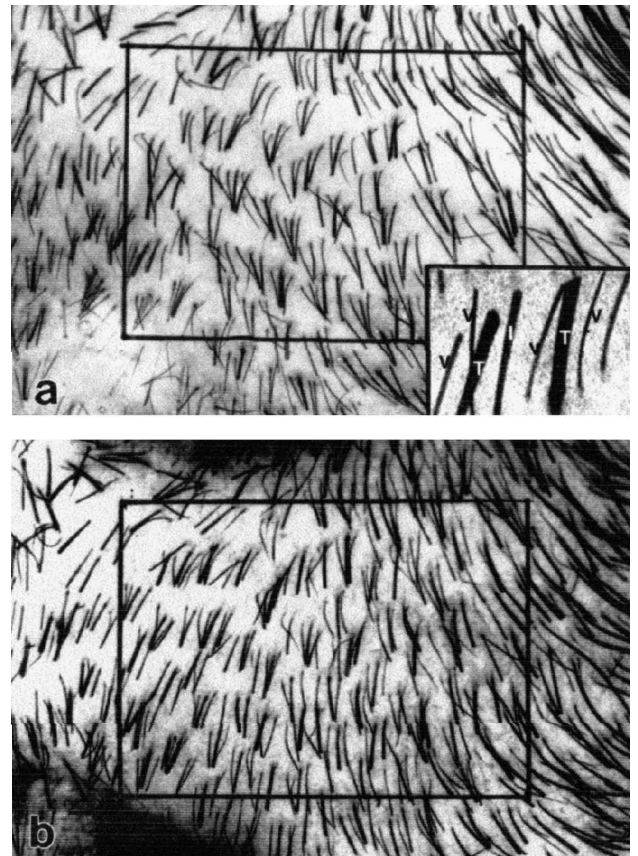


Fig. 3. Phototrichographs of monkeys treated with latanoprost 500 µg/ml; pretreatment (a) and 3 months after treatment (b). High-power magnification of individual hair representing vellus (v), intermediary (I) and terminal (T) hair (inserted).

Physiological and hematological examinations

Seven of the 8 monkeys either maintained their weight or showed a small decrease in weight during the course of the experiment. One animal (no. 3) in the latanoprost

Table III. Change of population in hair types during the last 3 months of treatment

| Treatment/case no. | Type of hair Vellus (%) | Intermediary (%) | Terminal (%) |
|--------------------------------|----------------------------|------------------|---------------|
| Latanoprost (500 µg/ml) | | | |
| No. 1 | Decrease 10.5% | Increase 6.6% | Increase 4% |
| No. 2 | Decrease 10.2% | Increase 8.7% | Increase 1.5% |
| No. 5 | Decrease 4.5% | Increase 1% | Increase 3.5% |
| No. 6 | Increase 4.4% | Decrease 7% | Increase 2.5% |
| (Average)* | (- 5.3%) | (+ 9.3%) | (+ 2.9%) |
| Latanoprost (50 µg/ml) | | | |
| No. 3 | Decrease 6.7% | Increase 17.7% | Decrease 1.2% |
| No. 4 | Increase 2% | Decrease 4.6% | Increase 2.5% |
| (Average)* | (- 2.3%) | (+ 6.6%) | (+ 0.6%) |
| Vehicle | | | |
| No. 7 | Increase 7.5% | Decrease 4.6% | Decrease 2% |
| No. 8 | Decrease 0.1% | Decrease 0.6% | Decrease 0.9% |
| (Average)* | (- 3.7%) | (- 2.6%) | (- 1.5%) |

*Average rates in each group calculated by decreased (minus) and increased (plus) populations in 3 types of hair in each treatment group.

50 µg/ml group demonstrated a 20% decrease in body weight during the experiment, but no other abnormalities were seen. The results of hematological and blood chemistry examinations for all 8 monkeys were within the normal limit during the entire course of the experiment.

DISCUSSION

In these experiments we studied the bald scalp of the stump-tailed macaque, which serves as a non-human primate model of human androgenetic alopecia. We observed that latanoprost had a positive action on hair growth. This effect of latanoprost on hair growth was dose-dependent and the minimal effective dose was 50 µg/ml (0.005% w/v). At a dose of 500 µg/ml (0.05%), latanoprost induced significant hair growth, corresponding to that seen with 5% minoxidil solution in our previous studies. The phototrichographic data showed that 0.05% latanoprost solution induced 10% conversion of the vellus hair to intermediary or to terminal hairs in 2 of 4 macaques. In our earlier studies, 5% minoxidil induced 10% conversion of vellus hair to terminal hairs in the macaque showing the greatest response (17).

Observing monthly global photographs, latanoprost 500 µg/ml induced noticeable hair regrowth and increased thickening and length of hair, as early as one month after treatment in 3 out of 4 monkeys. During 3 months of treatment, all 4 monkeys showed further progression of hair growth. These sequential changes of hair growth were graded according to 4 categories. The average grading scores assessed from monthly global photographs in the 3 experimental groups (latanoprost 50 µg/ml and 500 µg/ml, and vehicle) corresponded well with the data of phototrichographic analysis.

Follicular regression in androgenetic alopecia in both human and stump-tailed macaques is known to be triggered by postpubertal elevation of serum testosterone and dihydrotestosterone (22–25). Furthermore, an inhibitor of 5- α -reductase, finasteride, and androgen receptor blocker, RU58841, successfully induced regrowth of hair in the bald scalp in both human and macaque alopecia (18, 19, 21, 26).

Hypertrichotic agents such as minoxidil and diazoxide induce thickening of hairs elsewhere in the body (27, 28). These vasodilators acting as potassium channel openers are known to cause regrowth of hair in human and macaque alopecia (13, 29, 30). Minoxidil also activates cyclo-oxygenase I (PGHS I) in human dermal papilla fibroblasts, resulting in increased production of prostaglandin (31). The dermal papilla cells in follicles are known to have inductive action on the cyclic growth and transformation of follicles (32–34). Latanoprost as an analogue of prostaglandin F₂ α is known to have diverse pharmacological effects such as vasodilatory, melanogenic, and hypertrichotic effects (1, 2, 3, 10, 11, 35). The vasodilatory action of minoxidil and latano-

prost appears to associate with prostaglandin F₂ α , which induces long-standing vasodilation in perifollicular vessels resulting in stimulating follicular growth.

In summary, latanoprost, a selective FP prostanoid receptor agonist, showed a potent effect on hair growth in the bald scalp of macaques. Thus, latanoprost appears to be a promising candidate in the therapy of human androgenetic alopecia.

ACKNOWLEDGEMENTS

This work was partly supported by NIH Grant RR-00167 and a grant from the Pharmacia & Upjohn Company, Uppsala, Sweden. The authors acknowledge Mrs Adrienne Capps for daily application of compounds and technical assistance, and Dr Robert Becker and Shoko Uno for computer imaging and analysis of phototrichography. This is publication no. 40-027 of the Wisconsin Regional Primate Research Center.

REFERENCES

1. Wand M. Latanoprost and hyperpigmentation of eyelashes. *Arch Ophthalmol* 1997; 115: 1206–1208.
2. Johnstone MA. Hypertrichosis and increased pigmentation of eyelashes and adjacent hair in the region of the ipsilateral eyelids of patient treated with unilateral topical latanoprost. *Am J Ophthalmol* 1997; 124: 544–547.
3. Reynolds A, Murray PI, Colloby PS. Darkening of eyelashes in a patient treated with latanoprost. *Eye* 1998; 12: 741–743.
4. Erb C, Messerli J, Flammer J. Latanoprost – a new prostaglandin F₂ alpha analog in therapy of glaucoma: an overview. *Klin Monstbl Augenheilkd* 1998; 212: 2–12.
5. Zhang J, Van Meel JC, Pfaffendorf M, Zhang J, Van Zweiten PA. Endothelium-dependent nitric oxide-mediated inhibition of angiotensin II-induced contractions in rabbit aorta. *Eur J Pharmacol* 1994; 262: 247–253.
6. Chen J, Champa-Rodrigues ML, Woodward DF. Identification of a prostanoid FP receptor population producing endothelium-dependent vasorelaxation in the rabbit jugular vein. *Br J Pharmacol* 1995; 116: 3035–3041.
7. Astin M, Stjerschantz J. Mechanism of prostaglandin E₂, F₂alpha- and latanoprost acid induced relaxation of submental veins. *Eur J Pharmacol* 1997; 340: 195–201.
8. Astin M. Effects of prostaglandin E₂, F₂alpha, and latanoprost acid on isolated ocular blood vessels *in vitro*. *J Ocul Pharmacol Ther* 1998; 14: 119–128.
9. Seong GJ, Lee HK, Hong YJ. Effects of 0.005% latanoprost on optic nerve head and peripapillary retinal blood flow. *Ophthalmologica* 1999; 213: 355–359.
10. Lindquist NG, Larsson BS, Stjerschantz J. Increased pigmentation of iridial melanocytes in primates induced by a prostaglandin analogue. *Exp Eye Res* 1999; 69: 431–436.
11. Stjerschantz J, Selen G, Astin M, Karlsson M, Resul B. Effect of latanoprost on regional blood flow and capillary permeability in the monkey eye. *Arch Ophthalmol* 1999; 117: 1363–1367.
12. Uno H, Capps A, Schlagel C. Cyclic dynamics of hair follicles and the effect of minoxidil on the bald scalp of stump-tailed macaques. *Am J Dermatopath* 1985; 7: 283–297.
13. Uno H, Capps A, Brigham P. Action of topical minoxidil in the bald stump-tailed macaque. *J Am Acad Dermatol* 1987; 16: 657–668.
14. Uno H. Stumptailed macaques as a model of male-pattern

- baldness. In: Maibach HI, Lowe NJ, eds. Models in dermatology, vol. 3. Basel: S. Karger AG. 1987: 159–169.
15. Rittmaster RS, Uno H, Povar ML, Mellin TN, Loriaux DL. The effect of 4-MA, a 5 α -reductase inhibitor and anti-androgen, on the development of baldness in the stump-tail macaque. *J Endocrinol Metab* 1987; 65: 188–193.
 16. Uno H. Quantitative models for the study of hair growth *in vivo*. In: Stenn KS, Messenger AG, Baden HP, eds. Molecular and structural biology of hair. *Ann NY Acad Sci* 1991; 642: 107–124.
 17. Uno H, Kurata S. Chemical agents and peptides affect hair growth. *J Invest Dermatol* 1993; 101: 143S–147S.
 18. Rhodes L, Harper J, Uno H, Gaito G, Audette-Arruda J, Kurata S, et al. The effect of finasteride (Proscar) on hair growth, hair cycle stage, and serum testosterone and dihydrotestosterone in adult male and female stump-tail macaques (*Macaca arctoides*). *J Clin Endocrinol Metab* 1994; 79: 991–996.
 19. Obana N, Chang C, Uno H. Inhibition of hair growth by testosterone in the presence of dermal papilla cells from the frontal bald scalp of the postpubertal stump-tailed macaque. *Endocrinology* 1997; 138: 356–361.
 20. Sundberg JP, Beamer WG, Uno H, Van Neste D, King LE. Androgenetic alopecia: *in vivo* models. *Exp Mol Pathol* 1999; 67: 118–129.
 21. Uno H, Obana N, Cappas A, Bonfils A, Battmann T, Philibert D. Stimulation of follicular regrowth by androgen receptor blocker (RU58841) in macaque androgenetic alopecia. In: Van Neste DJ, Randall VA, eds. Hair research for the next millennium. Amsterdam: Elsevier Science 1996: 349–353.
 22. Price VH. Testosterone metabolism in the skin. *Arch Dermatol* 1975; 111: 1496–1502.
 23. Uno H. Biology of hair growth. In: Speroff L, ed. Seminars in reproductive endocrinology: andrology in women, vol. 4. New York: Thieme-Stratton, 1986; 131–141.
 24. Randall VA, Thornton MJ, Hamada K, Redfern, CPF, Nutbrown M, Ebling JG, et al. Androgens and the hair follicle; cultured human dermal papilla cells as a model system. In: Stenn KS, Messenger AG, Baden HP, eds. The molecular and structural biology of hair. *Ann NY Acad Sci* 1991; 642: 355–375.
 25. Sawaya M, Price V. Different levels of 5- α -reductase type I and II, aromatase, and androgenreceptor in hair follicles of women and men with androgenetic alopecia. *J Invest Dermatol* 1997; 109: 296–300.
 26. Kaufman KD, Olsen EA, Whiting D, Savin, R, DeVillez R, Bergfeld W, et al. Finasteride in the treatment of men with androgenetic alopecia. Finasteride male pattern hair loss study group. *J Am Acad Dermatol* 1998; 39: 578–589.
 27. Burton JL, Schutt WH, Caldwell IW. Hypertrichosis due to diazoxide. *Br J Dermatol* 1975; 93: 707–711.
 28. Parker LN, Lifrak ET, Odell WD. Lack of a gonadal or adrenal androgenic mechanism for the hypertrichosis produced by diazoxide, phenytoin and minoxidil. *Biochem Pharmacol* 1982; 31: 1984–1950.
 29. De Vilez RL. Androgenetic alopecia treated with topical minoxidil. *J Am Acad Dermatol* 1987; 16: 669–673.
 30. Uno H, Kemnitz JW, Cappas A, Adachi K, Sakuma M.S, Kamoda H. The effects of topical diazoxide on hair follicular growth and physiology of the stump-tailed macaque. *J Dermatol Sci* 1990; 1: 183–194.
 31. Michelet JF, Commo S, Billoni N, Mahe YE, Bernard BA. Activation of cytoprotective prostaglandin synthase-1 by minoxidil as a possible explanation for its hair growth-stimulating effect. *J Invest Dermatol* 1997; 108: 205–209.
 32. Oliver RF. Regeneration of the dermal papilla and its influence on whisker growth. In: Montagna W, Dobson RI, eds. *Advances in biology of skin*. Oxford: Pergamon Press, 1967: 19–33.
 33. Jahoda CAR, Horne KA, Oliver RF. Induction of hair growth by implantation of cultured dermal papilla cells. *Nature* 1984; 311: 560–562.
 34. Reynold AJ, Lawrence C, Cserhalmi-Friedman PB, Christiano AM, Jahoda CAB. Trans gender induction of hair follicles. *Nature* 1999; 402: 33–34.
 35. Lark KK, Pasha AS, Yan X, Edward DP. The effect of latanoprost and brimonidine on rabbit subconjunctival fibroblasts. *J Glaucoma* 1999; 8: 72–76.