

Relapsing Kaposi's Varicelliform Eruption and Herpes Simplex Following Facial Tacrolimus Treatment for Atopic Dermatitis

Midori Ambo

Department of Dermatology, Bibai Rosai Hospital, Labor Welfare Corporation, 3-1, Minami-1, Higashi-4, Bibai 072-0015, Japan.

E-mail: anpo@fa2.so-net.ne.jp

Accepted April 5, 2002.

Sir,

Tacrolimus ointment is an immunosuppressive agent that interferes with cell-mediated immunity (1, 2). It has proved efficient in atopic dermatitis, particularly in adults who suffer from facial dermatitis. We report a case of atopic dermatitis in which episodes of Kaposi's varicelliform eruption and herpes simplex virus (HSV) infection occurred repeatedly when the dermatitis was treated with tacrolimus ointment.

CASE REPORT

The patient was a 32-year-old Japanese woman with a long history of head-and-neck type atopic dermatitis. She had experienced a few outbreaks of herpes simplex on her face in the past and two episodes of Kaposi varicelliform eruption 4 years earlier. Her eczema had been treated with a weak steroid ointment and a vitamin A ointment for several years. In April 2001, tacrolimus ointment was started with good clinical improvement, and in May 2001 she experienced high fever and general fatigue. Vesicles with encrusted erosions or ulcers occurred on her face and neck in the areas where she had been applying the tacrolimus ointment (Figs 1, 2). Laboratory tests revealed a high serum IgE concentration (6523 U/ml) and increased erythrocyte sedimentation rate (28 mm/1 h). All other routine haematological and biochemical parameters were normal. No increase in HSV antibody was observed (1:32 to 1:64). Histologically, a haematoxylin and eosin (H&E) stained section revealed intercellular oedema in the epidermis and intraepidermal blisters with necrotic keratinocytes and a dermal infiltration of mononuclear cells. Several viral giant cells were observed. Immunohistochemical staining with an anti-HSV polyclonal antibody (Dakopatts A/S, Denmark) revealed a positive reaction in the necrotic cells or viral giant cells (Fig. 3). The patient was treated intravenously with acyclovir (750 mg/day) for 5 days and orally with cefcapene pivoxil hydrochloride 300 mg/day to avoid secondary infections. She went into remission without scarring. Three weeks later she again started tacrolimus treatment. However, Kaposi's varicelliform eruption and herpes simplex relapsed in September and October 2001. In each case, she immediately stopped using the tacrolimus ointment and was successfully treated with an oral dose of acyclovir (1000 mg/day) for 5 days.

DISCUSSION

Adult patients with a long history of atopic dermatitis on the face and/or neck can be difficult to treat. Tacrolimus ointment, which is an immunosuppressive agent that interferes with cell-mediated immunity (1, 2), has been successfully applied to intractable cases of

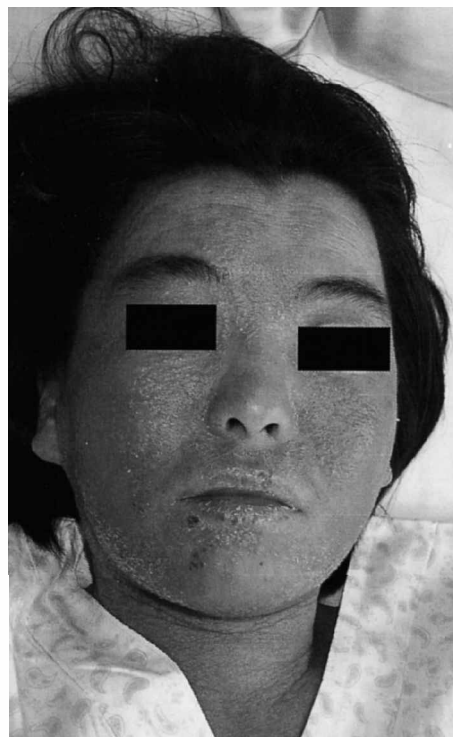

Fig. 1. Clinical appearance. Many vesicles on the face and neck.

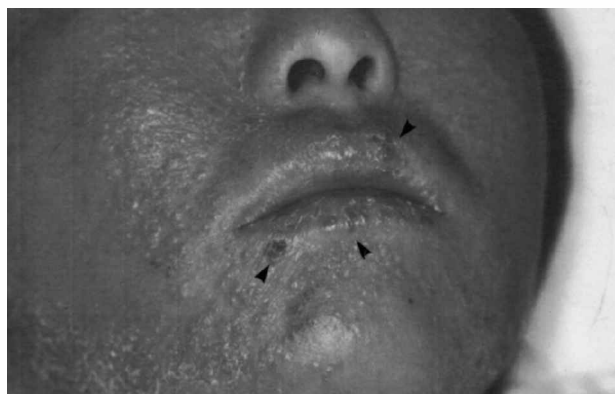

Fig. 2. Encrusted vesicles around the mouth (arrows) and many vesicles on the face.

atopic dermatitis in recent years (3, 4). However, it has been suggested that the use of tacrolimus ointment may be associated with the development or worsening of cutaneous bacterial infections or HSV infections. Furthermore, patients with atopic dermatitis have a tendency to develop Kaposi's varicelliform eruptions (5), which can be accompanied by high fever and tend to leave scars. Patients receiving immunosuppressive therapy are also at a risk of Kaposi's varicelliform eruption (6).

A few cases of Kaposi's varicelliform eruption have been reported in atopic dermatitis patients with no history of HSV-infected diseases after the application of tacrolimus ointment (7). In our case, the patient had suffered several episodes of Kaposi's varicelliform eruption and herpes simplex outbreaks in the past. Moreover, their recurrence has evidently increased after the patient started using tacrolimus ointment.

We believe that tacrolimus ointment should be used with caution in patients with atopic dermatitis who have a past history of herpes simplex or, particularly, Kaposi's varicelliform eruption, and that these patients may be at special risk of developing of Kaposi's varicelliform eruptions while using tacrolimus ointment. If a Kaposi's varicelliform eruption or herpes simplex occurs, application of the ointment should be promptly suspended; medication with systemic acyclovir proved to be effective for viral eradication.

ACKNOWLEDGEMENT

I thank Mr. Takumi Ishida for his help with the immunohistochemical technique.

REFERENCES

1. Frankel SJ, Kerdel FA. Topical tacrolimus. *Skin Therapy Lett* 2001; 6: 1–2,5.
2. Sakuma S, Higashi Y, Sato N, Sasakawa T, Sengoku T, Ohkubo Y, et al. Tacrolimus suppressed the production

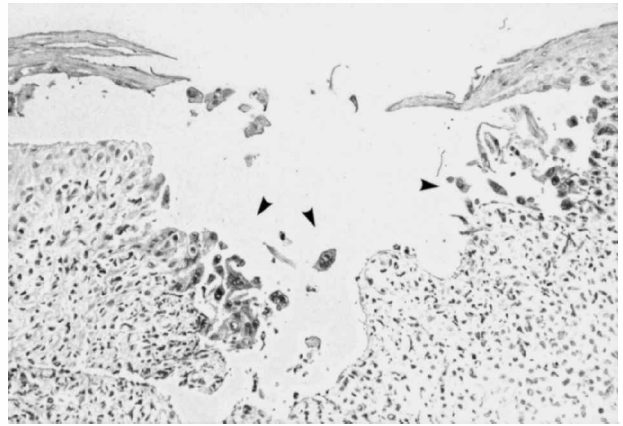


Fig. 3. Immunohistochemistry; positive reaction with herpes simplex virus polyclonal antibody (arrows). Several viral giant cells were also present (200 ×).

- of cytokines involved in atopic dermatitis by direct stimulation of human PBMC system. (*Comparison with steroids*). *Int Immunopharmacol* 2001; 1: 1219–1226.
3. Reitamo S, Wollenberg A, Schopf E, Perrot JL, Marks R, Ruzicka T, et al. Safety and efficacy of 1 year of tacrolimus ointment monotherapy in adults with atopic dermatitis. The European Tacrolimus Ointment Study Group. *Arch Dermatol* 2000; 136: 999–1006.
4. Kawakami T, Soma Y, Morita E, Koro O, Yamamoto S, Nakamura K, et al. Safe and effective treatment of refractory facial lesions in atopic dermatitis using topical tacrolimus following corticosteroid discontinuation. *Dermatology* 2001; 203: 32–37.
5. Nagington J, Rook A, Highet AS. Kaposi's varicelliform eruption. In: Rook A, Wilkinson DS, Ebling FJG, Champion RH, Burton JL, eds. *Textbook of dermatology*, 4th ed. Oxford: Blackwell Scientific Publications, 1986: 691–693.
6. Braun-Falco O, Plewig G, Wolff HH, Winkelmann RK. Eczema herpeticum. In: Braun-Falco O, Plewig G, Wolff HH, Winkelmann RK, eds. *Dermatology*. Berlin: Springer-Verlag, 1991: 26–27.
7. Lübke J, Pournaras CC, Saurat J-H. Eczema herpeticum during treatment of atopic dermatitis with 0.1% tacrolimus ointment. *Dermatology* 2000; 201: 249–251.