

## Identification of Herpes Simplex Virus DNA and Lack of Human Herpesvirus-8 DNA in Mycosis Fungoides

Emel Erkek<sup>1</sup>, Nilgün Sentürk<sup>1</sup>, Irem Dinçer<sup>2</sup>, Ali İlgin Olut<sup>2</sup>, Tanıl Kocagöz<sup>2</sup>, Gül Bükülmez<sup>1</sup> and Sedef Sahin<sup>1</sup>

Departments of <sup>1</sup>Dermatology and <sup>2</sup>Clinical Microbiology; Hacettepe University Faculty of Medicine, Neyzen Tevfik sokak, Ferah apt., 12/12 Maltepe, TR-06570 Ankara, Turkey. E-mail: emelerkek@hotmail.com

Accepted February 22, 2002.

Sir,

Human herpesvirus 8 (HHV-8) is the most recent putative human herpesvirus. Evidence was obtained using molecular biology techniques (1). Specific DNA sequences were first identified in 1994 by Chang et al. (2) in Kaposi's sarcoma tissues from patients with AIDS using the representational difference analysis technique. In the vast majority of cases, HHV-8 DNA sequences can be shown by polymerase chain reaction (PCR) in classical, endemic, iatrogenic and AIDS-associated Kaposi's sarcoma (1). HHV-8 is also lymphotropic and has the ability to immortalize cells (3, 4). The virus has been associated with peripheral T-cell lymphomas, plaque parapsoriasis, lymphomatoid papulosis and cutaneous T-cell lymphomas (CTCL), including mycosis fungoides (MF) (5–7). Herpes simplex virus (HSV) primarily targets epithelial and neural cells rather than lymphocytes. However, given the immunologic relationship between T lymphocytes and the epidermis, and the fact that MF often appears to be initiated as a cutaneous process, a potential role for HSV in the development or progression of MF has been suggested (8).

The purpose of this study was to elucidate a potential role for HHV-8 and HSV in the etiopathogenesis of MF.

### MATERIAL AND METHODS

Fifty formalin-fixed paraffin-embedded samples from lesional skin of 50 Caucasian patients with MF were selected and retrospectively collected from archival files of the Pathology Department. In a previous study performed in our department, these biopsy samples have been shown by PCR to be EBV negative (9). In all patients, the skin biopsies have been obtained during initial admission to hospital, before initiation of any form of therapy. Forty-three of the 50 patients were diagnosed as MF erythematous stage (86%) and 7 were MF plaque stage (14%). The patients were classified according to the TNM staging as follows: 19 of the 50 were stage IA (38%), 25 were stage IB (50%) and 6 were stage IIA (12%). Control skin samples were obtained from normal skin of 20 healthy individuals undergoing elective plastic surgery.

The patient and control samples were studied by PCR for the presence of HSV and HHV-8. All samples showed human  $\beta$ -globulin gene amplification by PCR, indicating the absence of major PCR inhibitors. The primers used in this study were first described by Chang et al. (2), and were specific for HHV-8. 5'TCCGTGTTGTCTACGTCCAG3' was used as the first primer, and 5'AGCCGAAAGGATTCCACCAT3' as the second. A positive control containing HHV-8 DNA was obtained from patients with HIV-associated Kaposi's sarcoma. For HSV, a target region of 342 base pairs between the 2348th and 2689th bases was selected on the viral genome: (HSV gB

2a-1) 5' CTG GTC AGC TTT CGG TAC GA 3', and (HSV gB 2a-2) 5' CAG GTC GTG CAG CTG GTT GC 3'. These primers have been amplifying both types of HSV, namely types I and II. As a positive control specimen, cerebrospinal fluid of a patient with a clinical and serologically proven HSV encephalitis was used.

### RESULTS AND DISCUSSION

Using PCR, we were able to amplify DNA specific for HSV from 16 of 50 MF patients (32%). Thirteen out of 16 HSV-positive samples were diagnosed as MF erythematous stage and 3 were MF plaque stage. All samples lacked HHV-8 DNA by PCR. Neither HSV nor HHV-8 was detected in any of the control specimens. The representative positive PCR results are shown in Figs 1 and 2.

HHV-8 is usually together with EBV as a dual infection in body cavity lymphomas, AIDS-related non-Hodgkin's lymphomas and in non-malignant lymphoid lesions (10, 11). In HIV+ patients, EBV and HHV-8 associated CTCL have been reported to take anaplastic large cell morphology (12). However, there was no evidence for the presence of EBV (9) and HHV-8 in lesional samples of our patients. This finding is in accordance with that of previous studies (5–7, 13–15) revealing the absence of HHV-8 in MF and suggesting that HHV-8 can be excluded from the list of potential etiological factors in MF.

The presence of both HSV-specific antigens and HSV DNA in lesions of CTCL has been reported previously (16, 17). However, no direct association between chronic HSV infection and the development of malignant lymphoma has been confirmed to date. Brice et al. (18) could not detect any HSV positivity among 30 patients with CTCL, 9 patients with lymphomatoid papulosis and 10 patients with pityriasis lichenoides et varioliformis acuta. In contrast, our study revealed the presence of HSV DNA in 16 of 50 (32%) lesional biopsy samples. There are previously reported cases of chronic, disseminated and fatal cases of HSV infections in CTCL, including MF (19, 20). The presence of HSV within MF lesions might reflect the immunodeficiency secondary to advanced disease or to immunosuppressive treatment. However, cutaneous biopsies in our study were obtained before therapy and none of the samples belonged to patients with advanced tumoral or erythrodermic MF. We believe that the role of HSV as an initiator or promoter in CTCL is worth investigating, and further

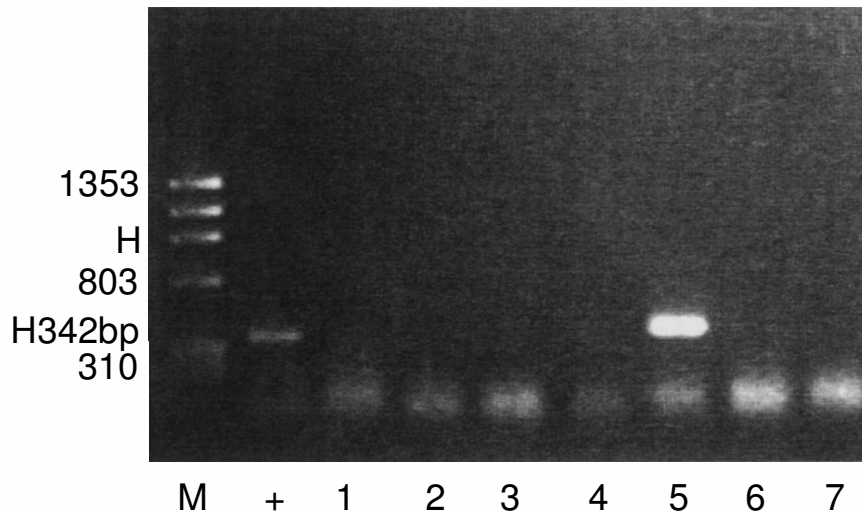


Fig. 1. PCR amplification of HSV-specific 342 bp DNA fragment in patients with mycosis fungoides (MF). M: molecular DNA weight marker; +: positive control for HSV; lane 1: negative control; lanes 2, 3, 4, 6, 7: negative patient samples; lane 5: positive HSV PCR amplification of a patient with MF.

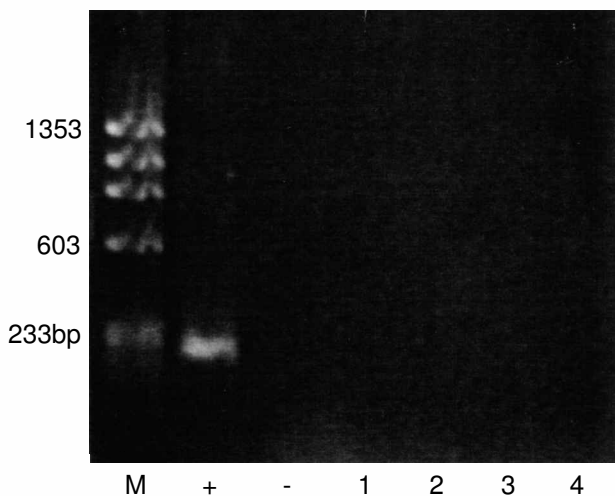


Fig. 2. PCR amplification of HHV-8 in patients with mycosis fungoides. M: molecular DNA weight marker; +: positive control for HHV-8; -: negative control; lanes 1, 2, 3, 4: negative patient samples.

studies in lesional and non-lesional biopsy specimens from patients with MF are awaited.

## REFERENCES

- Luppi M, Torelli G. The new lymphotropic herpesviruses (HHV-6, HHV-7, HHV-8) and hepatitis C virus (HCV) in human lymphoproliferative diseases: an overview. *Haematologica* 1996; 81: 265–281.
- Chang Y, Cesarman E, Pessin MS, Lee F, Culpepper J, Knowles DM, et al. Identification of herpesvirus-like DNA sequences in AIDS-associated Kaposi's sarcoma. *Science* 1994; 266: 1865–1869.
- Kemeny L, Gyulai R, Kiss M, Nagy F, Dobozy A. Kaposi's sarcoma-associated herpesvirus/human herpesvirus-8: a new virus in human pathology. *J Am Acad Dermatol* 1997; 37: 107–113.
- Lyons SF, Liebowitz DN. The roles of human viruses in the pathogenesis of lymphoma. *Semin Oncol* 1998; 25: 461–475.
- Sander CA, Simon M, Puchta U, Raffeld M, Kind P. HHV-8 in lymphoproliferative lesions in skin. *Lancet* 1996; 348: 475–476.
- Fossati S, Boneschi V, Ferruci S, Brambilla L. Human immunodeficiency virus negative Kaposi's sarcoma and lymphoproliferative disorders. *Cancer* 1999; 85: 1611–1615.
- Dupin N, Franck N, Calvez V, Gorin I, Grandadam M, Huraux JM, et al. Lack of evidence of human herpesvirus 8 DNA sequences in HIV-negative patients with various lymphoproliferative disorders of the skin. *Br J Dermatol* 1997; 136: 827–830.
- Diamandidou E, Cohen PR, Kurzrock R. Mycosis fungoides and Sezary syndrome. *Blood* 1996; 88: 2385–2409.
- Erkek E, Şahin S, Atakan N, Kocagöz T, Olut AI, Gököz A. Examination of mycosis fungoides for the presence of Epstein-Barr virus and human herpesvirus-6 by polymerase chain reaction. *J Eur Acad Dermatol Venereol* 2001; 15: 422–426.
- Cesarman E, Chang Y, Moore PS, Said JW, Knowles DM. Kaposi's sarcoma-associated herpesvirus-like DNA sequences in AIDS-related body-cavity-based lymphomas. *N Engl J Med* 1995; 332: 1186–1191.
- Luppi M, Barozzi P, Maiorana A, Artusi T, Travato R, Marasca R, et al. Human herpesvirus-8 DNA sequences in human immunodeficiency virus-negative angioimmunoblastic lymphadenopathy and benign lymphadenopathy with giant germinal center hyperplasia and increased vascularity. *Blood* 1996; 87: 3903–3909.
- Nakamura K, Katano H, Hoshino Y, Nakamura T, Hosono O, Masunaga A, et al. Human herpesvirus type 8 and Epstein-Barr virus-associated cutaneous lymphoma taking anaplastic large cell morphology in a man with HIV infection. *Br J Dermatol* 1999; 141: 141–145.
- Pastore C, Gloghini A, Volpe G, Nomdedeu J, Leonardo E, Mazza U, et al. Distribution of Kaposi's sarcoma herpesvirus sequences among lymphoid malignancies in Italy and Spain. *Br J Haematol* 1995; 91: 918–920.
- Henghold WB, Purvis SF, Schaffer J, Giam C-Z, Wood GS. No evidence of KSHV/HHV-8 in mycosis fungoides or associated disorders. *Cancer* 1999; 85: 1611–1615.
- Beylot-Barry M, Vergier B, Masquelier B, Bagot M, Joly P, Souteyrand P, et al. The spectrum of cutaneous

- lymphomas in HIV infection: a study of 21 cases. *Am J Surg Pathol* 1999; 23: 1208–1216.
16. Lee LA, Huff JC, Edmond BJ. Identification of herpes simplex virus antigens and DNA in lesions of mycosis fungoides. *J Invest Dermatol* 1983; 80: 333.
  17. Duvic M, Magee K, Storthz KA. In situ hybridization for herpes simplex virus in mycosis fungoides and alopecia areata. *J Invest Dermatol* 1989; 92: 423.
  18. Brice SL, Jester JD, Friednash M, Golitz LE, Leahy MA, Stockert SS, et al. Examination of cutaneous T-cell lymphoma for human herpesviruses by using the polymerase chain reaction. *J Cutan Pathol* 1993; 20: 304–307.
  19. Vonderheid EC, Milstein HJ, Thomson KD, Wu BC. Chronic herpes simplex infection in cutaneous T-cell lymphomas. *Arch Dermatol* 1980; 116: 1018–1022.
  20. Goldgeiger MH, Cohen SR, Braverman IM, Stenn KS. An unusual and fatal case of disseminated cutaneous herpes simplex. Infection in a patient with cutaneous T cell lymphoma (mycosis fungoides). *J Am Acad Dermatol* 1981; 4: 176–180.

## Cutaneous Sarcoidosis of the Scrotum: A Rare Manifestation of Systemic Disease

Susan S. McLaughlin, Allison M. Linquist, and Joseph W. Burnett

Department of Dermatology, University of Maryland School of Medicine, 405 West Redwood St., 6th Floor, Baltimore, MD 21201, USA. E-mail: ssmclaugh@hotmail.com

Accepted February 22, 2002.

Sir,

Sarcoidosis is a systemic granulomatous disease of unknown etiology that can affect various organs, such as the skin, lungs, heart, and eyes, as well as the lymph nodes. Although cutaneous findings in sarcoidosis may occur at any stage in the disease, they usually occur at the onset of disease. Skin lesions are present in up to 37% of patients (1). Cutaneous sarcoidosis is classified as specific (caused by non-caseating granulomas infiltrating the skin) and non-specific or reactive (such as erythema nodosum) (1). Although any part of the cutaneous surface may be involved, reports of genital sarcoidosis are rare. We describe an unusual case of cutaneous sarcoidosis involving the scrotum and penis.

### CASE REPORT

A 37-year-old African American male presented with a 3-month history of an extensive, pruritic, eczematous eruption of the scrotum, with associated edema and tenderness. Clusters of dark papules and plaques had developed on his face one month previously. The patient described having recent fevers, intermittent nausea and vomiting, difficulty urinating, and occasional wheezing but denied persistent shortness of breath. He had no family history of sarcoidosis.

Physical examination revealed an obese, hoarse man with multiple pink-to-violaceous annular papules and plaques on the face (lupus pernio), neck, arms, gluteal cleft, penis, and scrotum. No oral lesions were noted. Shotty, inguinal lymphadenopathy was noted bilaterally. The scrotum was massively enlarged, to approximately 18 cm in diameter, diffusely tender, and lichenified (Fig. 1). The penis was twice normal size and diffusely edematous.

Massive thickening of the scrotal wall was detected on ultrasound examination of the scrotum. The testes, epididymis, and blood vessels were normal. Mediastinal and hilar lymphadenopathy was evident on chest

roentgenogram. Results of pulmonary function tests were not available. No abdominal or pelvic lymphadenopathy was detected by computed tomography scan of the abdomen and pelvis. Direct laryngoscopic examination revealed nodular laryngeal and subglottal involvement. The serum angiotensin-converting enzyme level was elevated at 98 U/l (normal range, 20–60 U/l). A complete blood count, liver function panel, blood urea nitrogen, creatinine, and serum calcium and protein levels were all normal.

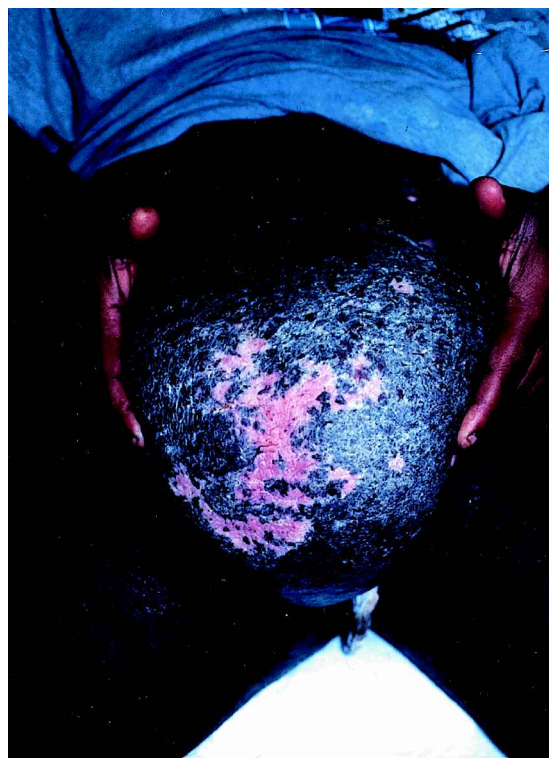

Fig. 1. Lichenified pink-to-violaceous papules and plaques cover the massively enlarged scrotum, which showed no improvement after a course of oral prednisone.

roentgenogram. Results of pulmonary function tests were not available. No abdominal or pelvic lymphadenopathy was detected by computed tomography scan of the abdomen and pelvis. Direct laryngoscopic examination revealed nodular laryngeal and subglottal involvement. The serum angiotensin-converting enzyme level was elevated at 98 U/l (normal range, 20–60 U/l). A complete blood count, liver function panel, blood urea nitrogen, creatinine, and serum calcium and protein levels were all normal.