

## CLINICAL REPORT

**A Novel Splice Site Mutation in Collagen Type VII Gene in a Chinese Family with Dominant Dystrophic Epidermolysis Bullosa Pruriginosa**

WEI JIANG, DINGFANG BU, YONG YANG and XUEJUN ZHU

*Department of Dermatology, First Hospital, Peking University, Beijing, China*

**Dystrophic epidermolysis bullosa pruriginosa, a subtype of epidermolysis bullosa dystrophica and a heterogeneous inherited disease, is characterized by pruritus, excoriated nodular prurigo-like lesions, skin fragility, altered anchoring fibrils and loss of dermal-epidermal adhesion. Mutation in type VII collagen gene (COL7A1) is thought to be implicated in the underlying change for dystrophic epidermolysis bullosa pruriginosa. We report here a large family of dominant dystrophic epidermolysis bullosa pruriginosa. Mutation analysis using polymerase chain reaction and direct sequencing demonstrated a novel nucleotide substitution of 6899A→G in exon 87 in one COL7A1 allele of the proband and 18 affected family members. This substitution was not found in 100 normal alleles. Polymerase chain reaction and sequencing of the cDNA, reverse transcribed from the proband's peripheral lymphocyte RNA, suggest that this mutation causes aberrant COL7A1 mRNA splicing of exon 87 skipping. Clinical features and pedigree analysis suggest that 6899A→G substitution is a mutation with full penetrance and variable expressivity. Key words: COL7A1 mutation; dystrophic epidermolysis bullosa; DEB pruriginosa.**

(Accepted April 3, 2002.)

Acta Derm Venereol 2002; 82: 187–191.

Xuejun Zhu, Department of Dermatology, Peking University First Hospital, Beijing 100034, China. E-mail: ZhuXJ@public.bta.net.cn

Dystrophic epidermolysis bullosa (DEB) is an inherited skin fragility disorder, with characteristic trauma-induced blistering associated with scarring and nail dystrophy (1). The ultrastructural hallmark of DEB is the separation in sub-lamina densa level of the dermal-epidermal junction, usually associated with abnormal quality or quantity of anchoring fibrils (2). DEB pruriginosa is a rare clinical type of DEB, characterized by marked itching and the presence of nodular prurigo-like or lichenoid lesions (3, 4). Autosomal dominant, autosomal recessive, and sporadic inheritance patterns have been described in this disease (4, 5). In this study,

we screened mutation in the COL7A1 gene in a Chinese family with dominant DEB pruriginosa.

## MATERIAL AND METHODS

*Patients*

The proband for scrutiny was a 35-year-old man suffering from moderate to severe pruritus with blisters or erosions over the extremities as a result of minor trauma or scratching. On examination (Fig. 1), we found nodular prurigo-like or lichenoid papules distributed mainly on the shins and the extensors of the forearms, and dystrophic toenails. The mucosae were not affected. All haematological and serum biochemical data were within normal range. Punch biopsy from lichenoid papules was obtained for histopathological, indirect immunofluorescence and electron microscopy examinations.

The proband was from a large family with 59 known cases of similar skin symptoms (Fig. 2). We did not find any atopic history in the family.

*Indirect immunofluorescence*

Indirect immunofluorescence study for collagen VII antigen in the dermal-epidermal junction was performed on frozen skin sections using monoclonal antibody LH 7:2 (a gift from Dr Jouni Uitto, USA), which specifically recognizes the NC-1 region of collagen VII (6).

*Electron microscopy studies*

For transmission electron microscopy examination, a skin sample (0.5 cm) was fixed in 2.5% glutaraldehyde then in 0.1M

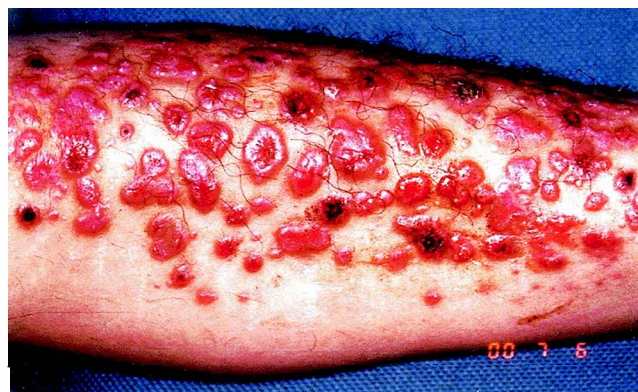

Fig. 1. Nodular prurigo-like papules on the extensor of the lower limb of the proband.

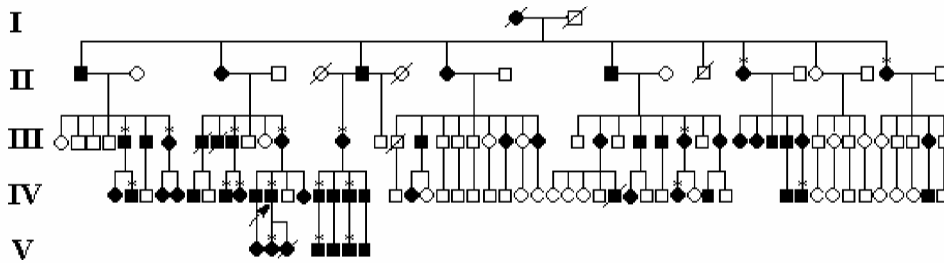


Fig. 2. Pedigree of the dominant dystrophic epidermolysis bullosa (DEB) pruriginosa family through 5 generations. Filled symbols indicate individuals known to carry the disease. Arrow indicates the proband. \*Patients from whom blood samples were available.

phosphate buffer, postfixed in OsO<sub>4</sub>, dehydrated in ethanol and embedded in epoxy resin. An ultra-thin section was stained with uranyl acetate and lead citrate and examined using a JEOL 100 CX-II electron microscope.

#### Mutation detection

Genomic DNA was extracted from peripheral blood lymphocytes of the proband and 18 other affected family members available for study by standard method (7). Polymerase chain reaction (PCR) was used to amplify all of the 118 exons of the COL7A1 gene from the proband's genomic DNA using oligonucleotide primer pairs described elsewhere (according to GenBank accession numbers L02870 and L23982) (8). Specifically, the following primers were used to amplify a 404-bp segment spanning exons 86–87 and their flanking intron sequences: left primer, 5'-GTC AAG GGT TGG GCT CCA GG; right primer, 5'-TGG AAA CAG GCT TGT GGG TG. The amplification condition was 94°C for 5 min, followed by 94°C for 45 s, 63°C for 45 s, and 72°C for 45 s for 33 cycles in a total volume of 50 µl containing 100–200 ng genomic DNA, 1 × PCR buffer, 1.5 mM MgCl<sub>2</sub>, 10 pmol of each primer and 1.25U of Taq DNA polymerase. The PCR product was purified in a 1.5% agarose gel and then subjected to direct sequencing on an automated DNA sequencer (ABI Prism 377 Sequencer).

#### PCR using allele-specific oligonucleotide primers

We used allele-specific oligonucleotide primers to detect the nucleotide substitution of 6899A→G in 20 members of this family (including one healthy member and 19 patients) and 50 unrelated healthy individuals. Primers for wild-type allele: left, 5'-ACA GGG GTC TCC AGG TTT GC; right, 5'-GAA GTC AGG GTC AAA GAT CAC CT. Primers for mutant allele: left, 5'-ACA GGG GTC TCC AGG TTT GC; right, 5'-GAA GTC AGG GTC AAA GAT CAC CC. The expected product size is 402 bp.

#### Reverse transcription polymerase chain reaction and sequencing

To examine the consequences of the 6899A→G transition in exon 87, reverse transcription-PCR (RT-PCR) was performed using total RNA extracted from the proband's peripheral lymphocytes. cDNA was generated from the total RNA by random priming and reverse transcription. cDNA 6783–7083 (numbering from the A of the translation initiation codon ATG), which includes the part transcribed from exons 86–92, was amplified by PCR using exonic primers: sense primer 5'-AGATGGTGCCAGTGGAAAAG (6783–6802) and antisense primer 5'-AGCCCTTTTCTGACCATCTT (7083–7062). The size of a normal PCR product should be 301 bp. The amplification condition was 94°C for 2 min, followed by 94°C for 45 s, 60°C for 45 s, and 72°C for 45 s, for 33 cycles.

The PCR product was purified in 2% agarose gel and cloned into pBluescript Sk+ Vector (Stratagene). Recombinant plasmids were sequenced on an ABI Prism 377 Sequencer, using T7 primer.

## RESULTS

#### Histopathologic, immunofluorescent and electron microscopic studies

Examination of the proband's skin specimen by light microscopy showed compact hyperkeratosis, mild acanthosis, dermal-epidermal separation and dense fibrosis in the upper dermis (results not shown). Indirect immunofluorescent study, using monoclonal antibody LH 7:2 recognizing collagen VII, revealed bright and linear fluorescence located in the dermal-epidermal junction (results not shown). Electron microscopic examination of a lichenoid, papular lesion showed abnormal high density of collagen bundles beneath the dermal-epidermal junction (results not shown).

#### Mutation detection, including screening of other family members

All exons and their flanking regions of the COL7A1 gene of the proband were scanned by PCR amplification and direct sequencing. The proband showed an A-to-G transition at nucleotide 6899 (numbering from the A of the translation initiation codon ATG) in one allele (Fig. 3). This point mutation is located in exon 87 at –2 of the donor site. We performed PCR using allele-specific oligonucleotide primers to detect the nucleotide substitution of 6899A→G in 20 family members (19 patients and 1 healthy member) and 50 unrelated healthy individuals. In 19 patients, the 402 bp fragment could be amplified by PCR using primers either for wild-type allele or for mutant allele. One of the PCR products was sequenced and demonstrated a heterozygous 6899A→G mutation. In the healthy family member and 50 unrelated healthy individuals, however, this fragment could be amplified by PCR using primers only for the wild-type allele. One of these PCR products was sequenced and showed a homozygous A at nucleotide 6899.

Eighteen other DEB pruriginosa patients in this family were examined clinically. As shown in Table I, their age at onset, area and severity of the skin symptoms varied

Table I. Clinical features of 19 patients available for examination

Patient <sup>a</sup>	Age (years)	Age at onset	Location of skin lesions	Pruritus <sup>#</sup>	Nail involvement
II-13	72	7–8	Legs, mostly on shins	+	Toenail atrophy
II-17	66	1	Limbs	++	Toenail absent
III-5	48	5–6	Limbs, and hands	–	Absent
III-7	41	4–5	Hands, feet, elbows and knees	+ / + +	Toenail absent
III-10	50	1	Legs, elbows and ankles	+ / + +	Nail thickness
III-13	63	1	Trunk and limbs	++	Nail thickness, and toenail absent
III-14	62	10	Legs and forearms	++	Absent
III-30	1	7–8	Limbs	++	Atrophy
IV-2	13	5	Limbs, hands and feet	–	Toenail absent
IV-8	13	0.1	Legs	+ / + +	Atrophy
IV-9	22	8	Trunk, elbows and knees	+	Toenail absent
IV-11 (proband)	35	3	Limbs	++	Toenail absent and nail thickness
IV-14	42	10	Limbs	++	Nail thickness
IV-16	38	4–5	Limbs	++	Thickness
IV-36	29	4–5	Legs and forearms	++	Nail thickness and toenail atrophy
IV-41	17	2	Legs, hands, elbows and back	+	Toenail dysmorphia
V-2	10	1	Limbs, hands and feet	++	Toenail atrophy
V-4	16	5–6	Trunk, limbs	++	Normal
V-6	13	4–5	Legs and feet	+	Thickness

<sup>a</sup>For details see Fig. 2. All were found to have heterozygous 6899 A→G substitution in the COL7A1 gene.

<sup>#</sup>Severity of pruritus: – = no; + = mild; ++ = severe.

considerably. However, all of them bore a substitution of 6899A→G in one of the COL7A1 alleles, as identified by PCR using allele-specific oligonucleotide primers.

#### RT-PCR analysis

RT-PCR of total RNA from the proband's peripheral lymphocytes revealed two bands on agarose electrophoresis: a band of normal size (301 bp) and an extra band of smaller size (232 bp) (Fig. 4A). After cloning of the PCR products into plasmids and sequencing of the recombinant plasmids, two kinds of DNA sequence were obtained. One had a normal sequence and the other lost 69 bp nucleotides corresponding to those of the entire exon 87 (Figs 4B and 4C) and resulting in the deletion of 23 amino acid residues in the COL7A1 polypeptide.

#### DISCUSSION

The term "epidermolysis bullosa pruriginosa" was proposed by McGrath et al. (4). DEB pruriginosa is a rare form of DEB, characterized by intense pruritus usually accompanied by nodular prurigo-like lesions and lichenoid papulars, hypertrophic violaceous scars and nail dystrophy. Blisters and erosions may not be evident clinically. This condition must be distinguished clinically from a variety of acquired inflammatory dermatoses, such as hypertrophic lichen planus, keratosis lichenoides chronica, nodular prurigo and dermatitis artefacta (5).

Here we report on a large Chinese family with 59 patients in which indirect immunofluorescent and histo-

pathological features of the proband confirmed the clinical diagnosis of DEB pruriginosa. In this family, we found a 6899A→G mutation in the COL7A1 gene, which is located at –2 of the donor site of exon 87 and was not reported previously (9–11). This mutation was closely linked to the individuals with DEB pruriginosa in this family and was not found in 50 normal, unrelated individuals. Therefore, it is likely to be a pathogenic mutation that caused DEB pruriginosa in this family.

This mutation may affect the splicing of the corresponding exon, because the A nucleotide in donor position –2 in human genes is relatively conserved in 58% of the splice junctions (12). Another possibility is that it may change the codon glutamine (CAG) at 2,300 to arginine (CGG) in COL7A1 mRNA (Fig. 4). We therefore performed RT-PCR and cloning of the RT-PCR product. Sequencing of the recombinant clones revealed a normal sequence in one clone and skipping of exon 87 in the other clones, confirming that the 6899A→G substitution is a splicing mutation. Because exon 87 consists of 69 bp, which in-frame codes for 23 amino acids, the mutant COL7A1 mRNA is predicted to code an  $\alpha 1(VII)$  collagen polypeptide that is internally shortened by 23 amino acids. The deleted segment resides within the collagenous domain of 8 Gly-X-Y triple repeat sequences. In many studies the importance of the Gly-X-Y repeat sequence in type VII collagen (13–15) has been demonstrated, therefore the mutation delineated in this study is apparently the pathogenic genotype of DEB pruriginosa in this family.

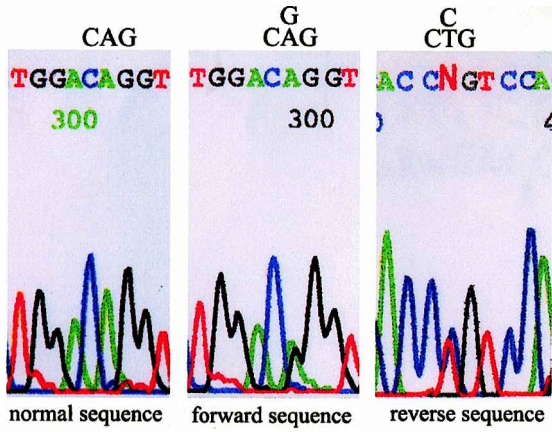


Fig. 3. Direct sequencing of the polymerase chain reaction (PCR) products from genomic DNA of the proband (middle and right) and a normal control (left). The proband shows a heterozygous mutation of A-to-G transition at position 6899.

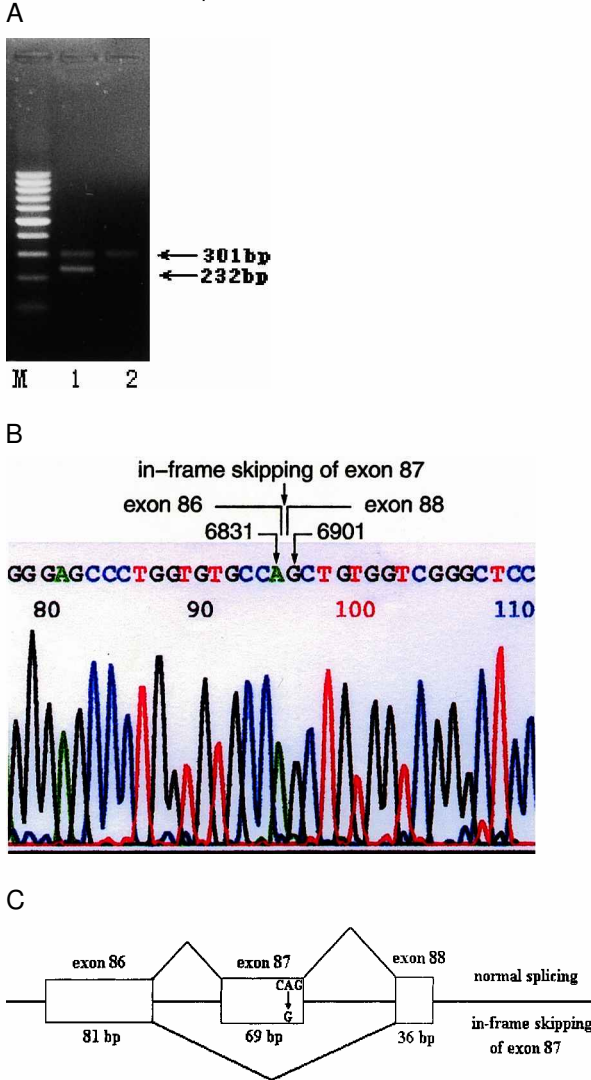


Fig. 4. (A) Agarose electrophoresis of the RT-PCR products showing a homoduplex 301 bp of COL7A1 cDNA band in an unrelated control individual (lane 2), whereas two bands, 301 bp and 232 bp, are seen in the proband (lane 1). Sequencing of the clone containing the 232 bp demonstrates the deletion of 69 bp (B), suggesting the in-frame skipping of exon 87 (C).

In this pedigree, all of the offspring from normal parents were normal (see II-8, III-16, 18–21, 23, 38–44, and 46 in Fig. 2), and roughly half of the progeny from a DEB pruriginosa parent was abnormal. This suggests that the 6899 A→G substitution is a mutation with full penetrance, though we had only one normal individual in this family with the consent of mutation screening. Moreover, patients in this family showed variable clinical features in age at onset, area and severity of skin lesion. Other factors (genetic and environmental) responsible for the variable expressivity of DEB pruriginosa need to be studied further.

ACKNOWLEDGEMENTS

We thank Aie Xu, Dejin Wang and Yiling Wang of the Department of Dermatology, Hangzhou Third People's Hospital, for providing clinical information.

REFERENCES

1. Fine JD, Bauer EA, Briggaman RA, Carter DM, Eady RAJ, Esterly NB, et al. Revised clinical and laboratory criteria for subtypes of epidermolysis bullosa. *J Am Acad Dermatol* 1991; 24: 119–135.
2. Tidman MJ, Eady RAJ. Evaluation of anchoring fibrils and other components of the dermal-epidermal junction in dystrophic epidermolysis bullosa by a quantitative ultrastructural technique. *J Invest Dermatol* 1985; 84: 374–377.
3. Fine JD, Eady RAJ, Bauer EA, Briggaman RA, Bruckner-Tuderman L, Christiano A, et al. Revised classification system for inherited epidermolysis bullosa: report of the second international consensus meeting on diagnosis and classification of epidermolysis bullosa. *J Am Acad Dermatol* 2000; 42: 1051–1066.
4. McGrath JA, Schofield OMV, Eady RAJ. Epidermolysis bullosa pruriginosa: Dystrophic epidermolysis bullosa with distinctive clinicopathological features. *Br J Dermatol* 1994; 130: 617–625.
5. Cambiagli S, Brusasco A, Restano L, Cavalli R, Tadini G. Epidermolysis bullosa pruriginosa. *Dermatology* 1997; 195: 65–68.
6. Christiano AM, Fine JD, Uitto J. Genetic basis of dominantly inherited transient bullous dermolysis of the newborn: a splice site mutation in the type VII collagen gene. *J Invest Dermatol* 1997; 109: 811–813.
7. Sambrook J, Fritsch EF, Maniatis T. *Molecular cloning: a laboratory manual*. New York: Cold Spring Harbor Laboratory Press, 1989.
8. Christiano AM, Hoffman GG, Zhang X, Xu Y, Tamai Y, Greenspan DS, Uitto J. Strategy for identification of sequence variants in COL7A1 and a novel 2-bp deletion mutation in recessive dystrophic epidermolysis bullosa. *Hum Mutat* 1997; 10: 408–414.
9. Lee JY-Y, Pulkkinen L, Liu H-S, Chen Y-F, Uitto J. A glycine-to-arginine substitution in the triple-helical domain of type VII collagen in a family with dominant dystrophic epidermolysis bullosa pruriginosa. *J Invest Dermatol* 1997; 108: 947–949.
10. Mellerio JE, Ashton GH-S, Mohammadi R, Lyon CC, Kirby B, Harman KE, et al. Allelic heterogeneity of dominant and recessive COL7A1 mutations underlying

- epidermolysis bullosa pruriginosa. *J Invest Dermatol* 1999; 112: 984–987.
11. Shimizu H, Hammami-Hauasli N, Hatta N, Nishikawa T, Bruckner-Tuderman L. Compound heterozygosity for silent and dominant glycine substitution mutations in COL7A1 leads to a marked transient intracytoplasmic retention of procollagen VII and a moderately severe dystrophic epidermolysis bullosa phenotype. *J Invest Dermatol* 1999; 112: 419–421.
  12. Shapiro MB, Senapathy P. RNA splice junctions of different classes of eukaryotes: sequence statistics and functional implications in gene expression. *Nucl Acids Res* 1987; 15: 7155–7174.
  13. Christiano AM, Hoffman GG, Chung-Honet LC, Lee S, Cheng W, Uitto J, Greenspan DS. Structural organization of the human type VII collagen gene (COL7A1), composed of more exons than any previously characterized gene. *Genomics* 1994; 21: 169–179.
  14. Kon A, Pulkkinen L, Ishida-Yamamoto A, Hashimoto I, Uitto J. Novel COL7A1 mutations in dystrophic forms of epidermolysis bullosa. *J Invest Dermatol* 1998; 111: 534–537.
  15. Whittock NV, Asthon GH-S, Mohammedi R, Mellerio JE, Mathew CG, Abbs SJ, et al. Comparative mutation detection screening of the type VII collagen gene (COL7A1) using the protein truncation test, fluorescent chemical cleavage of mismatch, and conformation sensitive gel electrophoresis. *J Invest Dermatol* 1999; 113: 673–686.