

## Cold Urticaria and Angiotensin Converting Enzyme Inhibitor

Birger Kränke and Sigrid Mayr-Kanhäuser

Department of Dermatology and Venereology, University of Graz, Auenbruggerplatz 8, A-8036 Graz, Austria. E-mail: birger.kraenke@kfunigraz.ac.at

Accepted January 23, 2002.

Sir,

Acquired cold urticaria (ACU) is a frequent and sometimes harmful variant of physical urticaria, and is inducible through exposure to cold objects (1, 2). The most common form is idiopathic (primary) ACU with unknown etiology, but in cases of association with cryoglobulins, cryofibrinogens or infectious diseases the entity can occasionally be classified as secondary (1). Consequently, a careful history-taking and physical examination are sufficient for making a diagnosis; an exhaustive search for the cause is generally not recommended (1). However, with this case we present a pathogenetic concept for a potentially life-threatening triggering of a pre-existing ACU by drug intake.

### CASE REPORT

We report the case of a 43-year-old male Caucasian patient who complained of localized itching and urticaria upon exposure to cold air, water and other cold objects over the course of 10 years. Therapeutic trials had not been performed because of his mild symptoms, even in the case of bathing or swimming. In December 1999, he suffered for the first time from a generalized urticaria upon cold exposure, and from 1 month later up to the time of presentation in June 2000 he had repeatedly noticed a deep and long-lasting skin swelling of the contact areas. Furthermore, after swimming in a pool with a water temperature of 24°C he developed a generalized urticaria, angioedema of the extremities and chest, dizziness, nausea and dyspnoea. The patient consequently had to be transported to an emergency ward for therapy, and thereafter was referred to our allergy unit for further diagnostic measurement.

Exact history-taking revealed an essential hypertension and reflux esophagitis for 2 years, but family history was negative for urticaria, especially cold urticaria. There was no history of recent immunization, stinging insect allergy, urticaria or angioedema other than with cold exposure. Medication at the time of presentation was omeprazol (Losec 20 mg; Astra, Germany), and in December 1999 the patient was started on a compound (Acecomb, Zeneca, Germany) of lisinopril (20 mg) and hydrochlorothiazide (25 mg).

### Diagnostic evaluation

The ice-cube and cold-water immersion tests were performed according to the recommendations of the

EAACI (1): a glass tube filled with ice water was fixed on the volar aspect of the upper left arm and the right hand was immersed in chilled water (4°C). Both tests were strongly positive after 1 min, such that the glass tube had to be removed and the immersion test stopped (Fig. 1). Additionally, the following diagnostic evaluation was performed: laboratory tests (total and differential blood cell count, erythrocyte sedimentation rate, acute phase proteins, enzyme screening, antistreptolysine titre, screening tests for virus antibodies (Epstein-Barr virus, measles virus, cytomegalovirus, varicella-zoster virus, herpes simplex virus and human immunodeficiency virus) as well as cryoglobulins and cold agglutinins, C1-inhibitor activity, complement 4 and urinalysis), X-ray examination of the chest and paranasal sinuses and screening for *Helicobacter pylori* infection (test for antibodies, <sup>13</sup>C urea breath test) (3). The results of all these tests were within the normal range, this suggesting a diagnosis of primary ACU.

### Clinical course

In a prophylactic trial, we replaced on the day of presentation the angiotensin converting enzyme (ACE) inhibitor therapy with Co-Diovan® (Novartis, Switzerland) containing angiotensin II type 1 receptor blocker valsartan (80 mg) and hydrochlorothiazide (12.5 mg). An antihistamine regimen was not prescribed. The patient was then advised to record his state of health for 6 months. After 4 weeks, 8 weeks, 12 weeks and 24 weeks, respectively, he reported only mild

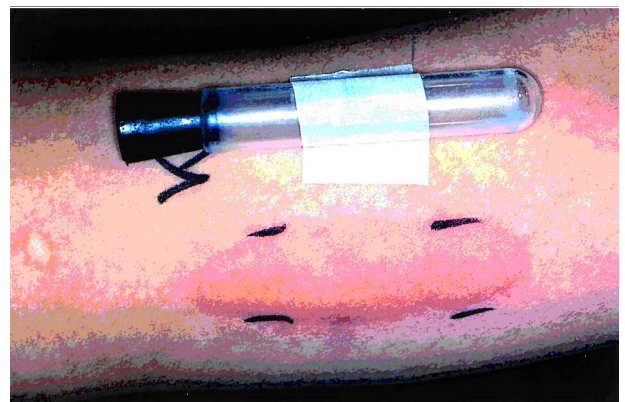


Fig. 1. Clinical presentation of the cold provocation test on the upper left arm in a patient with ACE inhibitor therapy. Massive localized oedema and marginal erythema appeared 1 min after the beginning of provocation.

symptomatology on exposure to cold (swimming); the ice-cube and cold-water immersion tests were repeated with incremental exposure times (1 min, 3 min, 5 min). Both tests were negative after 1 and 3 min, but resulted in mild local oedema after an exposure time of 5 min.

## DISCUSSION

Cold urticaria, as a frequent variant of physical urticaria, is a strikingly chronic disease, and the majority of patients suffer from cold-induced symptoms for years (4). Generalized weals due to aquatic activities are commonly seen on these patients, and in a proportion of more than 40% shock-like reactions will develop (5). In the latter patients, a cold stimulation time test of less than 3 min indicates the severity of cold urticaria, as was seen in our patient while he received ACE inhibitor therapy.

Data from the literature suggest that histamine – in contrast to other variants of urticaria – may not be the principal mediator of the vascular response to cold challenge in ACU. In 1968, DeLaus & Winkelmann (6) reported that bradykinin was produced as a mainly inflammatory mediator in the cold-provoked weals of 11 patients with cold urticaria. Later on, participation of the kallikrein-kinin system in the formation of cold-induced weals has been suggested by various authors (7, 8). Because treatment with ACE inhibitors was recently shown to increase weal and flare reactions to cutaneous applied bradykinin (9), we decided to change the antihypertensive therapy in our patient. ACE inhibitor therapy has been associated with elevated plasma kinin levels (10), and we believe this elevation was responsible for life-threatening attacks in this patient with long-standing ACU.

The mainstay of ACU therapy is awareness, avoidance of the inciting stimulus “cold”, and finally it may be symptomatic by applying antihistamines (1, 6). However, identifying and avoidance of drugs known to

trigger or potentiate mediator effects are essential in preventing more severe adverse events in ACU patients. We therefore recommend avoidance of ACE inhibitor therapy in patients with cold urticaria – analogous to avoidance in patients with hereditary angioedema, who are known to have elevated bradykinin levels (11).

## REFERENCES

1. Kontou-Fili K, Borici-Mazi R, Kapp A, Matjevic LJ, Mitchel FB. Position paper. Physical urticaria: classification and diagnostic guidelines. *Allergy* 1997; 52: 504–513.
2. Mathelier-Fusade P, Aissaoui M, Bakhhos D, Chabane MH, Leynadier F. Clinical predictive factors of severity in cold urticaria. *Arch Dermatol* 1998; 134: 106–107.
3. Kränke B, Mayr-Kanhäuser S, Aberer W. *Helicobacter pylori* in acquired cold urticaria. *Contact Dermatitis* 2001; 44: 57–58.
4. Kozel MMA, Mekkes JR, Bossuyet PMM, Bos JD. Natural course of physical and chronic urticaria and angioedema in 220 patients. *J Am Acad Dermatol* 2001; 45: 387–391.
5. Wanderer AA, Grandel KE, Wassermann SI, Farr RS. Clinical characteristics of cold induced systemic reactions in acquired cold urticaria syndrome: recommendations for prevention of this complication and a proposal for a diagnostic classification of cold urticaria. *J Allergy Clin Immunol* 1986; 78: 417–423.
6. DeLaus FV, Winkelmann RK. Kinins in cold urticaria. *Arch Dermatol* 1968; 98: 67–74.
7. Michaelsson G. Chronic urticaria. *Acta Derm Venereol* 1969; 49: 404–416.
8. Martens BPM, Berrens L. Enzyme activation and inhibition induced by cold provocation in a patient with cold urticaria. *Acta Derm Venereol* 1975; 55: 121–125.
9. Anderson MW, DeShazo RD. Studies of the mechanism of angiotensin-converting enzyme (ACE) inhibitor-associated angioedema: the effect of an ACE inhibitor on cutaneous responses to bradykinin, codeine, and histamine. *J Allergy Clin Immunol* 1990; 85: 856–858.
10. Pellacani A, Brunner HR, Nussberger J. Plasma kinins increase after angiotensin-converting-enzyme inhibition in human subjects. *Clin Sci* 1994; 87: 567–574.
11. Nussberger J, Cugno M, Amstutz C, Cicardi M, Pellacani A, Agostoni A. Plasma bradykinin in angioedema. *Lancet* 1998; 351: 1693–1697.

---

## Association of HIV Infection, Pyoderma Gangrenosum and Psoriasis

Alexander Kreuter, Thilo Gambichler, Klaus Hoffmann, Peter Altmeyer and Norbert H. Brockmeyer

Department of Dermatology, Ruhr-University Bochum, Gudrunstrasse 56, D-44791 Bochum, Germany. E-mail:

A.Kreuter@derma.de

Accepted January 28, 2002.

Sir,

Pyoderma gangrenosum usually occurs in immunocompetent individuals suffering from ulcerative colitis, M. Crohn, M. Bechterew or lupus erythematosus. Pyoderma gangrenosum has also been described in immunosuppressed patients with haematologic

malignancies, hypogammaglobulinemia or IgA-deficiency (1, 2). Only a few patients with HIV-associated pyoderma gangrenosum have been reported to date (3–5). We here report a HIV-positive patient with simultaneous exacerbation of pyoderma gangrenosum and psoriasis.