

A Case of Primary Cutaneous Actinomycosis

Clara Romano¹, Lucia Massai¹, Giovan Battista De Aloe¹, Karin Schurfeld² and Clelia Miracco²

¹Institute of Dermatological Science and ²Institute of Pathological Anatomy and Histology, University of Siena, Via Monte Santo, 3, I-53100 Siena, Italy. E-mail: mondelli@unisi.it

Accepted January 28, 2002.

Sir,

Actinomycetes are Gram-positive anaerobic bacteria present as saprophytes in the soil as well as in the oral and sometimes vaginal mucosa. *Actinomyces israeli*, and less often *A. meyeri*, *A. naeslundii*, *A. viscosus* and *A. odontolyticus*, cause chronic granulomato-suppurative infections of the neck and face, lungs, intestine (predominantly caecum) and pelvic area. Disseminated forms of infection have been reported (1) as well as uncommon primary cutaneous cases. Infection is generally contracted endogenously from tooth and gum disease. Although it occurs worldwide, it has a higher incidence in farm workers of rural tropical regions, possibly related to poor oral hygiene and limited use of antibiotics effective against actinomycetes in these areas. Here we report an immunocompetent patient with primary cutaneous actinomycosis.

CASE REPORT

A 74-year-old man presented with a painless perineal nodule at the base of the scrotum. The nodule was 12 mm in diameter, soft to elastic in consistency, erythematous and suppurative. It developed in the site of an excoriation received during hunting, appearing about 1 month after the wound, which had healed completely at the time of observation. Medical history included chronic periodontitis. The patient had received periodontal care 5–6 months before the nodule appeared. The dentist reported severe gingival disease with sites of chronic infection, but did not observe lesions suggesting actinomycosis. The patient consulted a surgery department where the lesion was removed. Histological examination at scanning power revealed amorphous eosinophilic aggregates with fringed edges, embedded in fibrotic stroma in the dermis, with some monocytic inflammatory infiltrate. Special stains revealed the aggregates to consist of filamentous Gram-positive structures (Fig. 1). Culture of biopsy fragments on brain-heart dextrose agar at 37°C, performed in the Mycology Laboratory of the Institute of Dermatology, produced colonies of *Actinomyces israeli*. There were no cervicofacial, thoracic or abdominal lesions. Chest X-ray and abdominal ultrasonography and X-ray were negative. Routine blood chemistry and lymphocyte subpopulations were within normal limits. The patient was treated with 200 mg/day oral minocyclin for 45 days. Follow-up 1 year later was negative.

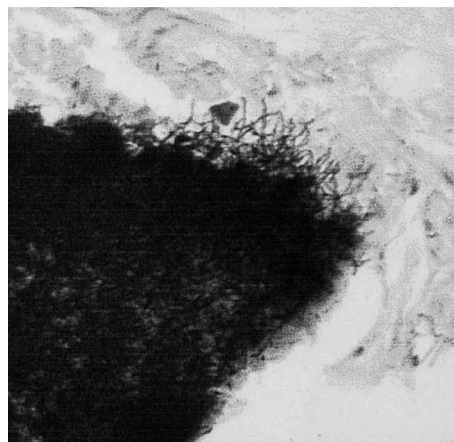


Fig. 1. Filamentous structures at periphery of Gram-positive bacterial colony (Gram ×400).

DISCUSSION

Diagnosis of cutaneous actinomycosis was based on histological examination, which revealed filamentous Gram-positive structures, and on isolation of *A. israeli* in skin biopsy culture. In the absence of demonstrable localizations in other sites, the infection was presumed to be linked to perineal trauma and classified as primary.

Cutaneous localizations of actinomycosis generally occur by contiguity of underlying foci of tooth or lung infection, by direct inoculation, or by spread through the bloodstream during a septicemic phase of the infection. In the latter case, there are often multiple lesions. Post-traumatic actinomycosis and cases due to insect bites have also been described. Primary infections of the rectum (2, 3) and rarely of the perianal area (4, 5), perianal and buttock area (6) and abdominal wall (7, 8) have been reported. These infections were presumably related to previous surgery sometimes undergone many years earlier.

Cutaneous actinomycosis manifesting with nodular lesions that tend to form fistulae needs to be differentiated clinically from other chronic inflammatory skin diseases, such as cutaneous tuberculosis, tertiary syphilis, sporotrichosis, lymphogranuloma venereum and nocardiosis. Diagnosis is based on identification of sulphur granules, usually 1–2 mm in diameter, in pus and histological preparations, and preferably also on culture. The histological picture is one of suppurative inflammation with abscesses and pus-filled sinus tracts in which bacteria form typical granular colonies composed of radiating Gram-positive filaments. Anaerobic culture at 37°C

produces glistening, white, nodular colonies in a few days.

Cutaneous actinomycosis is treated surgically followed by antibiotics, the most widely used of which are long-term penicillin, tetracyclin and erythromycin. Doses and treatment period are variable, since the best dosage is unknown (5). In our case, characterized by a single, exclusively cutaneous lesion, brief treatment was sufficient as recently reported in the literature (9).

REFERENCES

1. Apothéloz C, Regamey C. Disseminated infection due to *Actinomyces meyeri*: case report and review. *Clin Infect Dis* 1996; 22: 621–625.
2. Morson BC. Primary actinomycosis of the rectum. *Proc R Soc Med* 1961; 54: 723–724.
3. Fry GA, Martin WJ, Dearing WH, Culp CE. Primary actinomycosis of the rectum with multiple perianal and perineal fistulae. *Mayo Clin Proc* 1965; 40: 296–299.
4. Harris GJ, Metcalf AM. Primary perianal actinomycosis. Report of a case and review of the literature. *Dis Colon Rectum* 1988; 31: 311–312.
5. Alvarado-Cerna R, Bracho-Riquelme R. Perianal actinomycosis – a complication of a fistula in ano: report of a case. *Dis Colon Rectum* 1994; 37: 378–380.
6. Gayraud A, Grosieux-Dauger C, Durlach A, Salmon-Ehr V, Elia A, Grosshans E, et al. Cutaneous actinomycosis localized on the perianal area and buttocks. *Ann Dermatol Venereol* 2000; 127: 393–396.
7. Aulahi A. Primary cutaneous actinomycosis. *BMJ* 1977; 24: 828–829.
8. Ramirez O, De Linares IM, Astacio JN. Primary abdominal actinomycosis. Report of a case. *Med Cutan Ibero Lat Am* 1984; 12: 29–32.
9. Wee SH, Chang SN, Shim JY, Chun SI, Park WH. A case of primary cutaneous actinomycosis. *J Dermatol* 2000; 27: 651–654.

Self-healing Juvenile Cutaneous Mucinosis in an Infant

Klilah Hershko, Efraim Sagi and Arieh Ingber

Department of Dermatology, Hadassah University Hospital, Jerusalem, Israel 91120. E-mail: alon_hershko@hotmail.com

Accepted January 9, 2002.

Sir,

Self-healing juvenile cutaneous mucinosis (SHJCM) is a very rare disease characterized by the rapid onset of asymptomatic papules and nodules with predilection to face and periarticular regions, mild or absent inflammatory symptoms, lack of extra-cutaneous involvement and spontaneous and complete resolution of the skin lesions within weeks to months.

The first cases diagnosed with SHJCM were published in the French medical literature, and subsequently 5 additional patients were reported (1, 2). The youngest patient was a 5-year-old boy (3). We describe a case of SHJCM in a 1-year, 9-month-old girl.

CASE REPORT

The otherwise healthy girl was referred to the emergency room with a history of rapidly enlarging subcutaneous masses over her face, trunk and the periarticular regions on her hands (Fig. 1). Because of the unusual appearance of the skin lesions, a full investigation including skin biopsy was recommended but her parents declined. The child returned to the emergency room 3 weeks later because of further enlargement of the existing lesions and the appearance of new lesions. The rest of her physical examination was unremarkable.

Blood tests, including a complete blood count, erythrocyte sedimentation rate, liver, kidney and thyroid functions, serum protein electrophoresis and whole body computerized tomography were normal.

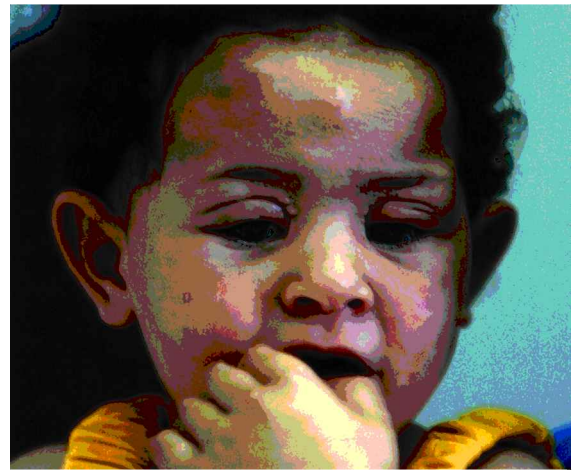

Fig. 1. Subcutaneous nodules over the face, eyelids and periarticular areas of the hands.

Excision biopsies from lesions on the skull and hands revealed normal epidermis and focal deposition of amorphous material within the dermis, in particular the upper dermis. This material stained positively with alcian blue at pH 2.5, and negatively with periodic acid-Schiff (Fig. 2). The interpretation of these biopsies was consistent with cutaneous mucinosis, and in view of her age and clinical presentation the patient was diagnosed as having SHJCM. Consequently, no treatment was recommended. At a follow-up visit 3 months later, all her lesions had resolved completely.