

## CLINICAL REPORT

**Benign Neonatal Hemangiomatosis with Conjunctival Involvement***Report of a Case and Review of the Literature*EMEL BÜLBÜL BASKAN<sup>1</sup>, MEHMET BAYKARA<sup>2</sup>, HAYRİYE SARICAĞLU<sup>1</sup> and SÜKRAN TUNALI<sup>1</sup>*Departments of <sup>1</sup>Dermatology and <sup>2</sup>Ophthalmology, Uludag University Medical Faculty, Görükle, Bursa, Turkey*

**Hemangiomas are the most common tumours of infancy. When limited to the skin, multiple lesions have a benign course and excellent prognosis but in cases of visceral involvement, the morbidity and mortality rates are high. We report a rare case of a female infant with benign neonatal hemangiomatosis who had dramatic conjunctival involvement. The spectrum of neonatal hemangiomatosis is reviewed, highlighting the importance of differentiation of the two extremes of this disorder. Key words: neonatal hemangiomatosis; conjunctival involvement.**

(Accepted January 15, 2002.)

Acta Derm Venereol 2002; 82: 124–127.

Emel Bülbül Baskan, Uludag University Medical Faculty, Dermatology Department, Görükle 16059, Bursa, Turkey. E-mail: baskan@superonline.com

Neonatal hemangiomatosis is characterized by the presence of multiple congenital hemangiomas. This disorder is commonly a benign condition when the tumours are associated with limited or asymptomatic visceral involvement and has been called benign neonatal hemangiomatosis (BNH) (1). However, multiple cutaneous hemangiomas may occur with coexistent hemangiomas of at least 3 separate organ systems, and this rare and life-threatening condition is known as diffuse neonatal hemangiomatosis (DNH). Spontaneous regression occurs in patients with BNH usually within the first 2 years of life. Depending on the specific organ involvement, visceral hemangiomas of DNH may have a fatal outcome if not recognized and treated (2).

This report describes a female infant with BNH whose lesions are limited to the skin and mucosa and emphasizes the careful monitoring of infants presenting with multiple cutaneous hemangiomatosis.

## CASE REPORT

A 40-day-old girl was referred to our clinic for the evaluation of pink papules on her face, trunk and limbs (Fig. 1). She was delivered vaginally at term by a 21-year-old mother and had a birthweight of 3,300 g. There was no family history of hemangiomas, congenital

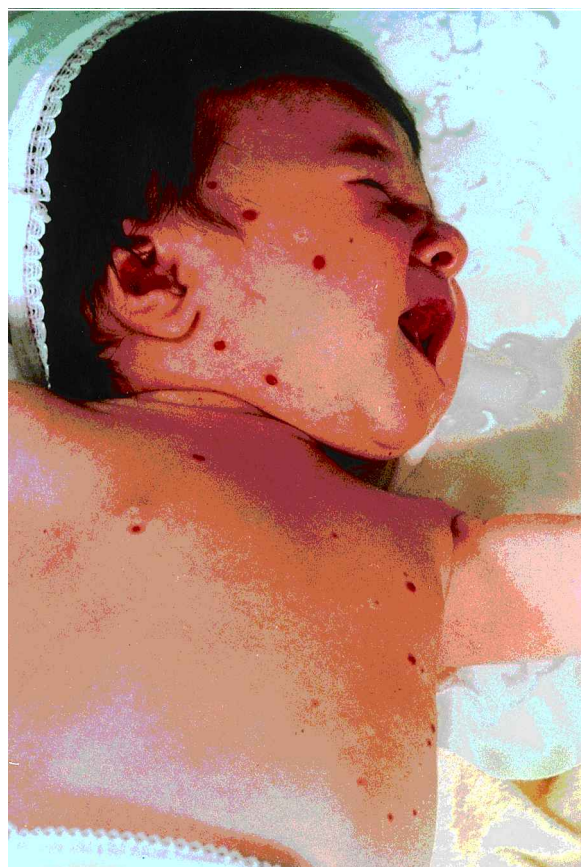

Fig. 1. Multiple cutaneous hemangiomas on the face, trunk and limbs.

malformations or consanguinity. Cutaneous hemangiomas were first noted at birth on her face and neck as pink macules that enlarged to become domed red papules of firm consistency with some smooth and some lobulated surfaces, increasing in number over the first few weeks. The pink papules, well-demarcated from surrounding tissue, ranged in size from 1 to 10 mm and some of them had a perilesional pale halo. A 2 × 2 mm sized pink papule was also observed on the midline of the upper lip. Ophthalmic examination disclosed a 0.5 × 0.5 mm hemangioma on the nasal side of the right upper eyelid, localized 5 mm from the inner canthus. A 6 × 3 mm hemangioma was also noted in the upper nasal conjunctiva of the left eye (Fig. 2). Bilateral anterior segment structures, lens and fundal examination were

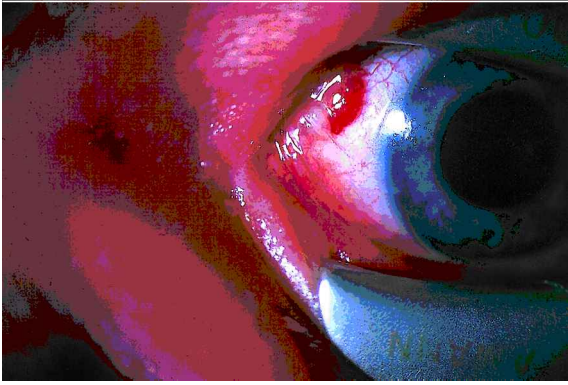


Fig. 2. A 6 × 3 mm hemangioma in the upper nasal conjunctiva of the left eye.

within normal limits. These hemangiomas remained stable on the subsequent examinations, repeated every month, and began to regress spontaneously after 5 months and completely disappeared at 8 months of age.

On physical examination, we found no evidence of visceral involvement or any signs of congestive heart failure. The results of initial laboratory studies including complete blood count, serum electrolytes and transaminases were normal and a stool guaiac test was negative. Initial chest radiography and screening with abdominal ultrasonography with a Doppler study repeated every 3 months ruled out respiratory system and hepatic involvement. An echocardiogram showed only a small atrial septal defect, but no arteriovenous malformation was detected.

The infant is now 8 months of age, with normal growth and development. Most of her cutaneous and mucosal hemangiomas involuted spontaneously, with excellent cosmesis. She is still seen at 3-month intervals for an outpatient follow-up visit.

## DISCUSSION

Hemangiomas are benign vascular neoplasms, present in nearly 1–2% of newborns and 10–12% of infants by one year of age (1). Female infants are 4 times more likely to be affected (2). The hemangiomas may occur anywhere on the skin but the head and neck are the most commonly affected sites, trunk and limb are next. Often, hemangiomas may involve the mucous membranes of the oral and genital regions. In approximately 10–20% of infants with hemangiomas, the lesions are multiple (2, 3). Multiple congenital hemangiomas that affect the skin and viscera have been designated as neonatal hemangiomatosis (3).

BNH was first defined by Stern et al. (1) as multiple cutaneous hemangiomas with limited or asymptomatic visceral involvement following a benign course. As in our case, these infants experience rapid involution of their skin lesions, usually within the first 2 years of life, and have an excellent prognosis. Significant

systemic findings such as thrombocytopenia, anemia and obstructive jaundice, which regressed early as did cutaneous lesions, generally by 6 to 9 months of age, were also reported in cases of BNH (3). However, the occurrence of a prolonged and complicated proliferative phase of cutaneous hemangiomas through 18–20 months of age has been documented in two more recent case reports (4, 5). The clinical characteristics of 14 cases identified as BNH are summarized in Table I (1, 3–11).

Hemangiomas of the iris in the cases of BNH and DNH with eyelid, conjunctival, ciliar and iris hemangiomas were previously reported (12). The most common visual complications of the 51 infants and children with infantile hemangioma of the eyelid were amblyopia and strabismus, so in the cases of eyelid occlusion, careful follow-up is necessary and therapy should be started as early as possible (13). In our case, the hemangioma of the eyelid and conjunctiva did not result in any complication during the follow-up, and the hemangiomas regressed spontaneously.

Esterly et al. (14) described neonatal hemangiomatosis as a continuum, with DNH and BNH representing opposite extremes of the spectrum. DNH is a severe and life-threatening disorder affecting 3 or more organ systems (15). Clinically, the cutaneous features are indistinguishable from those seen in BNH. The liver is the most commonly involved internal organ, followed by lung, brain and intestine (1). Visceral hemangiomas have also been reported in the lymph nodes, spleen, kidney, iris, retina, salivary glands, heart, thymus, bladder, gallbladder, pancreas and adrenal gland (1, 2). Hepatic hemangiomas eventually involute but significant involvement may manifest itself as a triad of hepatomegaly, congestive heart failure and anemia which generally develops between 1 and 16 weeks of age (1, 15). Mortality reported to be as high as 81% without treatment and reduced to 29% with treatment is most commonly due to congestive heart failure. Other complications depend on the specific organ involvement and include gastrointestinal hemorrhage, obstructive jaundice and seizures (15).

It is important to differentiate the benign and disseminated variants of neonatal hemangiomatosis with the most appropriate studies because early therapy and aggressive intervention are crucial in the cases of DNH. As benign and diffuse neonatal hemangiomatosis likely exist along a continuum, infants younger than 3 months with numerous, small cutaneous hemangiomas should be carefully monitored. In this group of patients, in addition to a work-up directed by history, physical examination, general chemistry and blood counts, screening abdominal ultrasonography with Doppler studies may be considered to rule out hepatic involvement (1). We did not perform a magnetic resonance examination of the brain in this asymptomatic case. Whether additional and more expensive diagnostic tests

Table I. Clinical features in patients with benign neonatal hemangiomatosis\*

Reference	Sex	Age at onset	Other findings	Treatment of hemangiomas	Course
Lunsford (3)	F	6 days	None	1. Radium to 2 large lesions 2. CO <sub>2</sub> snow 3. None	1. Decreased to 1/3 original size; 2. Vesicles healed 3. Resolved
Fischler (6)	M	Birth	Hematemesis, anemia, thrombocytopenia	None	Began to resolve at 3 months of age
Burke et al. (7)	M	Birth	CNS lesion?	None	Began to involute at 1 year of age
Fryns et al. (8)	F	3 days	Hemangiomas in buccal mucosa, iris, hepatomegaly	None	Only 10% of lesions remaining at 18 months of age
Sardemann et al. (9)	M	Birth	Tumour on placenta, jaundice, hemangiomas in buccal, anal mucosa, iris, hepatosplenomegaly	None	Hemangiomas began to diminish at 5 weeks with simultaneous decrease in serum bilirubin
	M	Birth	Tumour on placenta, jaundice, hepatosplenomegaly	None	Hemangiomas disappeared by 5 months of age
Stern et al. (1)	F	Birth	Congestive heart failure, hepatomegaly	Digitalization oxygen, diuresis	Spontaneous regression with complete resolution of all lesions at 10 months
Ronan et al. (10)	F	After birth	None	Oral prednisone	Lesions began to involute after 2 months of therapy
Held et al. (4)	F	10 days	Small bowel atresia	None	Lesions continued to appear and grow at 18 months
Rothe et al. (5)	M	Birth	Subcutaneous perinasal hemangioma	Surgery, oral prednisone	Lesions continued to appear and grow at 20 months
Dyall-Smith et al. (11)	M	20 days	Hypothyroidism, recurrent bronchiolitis	None	Lesions disappeared by 28 months of age
	F	6 months	Arnold-Chiari malformation, large meningocele in the lower cervical and upper thoracic region	None	No follow-up
	F	Birth	Patent ductus arteriosus, atrial septal defect	None	Lesions involuted by 1 year of age
Baskan E. et al. (present study)	F	Birth	Hemangiomas on the lip, eyelid and iris, small atrial septal defect,	None	Lesions began to involute by 8 months of age

\*Modified and updated from Rothe et al. (5).

such as magnetic resonance imaging of brain should be included in the routine evaluation or follow-up of these infants has not been well established in the literature.

The approach to the management of hemangiomas should be individualized based on the size of the lesions, location, presence of complications, the age of the patient and the rate of growth or involution of the lesions. Since most of the lesions regress spontaneously during the first years of life, we also preferred expectant management in this case for best cosmetic results. Active treatment is necessary when hemangiomas interfere with important structures and their functions or the complications of extensive visceral involvement are present. Systemic and intra-lesional steroids, embolization, surgery, cryotherapy, cytotoxic agents, laser and interferon therapy are the available therapeutic options, but the first choice in treating serious hemangiomas is by systemic steroids (1, 2). Since there are reports about the appearance of new lesions and growth of established lesions even after 18–20 months of age (4, 5), we want

to point out that whatever the therapeutic approach is, routine monitoring is necessary, especially during the first years of life.

## REFERENCES

1. Stern JK, Wolf JE, Jarratt M. Benign neonatal hemangiomatosis. *J Am Acad Dermatol* 1981; 4: 442–445.
2. Requena L, Sanguenza OP. Cutaneous vascular proliferations. Part II. Hyperplasias and benign neoplasms. *J Am Acad Dermatol* 1997; 37: 887–922.
3. Lunsford CJ. Multiple disseminated angiomas: report of a case. *Arch Dermatol Syph* 1932; 25: 344–347.
4. Held JL, Haber RS, Silvers DN, Grossman ME. Benign neonatal hemangiomatosis: review and description of a patient with unusually persistent lesions. *Pediatr Dermatol* 1990; 7: 63–66.
5. Rothe MJ, Rowse D, Grant-Kels JM. Benign neonatal hemangiomatosis with aggressive growth of cutaneous lesions. *Pediatr Dermatol* 1991; 8: 140–146.
6. Fischler E. Subcutane nodulare hemangiomatosis in

- kombination mit thrombocytopenie. Bericht über einen fall. *Helv Pediatr Acta* 1960; 1: 88–93.
7. Burke EC, Winkelmann RK, Strickland MK. Disseminated hemangiomas: the newborn with central nervous system involvement. *Am J Dis Child* 1964; 108: 418–424.
  8. Fryns JP, Eggermont E, Eeckels R. Multiple diffuse hemangiomas. Case report and review of the literature. *Z Kinderheilk* 1974; 117: 115–119.
  9. Sardemann H, Tygstrup I. Prolonged obstructive jaundice and hemangiomas. Report of 2 cases. *Arch Dis Child* 1974; 49: 665–667.
  10. Ronan SG, Solomon LM. Benign neonatal hemangiomas in identical twins. *Pediatr Dermatol* 1984; 1: 318–321.
  11. Dyll-Smith D, Cowen P. Benign neonatal hemangiomas. *Int J Dermatol* 1992; 31: 336–338.
  12. Chang CW, Rao NA, Stout JT. Histopathology of the eye in diffuse neonatal hemangiomas. *Am J Ophthalmol* 1998; 125: 868–870.
  13. Stigmar G, Crawford JS, Ward CM, Thomson HG. Ophthalmic sequelae of infantile hemangiomas of the eyelids and orbit. *Am J Ophthalmol* 1978; 85: 806–813.
  14. Esterly NB, Margileth AM, Kahn G, et al. The management of disseminated eruptive hemangiomas in infants: special symposium. *Pediatr Dermatol* 1984; 1: 312–317.
  15. Lopriore E, Markhorst DG. Diffuse neonatal hemangiomas: new views on diagnostic criteria and prognosis. *Acta Pediatr* 1999; 88: 93–97.