

- ant of paraneoplastic autoimmune multiorgan syndrome. *Arch Dermatol* 2001; 137: 193–206.
7. Rivollier C, Vaillant L, Machet MC, Martin L, Jan V, Huttenberger B, et al. Pemphigus paraneoplastique. Une forme pustuleuse au cours d'une leucémie lymphoïde chronique. *Ann Dermatol Venereol* 2001; 128: 644–648.
 8. Kimyai-Asadi A, Jih MH. Paraneoplastic pemphigus. *Int J Dermatol* 2001; 40: 367–372.
 9. Ostezan LB, Fabrè VC, Caughman SW, Swerlick RA, Korman NJ, Callen JP. Paraneoplastic pemphigus in the absence of a known neoplasm. *J Am Acad Dermatol* 1995; 33: 312–315.

Mixed Response to Thalidomide Therapy in Adults: Two Cases of Multisystem Langerhans' Cell Histiocytosis

Gerhard Kolde, Peter Schulze and Wolfram Sterry

Department of Dermatology, Charité, Humboldt-University of Berlin, Schumannstr. 20/21, 10117 Berlin, Germany.

E-mail: gerhard.kolde@charite.de

Accepted April 23, 2002.

Sir,
Langerhans' cell histiocytosis (LCH) (formerly histiocytosis X) is a clonal disorder of proliferating histiocytic cells expressing the phenotypic markers of the epidermal antigen-presenting Langerhans' cells (1, 2). The clinical spectrum and prognosis are variable ranging from benign single-organ disease affecting single or multiple sites, to multisystem disease with involvement of two or more organs, including chronic multifocal Hand-Schüller-Christian disease and acute leukaemia-like Abt-Letterer-Siwe disease. Owing to the unpredictable and often progressive course, multisystem LCH of infants warrants therapy with prednisolone and/or cytotoxic drugs, used either alone or in combination (3). By contrast, the management of adult-onset multisystem LCH remains controversial, as the disease has a more benign character than that in infants.

Successful treatment of LCH with thalidomide was first observed in a 32-year-old woman with localized genital lesions (4). Since then, the efficacy of thalidomide has been demonstrated in several case reports (5–8). However, most of the patients treated suffered from purely cutaneous LCH. We report here on the effects of thalidomide monotherapy in two adult patients with pronounced mucocutaneous and mild visceral manifestations of the disease.

CASE REPORTS

The two patients, a 23-year-old man (patient 1) and a 61-year-old woman (patient 2), suffered from adult-onset, chronic multisystem LCH for several years. Patient 1 presented with widespread mucocutaneous lesions, with infiltration of the scalp, erythematous gum swelling, and inguinal, perianal and anal infiltration and ulceration. Patient 2 presented with a multifocal maculopapular eruption on the trunk. The visceral involvement was restricted to either a focal bone defect of the jaw (patient 1) or multifocal infiltration of the mediastinal lymph nodes (patient 2). Involvement of other organ

regions and organs was ruled out after a complete physical examination, laboratory evaluation including liver function tests and phenotyping of peripheral blood mononuclear cells, abdominal and lymph node sonography, skeletal radiograph survey and computed tomography. The diagnosis of LCH was established by histological, immunohistological and electron microscopy examination of the cutaneous and visceral lesions, which showed aggregates of large histiocyte-like cells with CD1a expression and cytoplasmic Birbeck granules.

Patient 2 had previously been treated with systemic corticosteroids, which resulted in partial regression of the maculopapular skin eruption, but there was an immediate relapse after completion of the course of corticosteroid treatment.

After giving detailed information and obtaining written consent, both patients were started on thalidomide monotherapy at a dosage of 100 mg/day, which resulted in significant improvement of the mucocutaneous lesions. The maculopapular skin eruption and erythematous gum swelling resolved within one month, and the inguinal, perianal and anal infiltrations and ulcerations healed with scarring after 3 months (Fig. 1). The eroded and crusted

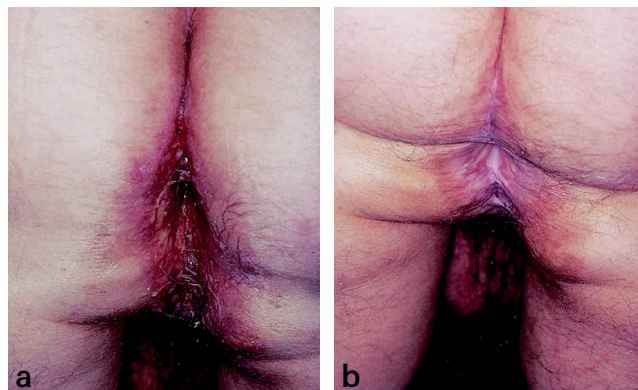


Fig. 1. Perianal and anal infiltration and ulceration (a) before and (b) after 3 months of thalidomide therapy showing healing of the lesions, with slight scarring.

scalp infiltration was markedly reduced, leaving only slight erythema. By contrast, neither the jawbone lesion with ulceration of overlying mucosa, nor the mediastinal lymph node involvement showed regression, even after increased daily doses (up to 500 mg). Owing to this failure, the thalidomide therapy was terminated after 3 and 16 months, respectively, and the patients were referred for cytotoxic treatment regimens.

Thalidomide was well tolerated by both patients. The sedative effects of the drug were successfully minimized by giving the thalidomide at bedtime. There were no adverse effects, and neurologic control examinations including electrophysiological measurements revealed no evidence of neuropathy.

DISCUSSION

Although multisystem LCH in the adult is rare, there is substantial evidence to suggest that the disease has a more benign character in adults than in infants (9, 10). The disease is mostly confined to a few lesions in only two or three organs, in particular bone, lung, skin and/or mucous membranes, and the lymph nodes, and does not cause severe functional or structural defects of the affected organs. Most importantly, adult-onset multisystem LCH usually takes a chronic or slightly progressive rather than aggressive course.

Our two adult patients suffered from long-standing, chronic multisystem LCH with widespread mucocutaneous lesions and mild visceral involvement restricted to either the bone of the jaw, or mediastinal lymph nodes. These clinical features and the efficacy of thalidomide in cutaneous LCH encouraged us to start low-dose monotherapy, which was well tolerated and did not lead to peripheral neuropathy, the most serious adverse effect in addition to the teratogenicity (11). The treatment resulted in healing or at least significant improvement of the mucocutaneous lesions, including complete regression of the marked inguinal, perianal and anal lesions in one of the patients. By contrast, neither the bone nor the lymph node involvement responded to the thalidomide therapy.

To the best of our knowledge, there are only two reports on the use of thalidomide in multisystem LCH. The two patients reported by Thomas et al. (6), showed histologically proven healing of the mucocutaneous lesions, but no regression of the bone, pulmonary and hypothalamic involvement. In the case reported by Bensaid et al. (5), the treatment failed to improve the cutaneous lesions, but was effective in resolving the parotid gland involvement.

The mechanism of action of thalidomide in LCH is currently not known. It is, however, remarkable that thalidomide exerts many of its antiinflammatory and antineoplastic properties by inhibiting the production of TNF α and IL-6 (12). These cytokines show an abundant expression in LCH lesions and are thought to play a crucial role in the recruitment, irregular maturation and

viability of the tumour cells (13, 14). It could therefore be speculated that the beneficial effect of thalidomide is mediated via normalization of the pathological cytokine environment in the lesions. Such a mechanism of treatment was also proposed in a very recent observation showing that the neutralization of TNF α by etanercept resulted in a marked improvement of multisystem LCH in a 5-month-old infant (15).

Taken together, thalidomide monotherapy represents an effective, safe and well-tolerated treatment option not only for pure cutaneous LCH, but also for the skin and mucous membrane lesions in adult-onset chronic multisystem disease. The extracutaneous manifestations of the disease seem to respond less effectively, but this impression merits being proven in more patients with chronic visceral involvement.

REFERENCES

1. Chu AC. Histiocytoses. In: Champion RH, Burton JL, Burns DA, Breathnach SM, eds. Textbook of dermatology. 6th ed. Vol. 3. Oxford: Blackwell Scientific Publications, 1998: 2311–2336.
2. Caputo R. Langerhans' cell histiocytosis. In: Freedberg IM, Eisen AM, Wolff K, Austen KF, Goldsmith LA, Katz SI, et al., eds. Fitzpatrick's dermatology in general medicine. 5th ed. Vol. II. New York: McGraw-Hill, 1999: 1882–1892.
3. Gardner H, Grois N, Arico M, Broadbent V, Ceci A, Jakobson A, et al. A randomized trial of treatment for multisystem Langerhans' cell histiocytosis. *J Pediatr* 2001; 138: 728–734.
4. Gnassia AM, Gnassia RT, Bonvalet D, Puissant A, Goudal H. Histiocytose X avec "granulome eosinophile vulvaire". Effet spectaculaire de la thalidomide. *Ann Dermatol Venereol* 1987; 114: 1387–1389.
5. Bensaid P, Mchet L, Vaillant L, Mchet MC, Scotto B, Lorette G. Histiocytose langerhansienne de l'adulte: localisation parotidienne régressive après traitement par thalidomide. *Ann Dermatol Venereol* 1992; 119: 281–283.
6. Thomas L, Ducros B, Secchi T, Balme B, Moulin G. Successful treatment of adult's Langerhans' cell histiocytosis with thalidomide. Report of two cases and literature review. *Arch Dermatol* 1993; 129: 1261–1264.
7. Gerlach B, Stein A, Fischer R, Wozel G, Dittert DD, Richter G. Langerhanszell-Histiozytose im Alter. *Hautarzt* 1998; 49: 23–30.
8. Lair G, Marie I, Cailleux N, Blot E, Boullie MC, Courville P, et al. Histiocytose langerhansienne de l'adulte: localisations cutaneomuqueuses régressives après traitement par thalidomide. *Rev Med Interne* 1998; 19: 196–198.
9. Baumgartner I, von Hochstetter A, Baumert B, Luetolf U, Follath F. Langerhans' cell histiocytosis in adults. *Med Pediatr Oncol* 1997; 28: 9–14.
10. Giona F, Caruso R, Testi AM, Moleti ML, Malagnino F, Martelli M, et al. Langerhans' cell histiocytosis in adults – a clinical and therapeutic analysis of 11 patients from a single institution. *Cancer* 1997; 80: 1786–1791.
11. Allen BR. Thalidomide. *Br J Dermatol* 2001; 144: 227–228.
12. Meierhofer C, Duzendorfer S, Wiedermann CJ. Theoretical basis for the activity of thalidomide. *BioDrugs* 2001; 15: 681–703.
13. Egeler RM, Favara BE, van Meurs M, Laman JD, Claassen E. Differential in situ cytokine profiles of

Langerhans-like cells and T cells in Langerhans' cell histiocytosis: abundant expression of cytokines relevant to disease and treatment. *Blood* 1999; 94: 4195–4201.

14. Tazi A, Moreau J, Bergeron A, Dominique S, Hance AJ, Soler P. Evidence that Langerhans' cells in adult pulmonary Langerhans' cell histiocytosis are mature dendritic

cells: importance of the cytokine microenvironment. *J Immunol* 1999; 163: 3511–3515.

15. Henter JI, Karlén J, Calming U, Bernstrand C, Andersson U, Fadeel B. Successful treatment of Langerhans' cell histiocytosis with etanercept. *N Engl J Med* 2001; 345: 1577–1578.

Bilateral Chalazia of the Lower Eyelids Associated with Pulmonary Tuberculosis

Mikako Aoki and Seiji Kawana

Department of Dermatology, Nippon Medical School Main Hospital, 1-1-5, Sendagi, Bunkyo-ku, Tokyo, 113-8602 Japan.

E-mail: mikan@nms.ac.jp

Accepted April 24, 2002.

Sir,

A chalazion is a chronic granulomatous inflammation that develops around the sebaceous glands in the eyelids (1). This disease of the eyelid is commonly encountered in the field of ophthalmology. Because dermatologists are generally not familiar with this disease, they may have some difficulties in making an accurate diagnosis. Here, we report on a case of bilateral symmetrical external chalazia associated with active pulmonary tuberculosis, the diagnosis of which was initially quite difficult.

CASE REPORT

A 61-year-old Japanese male with alcoholic liver cirrhosis presented a 3-week history of persistent swelling below each eye. Physical examination revealed bilateral, symmetrical, elastic, soft, non-tender, reddish-brown nodules immediately beneath the border of the lower epibrephalons (Fig. 1). The ocular and palpebral conjunctivae were normal, but a dimple appeared on the palpebral conjunctiva when the lower eyelid was pulled down. A skin biopsy of the left nodule revealed edema and a dense cellular infiltrate throughout the dermis. The essential feature was the formation of a confluent series of focal granulomas, consisting of epithelioid cells and multinucleated giant cells, with small neutrophilic microabscess (Fig. 2). Gram, Ziehl-Neelsen, PAS and Grocott stainings all yielded negative results, and swabs and tissue fragments obtained from the lesions failed to grow any bacteria and fungi. Although both nodules were completely surgically excised, similar lesions recurred twice at the same site and ruptured spontaneously. In the systemic check, the tuberculin skin test yielded a positive result, and culture and PCR of the patient's sputum were both positive for tuberculous bacilli. Anti-tuberculous combination therapy with isoniazid, rifampicin and ethambutol was started. After this therapy, the skin lesions of the lower eyelids disappeared, and in the subsequent year of follow-up there was no evidence of a recurrence.

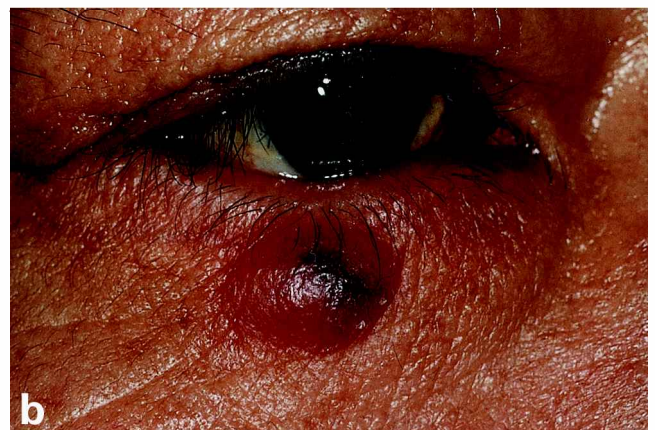
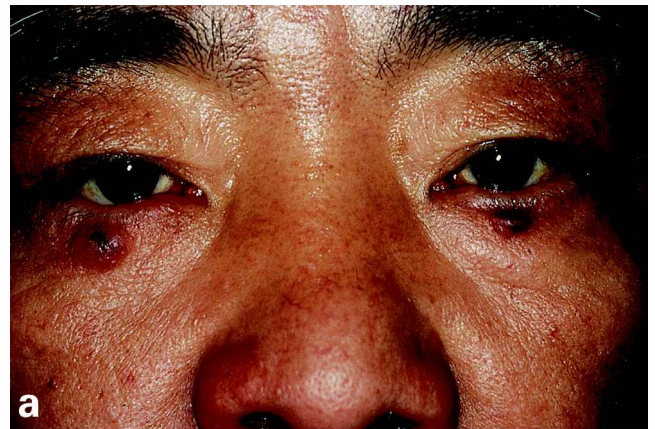

Fig. 1. Bilateral, elastic soft, reddish-brown nodules of the lower eyelids (a) and a close up of the right eye (b).

DISCUSSION

Chalazion is a granulomatous response to liberated fat from the sebaceous glands of the eyelids. The lesion usually ruptures through the conjunctiva (internal chalazia). In rare instances, focal inflammation around the involved gland causes pointing of the lesion through the skin anteriorly, where it eventually spontaneously drains (external chalazia) (2). Although lipid globules discharged from the sebaceous glands were not evident in the biopsy specimen, the clinical and histopathological