

CLINICAL REPORT

Treatment of Vitiligo Vulgaris with Narrow Band UVB (311 nm) for One Year and the Effect of Addition of Folic Acid and Vitamin B12

M. TJIOE¹, M. J. P. GERRITSEN¹, L. JUHLIN² and P. C. M. VAN DE KERKHOF¹*Department of Dermatology, ¹University Medical Center Nijmegen, The Netherlands and ²University Hospital Uppsala, Sweden*

Narrow band UVB is succeeding psoralen and UVA irradiation as the main treatment of vitiligo vulgaris in several European countries. Vitamin B12 and folic acid deficiency in some vitiligo patients has prompted researchers to investigate the efficacy of these vitamins in the treatment of vitiligo. In the present controlled study we investigated the value of narrow band UVB phototherapy in the treatment of vitiligo and the possible additive effect of vitamin B12 and folic acid. Twenty-seven patients with long-term stable vitiligo were included and randomized in a “UVB only” (UVB) or “UVB combined with vitamin B12 and folic acid” (UVB+) group. Patients were irradiated thrice weekly for one year, whilst repigmentation was carefully monitored. In 92% (25/27) of the patients up to 100% repigmentation was seen. Repigmentation was notable in lesions on the face, neck and throat, lower arm, chest, back and lower legs, whilst repigmentation on the hands, wrists, feet and ankles proved to be minimal. Maximum repigmentation rates did not differ significantly between the UVB group and the UVB+ group. Our study reconfirms that narrow band UVB phototherapy is an effective treatment for vitiligo and shows that co-treatment with vitamin B12 and folic acid does not improve the outcome of treatment of vitiligo with narrow band UVB phototherapy. *Key words: repigmentation; therapy; melanin; phototherapy.*

(Accepted May 14, 2002.)

Acta Derm Venereol 2002; 82: 369–372.

Milan Tjioe, Department of Dermatology, University Medical Center Nijmegen, P.O.Box 9101, NL-6500 HB Nijmegen, The Netherlands. E-mail: M.Tjioe@derma.azn.nl

Vitiligo has been known for centuries and is a disease characterized by the appearance of white patches, due to a loss of melanocytes (1–3). Although several treatments have been suggested in past years, it was not until the 1900s that the first effective treatment, photochemotherapy, was found (4–6). Psoralen and UVA irradiation (PUVA) treatment has been the only successful treatment for decades and in some countries PUVA is still the main treatment for generalized vitiligo. Recently, advances in phototherapy have provided new treatment

possibilities. Narrow band UVB in particular has been a major breakthrough and is superseding PUVA as the main treatment in several countries (7, 8). So far, however, controlled studies on the efficacy of narrow band UVB are not available. It should be taken into consideration that only UVB therapy is effective after prolonged treatment and that long-term, placebo-controlled studies for approaches where ample evidence is available are difficult to justify. In order to further substantiate the evidence for the efficacy of long-term narrow band UVB therapy, it is important to study patients with long-standing stable vitiligo.

Research on the aetiology and pathomechanisms of vitiligo has provided some insight into the biochemical pathways involved. This has resulted in the development of phototherapy treatments combined with several biochemical compounds such as pseudocatalase, calcium chloride and phenylalanine (9–14).

It has been suggested that vitamin B12 and folic acid may play a role in the melanin synthesis pathway, as the pteridine part of folic acid and N-N-methylene tetrahydrofolate as well as the vitamin B12-dependent formation of methionine could interfere with processes leading to depigmentation and pigmentary dilution (15–17). Several reports suggest that a deficiency of vitamin B12 and folic acid could be a common characteristic of vitiligo, while others contradict this supposition (18–20). Therefore it is tempting to hypothesize that vitamin B12 and folic acid may contribute to the efficacy of phototherapy in vitiligo.

The aim of the present study is to confirm the therapeutic value of narrow band UVB in the treatment of patients with stable vitiligo and, secondly, to evaluate the additional effect of vitamin B12 and folic acid on the treatment of vitiligo vulgaris with narrow band UVB phototherapy using a non-blinded approach comparing UVB and vitamin B12 and folic acid with narrow band UVB.

MATERIAL AND METHODS

Patients

Twenty-seven patients (male and female) aged 18 and above, with stable vitiligo vulgaris (at least one year no changes) and Fitzpatrick's skin type II–IV from our outpatient clinic were

included in the study, after written informed consent had been obtained. Patients using any medical treatment for their vitiligo at the time of the study were excluded. Other exclusion criteria were patients with a history of skin cancer or dysplastic naevus syndrome, photosensitivity or using photosensitizing medicines, psychiatric or epileptic disorders, known renal failure and known allergies to substances in the trial medication. The demographic data of the patients are shown in Table I.

Treatments

The patients were randomized in 2 narrow band UVB treatment groups. The first group received only narrow band UVB phototherapy, the second group received twice daily vitamin B12 (cobalamin) 1,000 µg sustained release tablets (Orthica B.V., Weesp, The Netherlands) and folic acid 5 mg tablets (Dumex, The Netherlands). These doses were chosen in concordance with a previous study by Juhlin & Olsson (21). Both groups were irradiated with narrow band (311 nm) UVB, as generated by Philips TL-01 lamps in a Waldmann 7001 cabin (Waldmann Medical Technology, The Netherlands). Irradiation was given 3 times a week for 12 months and started with 0.10 J/cm² exposure, which increased by 0–30% every next visit on an individual basis.

All the vitiliginous areas were carefully monitored monthly during the study period, including before and after photographs. The percentage of repigmentation was visually estimated in all areas. As a primary efficacy criterion we selected the areas showing the most active repigmentation. This was designated as “maximum repigmentation”.

Treatment was continued for one year after start of phototherapy or discontinued earlier if full repigmentation was reached before that time.

Treatment outcome was visually scored as the percentage of repigmentation of depigmented lesions.

Statistical analysis was performed with a one-way ANOVA test, on SPSS 7.5 for Windows.

RESULTS

The mean cumulative dose of narrow band UVB given to each patient was 126.7 ± 88.6 J/cm² (11.6–401.8 J/cm²), both groups taken together (Table I). Twenty-five of the 27 patients showed prominent repigmentation on most lesions of the body. In each group, one patient showed less than 5% repigmentation after 4 months of phototherapy and these patients were advised to discontinue phototherapy treatment.

As shown in Table II, ≥ 90% repigmentation (median values) was reached on the face, neck and throat, lower

Table II. Percentage of repigmentation in different body areas of all the patients (n = 27)

Area	No. of patients	Repigmentation (%) Mean ± SD	Repigmentation Median (range)
Face	19	71.8 ± 35.5	90 (5–100)
Neck/Throat	7	68.6 ± 40.7	90 (5–100)
Upper Arm	4	65.0 ± 31.0	65 (30–100)
Elbow	12	50.4 ± 29.8	45 (10–100)
Lower Arm	7	80.0 ± 24.5	90 (30–100)
Hand/Wrist	18	35.6 ± 31.5	22.5 (10–100)
Axilla	17	37.4 ± 31.9	40 (0–100)
Chest	9	71.1 ± 35.9	90 (20–100)
Abdomen	3	80.0 ± 10.0	80 (70–90)
Back	10	84.0 ± 27.5	92.5 (10–100)
Groin	14	70.4 ± 25.5	77.5 (20–100)
Upper Leg	6	55.0 ± 40.9	70 (0–100)
Knee	5	62.0 ± 41.5	80 (0–100)
Lower Leg	12	85.0 ± 16.1	90 (60–100)
Foot/Ankle	12	12.1 ± 10.8	10 (0–40)

arm, chest, back and lower legs, while less than 25% repigmentation (median values) was seen on the hands, wrists, feet and ankles.

The maximum repigmentation in vitiliginous lesions for both groups is shown in Fig. 1. No significant difference in repigmentation was reached at any of the monthly measurement points between the 2 groups (p ≥ 0.175). No additional effect of vitamin B12 and folic acid on repigmentation was seen on less responsive areas such as either the hands or feet (p ≥ 0.23).

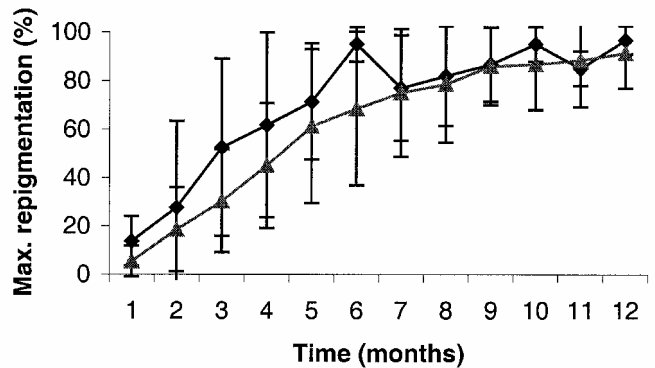


Fig. 1. Course of maximum repigmentation during one year narrow band UVB phototherapy with (▲) or without (●) medication.

Table I. Patient characteristics

Characteristics	Control group (UVB)	Vitamin group (UVB+)
No. of patients	13	14
Skin type II	5	3
Skin type III	7	10
Skin type IV	1	1
Age mean ± SD (range)	41.6 ± 8.7 (20–51)	46.8 ± 10.2 (29–68)
Sex, M/F	6/7	5/9
Duration of disease mean ± SD (range)	10.8 ± 9.9 (1–30)	18.3 ± 13.1 (1–47)
Percentage of body surface affected mean ± SD (range)	8.4 ± 5.6 (2–18)	10 ± 7.5 (3–26)
Mean cumulative dose narrow band UVB ± SD (range)	128.25 ± 109.57 (18.8–401.73)	125.11 ± 66.57 (11.09–214.24)

An example of an average response in a patient treated with UVB phototherapy alone is presented in Fig. 2. In all patients transient erythema was observed occasionally, usually experienced as localized prickling of the skin within 24 h of irradiation. However, these responses were mild and never induced aggravation of the lesions (Koebner phenomenon).

DISCUSSION

So far, no standardized scoring method for evaluating the effect of repigmentation therapies is available. A Psoriasis Area Severity Index (PASI)-type score, such as is used for psoriasis, would be a great step forward to evaluate and compare the effect of repigmentation between different therapies. Some studies use a rather inaccurate graded scoring method (less than 30%, 30–70% and more than 70% repigmentation, or total, partial and no repigmentation) (7, 22–25). Our study shows that only slight repigmentation or no repigmentation at all was seen on the dorsa of the hands, feet and the inner wrist, while other areas such as the face, chest, extensor surfaces of the lower arm and leg, back and neck/throat often repigmented readily and completely (Fig. 2 and Table II). Previously, resistance of the hands, feet and the inner wrist has been suggested for PUVA phototherapy, although this study did not provide a systematic quantitative analysis (25). On the other hand, some studies claim to achieve full repigmentation, again not specifying the responses per body region (10).

In view of the substantial intra-individual variability, we have avoided the pitfall of a general score and instead opted for the approach of scoring repigmentation visually per lesion and retrospectively selecting the maximum repigmented area in each patient as the primary efficacy criterion. As an additional efficacy criterion, we used the repigmentation in all body areas. A modified PASI score, with special attention to less responsive areas, possibly assisted by computerized measurement of the total reduction in vitiliginous areas could have provided more insight into the efficacy of vitiligo treatments.

Although no large studies and no controlled studies have been done, narrow band UVB has been proven in some studies to be effective in inducing repigmentation in patients with vitiligo (8, 23, 26). Our study shows that narrow band UVB treatment results in an up to 100% repigmentation of depigmented lesions in 92% (25/27) of patients with long-term stable vitiligo vulgaris. During this treatment period no relapse was seen and apart from some prickling sensations, usually on

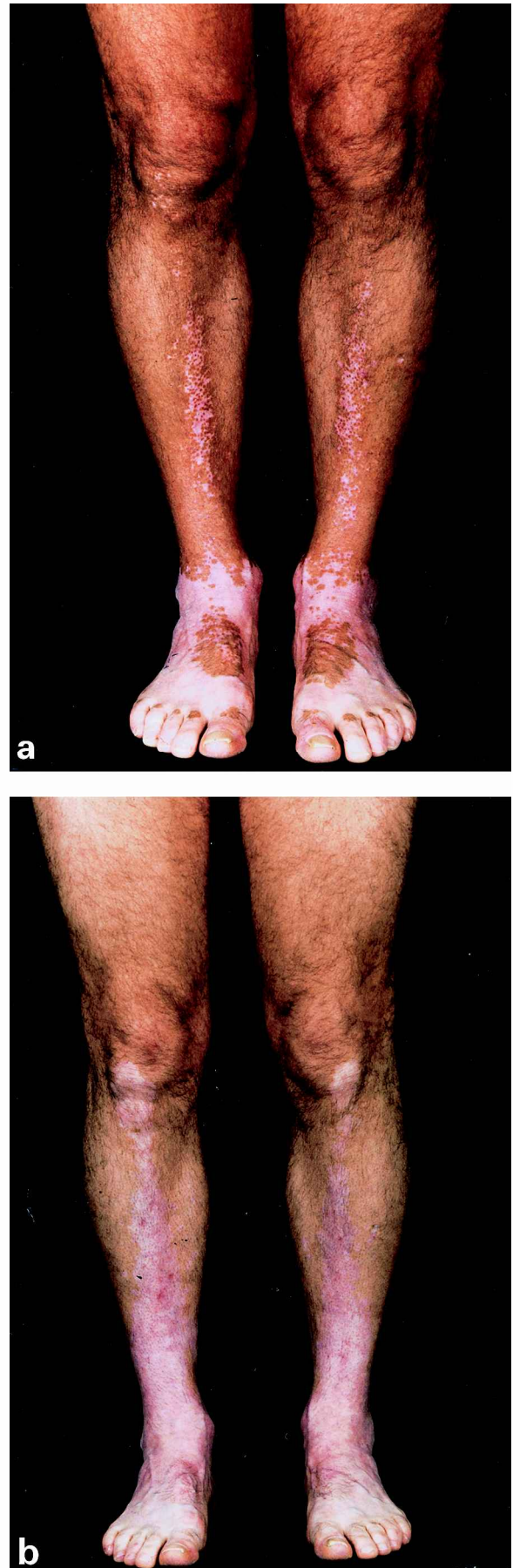

Fig. 2. Before (a) and after (b) photographs of a vitiliginous area on the lower legs and feet of a patient. Note the minimal repigmentation on the feet and ankles. Patient was treated with narrow band UVB alone. Photographs were taken after an interval of 12 months.

depigmented areas of the skin, and occasional phototherapy-induced erythema, no major side effects were seen.

It has been reported that folic acid and vitamin B12 may play an indirect role in repigmentation. Both substances have been indicated as being able to supplement tyrosine and methionine deficiencies, which have been regarded as possible mechanisms for depigmentation in vitiligo and pigmentary dilution, as seen in homocysteinuria (21). Others report possible deficiencies of folic acid and/or vitamin B12 in vitiligo patients (18, 20), but recently, in a large controlled study, Kim et al. did not find any difference in serum levels compared with a normal control group (19). This is in concordance with previous findings by Juhlin & Olsson (21). We therefore decided not to measure serum levels of these compounds in our patients.

The study by Juhlin & Olsson showed an improvement of vitiligo with solar UV exposure when combined with vitamin B12 and folic acid (21). This study, however, did not include a control group and was conducted without standardized UV exposure.

The present study reconfirmed the efficacy of narrow band UVB phototherapy in vitiligo but did not show any advantage from adding vitamin B12 and folic acid.

A possible explanation for the discrepancy between the studies could be that we used an optimal dose of narrow band UVB for a long period of time, which, owing to its high efficacy, hides any effect of vitamin B12 and folic acid, which are thus not needed.

ACKNOWLEDGEMENT

We express our thanks to Orthica B.V. for supplying the vitamin B12 tablets.

REFERENCES

- Hann SK, Chung HS. historic view of vitiligo in Korea. *Int J Dermatol* 1997; 36: 313–315.
- Lee S. Vitiligo auf ein historischen Porträt. *Hautarzt* 1982; 33: 335–336.
- Singh G, Ansari Z, Dwivedi RN. Letter: vitiligo in ancient Indian medicine. *Arch Dermatol* 1974; 109: 913.
- Benedetto AV. The psoralens. An historical perspective. *Cutis* 1977; 20: 469–471.
- Bethea D, Fullmer B, Syed S, Seltzer G, Tian J, Rischko C, et al. Psoralen photobiology and photochemotherapy: 50 years of science and medicine. *J Dermatol Sci* 1999; 19: 78–88.
- Grimes PE. Psoralen photochemotherapy for vitiligo. *Clin Dermatol* 1997; 15: 921–926.
- Westerhof W, Nieuweboer-Krobotova L. Treatment of vitiligo with UV-B radiation vs topical psoralen plus UV-A [see comments]. *Arch Dermatol* 1997; 133: 1525–1528.
- Njoo MD, Bos JD, Westerhof W. Treatment of generalized vitiligo in children with narrow-band (TL-01) UVB radiation therapy. *J Am Acad Dermatol* 2000; 42: 245–253.
- Schallreuter KU, Wood JM, Berger J. Low catalase levels in the epidermis of patients with vitiligo [see comments]. *J Invest Dermatol* 1991; 97: 1081–1085.
- Schallreuter KU, Wood JM, Lemke KR, Levenig C. Treatment of vitiligo with a topical application of pseudo-catalase and calcium in combination with short-term UVB exposure: a case study on 33 patients [see comments]. *Dermatology* 1995; 190: 223–229.
- Antoniou C, Schulpis H, Michas T, Katsambas A, Frajisi N, Tsagaraki S, et al. Vitiligo therapy with oral and topical phenylalanine with UVA exposure. *Int J Dermatol* 1989; 28: 545–547.
- Camacho F, Mazuecos J. Treatment of vitiligo with oral and topical phenylalanine: 6 years of experience [letter]. *Arch Dermatol* 1999; 135: 216–217.
- Cormane RH, Siddiqui AH, Westerhof W, Schutgens RB. Phenylalanine and UVA light for the treatment of vitiligo. *Arch Dermatol Res* 1985; 277: 126–130.
- Siddiqui AH, Stolk LM, Bhaggoe R, Hu R, Schutgens RB, Westerhof W. L-phenylalanine and UVA irradiation in the treatment of vitiligo. *Dermatology* 1994; 188: 215–218.
- Lerner AB, Fitzpatrick TB. Biochemistry of melanin formation. *Physiol Rev* 1950; 30: 91–126.
- Schallreuter KU, Wood JM, Pittelkow MR, Gutlich M, Lemke KR, Rodl W, et al. Regulation of melanin biosynthesis in the human epidermis by tetrahydrobiopterin. *Science* 1994; 263: 1444–1446.
- Schallreuter KU, Wood JM, Ziegler I, Lemke KR, Pittelkow MR, Lindsey NJ, et al. Defective tetrahydrobiopterin and catecholamine biosynthesis in the depigmentation disorder vitiligo. *Biochim Biophys Acta* 1994; 1226: 181–192.
- Banerjee AK, Banerjee DK, Chaudhury DS. Serum vitamin B12 level in vitiligo – a preliminary study. *Bull Calcutta Sch Trop Med* 1970; 18: 73–75.
- Kim SM, Kim YK, Hann SK. Serum levels of folic acid and vitamin B12 in Korean patients with vitiligo. *Yonsei Med J* 1999; 40: 195–198.
- Montes LF, Diaz ML, Lajous J, Garcia NJ. Folic acid and vitamin B12 in vitiligo: a nutritional approach. *Cutis* 1992; 50: 39–42.
- Juhlin L, Olsson MJ. Improvement of vitiligo after oral treatment with vitamin B12 and folic acid and the importance of sun exposure. *Acta Derm Venereol* 1997; 77: 460–462.
- Kim HY, Kang KY. Epidermal grafts for treatment of stable and progressive vitiligo. *J Am Acad Dermatol* 1999; 40: 412–417.
- Nieuweboer-Krobotova L, Westerhof W. Treatment of vitiligo with UVB (311 nm) vs topical PUVA. *Ned Tijdschr Derm Ven* 1997; 7: 95–97.
- Orecchia G, Perfetti L. Photochemotherapy with topical khellin and sunlight in vitiligo. *Dermatology* 1992; 184: 120–123.
- Ortel B, Tanew A, Honigsmann H. Treatment of vitiligo with khellin and ultraviolet A [see comments]. *J Am Acad Dermatol* 1988; 18: 693–701.
- Scherschun L, Kim JJ, Lim HW. Narrow-band ultraviolet B is a useful and well-tolerated treatment for vitiligo. *J Am Acad Dermatol* 2001; 44: 999–1003.