

Cutaneous Necrosis after Subcutaneous Injection of Polyethylene-Glycol-modified Interferon alpha

Hjalmar Kurzen, Detlef Petzoldt, Wolfgang Hartschuh and Uta Jappe

Department of Dermatology, University of Heidelberg, Voss-str.2, DE-69115 Heidelberg, Germany.

E-mail: Hjalmar_Kurzen@med.uni-heidelberg.de

Accepted April 19, 2002.

Sir,

Interferon- α -2b has been shown to be effective in the treatment of hepatitis C and malignant melanoma (1, 2). In order to improve treatment comfort and efficacy, polyethylene glycol (PEG) modification of interferon- α -2b has recently been introduced. Injection frequency can thus be reduced from 3 times a week to once a week. We report the development of a cutaneous necrosis (embolia cutis medicamentosa) at the injection site after subcutaneous injection of PEG-modified interferon- α -2b in 2 patients with hepatitis C.

CASE REPORT

Patient 1

A 44-year-old man with hepatitis C had been receiving treatment with PEG-modified interferon- α 2b (PegIntron[®] 100 μ g) subcutaneously once a week since September 2000. The treatment was well tolerated and without any major side effects. In June 2001, the patient developed a painful reddish-brown deep infiltrate, measuring 1.5 \times 1 cm in diameter, at the injection site on the left abdominal wall, with irregular, but well-marked demarcation like a spark or "blitz" (Fig. 1). One week later the skin overlying the infiltrate had turned dark brown and was painful. The necrosis was surgically removed and the ulcer left to heal using hydrocolloid dressings. The ulcer healed after 4 weeks.

Interferon treatment could be continued without modification and was well tolerated. However 2 months later, the patient again developed a painful lesion, this time on the right abdominal wall shortly after a PegIntron[®] injection. Topical heparin ointment and oral NSAIDs were ineffective and the lesion was therefore removed surgically, sutured and healed without complications.

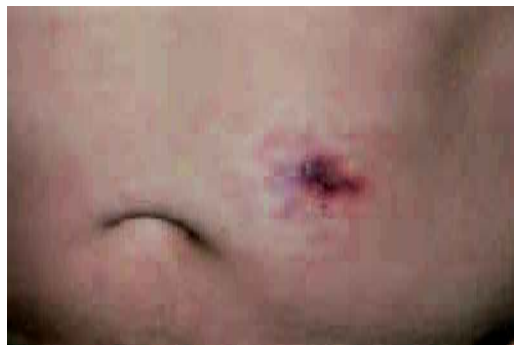

Fig. 1. One week after injection of pegylated interferon- α -2b, the injection site shows a well-demarcated brownish-red surface, 1.5 \times 1 cm in size, overlying a deep, tender infiltrate. Typical "blitz figures" surround the injection site.

Laboratory examinations revealed leukopenia and anemia, although thrombocytes, electrolytes, liver enzymes, urea and creatinine were within normal range.

A skin biopsy was taken from the inflammatory margin of the first lesion. Microscopic examination revealed dilatation of the vessels with extravasation of erythrocytes, but no signs of vasculitis. The epidermis showed an almost complete necrosis of the basal layer (Fig. 2a).

The second site was removed surgically before complete necrosis had occurred. The epidermis and upper parts of the dermis were necrotic in a wedge-shaped central part surrounded by vasodilatation. Some of the periadnexial small vessels were partly occluded due to endothelial swelling. Lymphocytes were found perivascularly and around the sweat glands. Occlusion of arterial vessels or larger veins was not observed.

Patient 2

A 35-year-old man with hepatitis C developed a painful 2 \times 3 cm red infiltrate, surrounded by typical "blitz figures" at the injection site of PEG-modified interferon- α 2b. Prior injections had been well tolerated. The infiltration was removed surgically, followed by normal healing. The treatment with

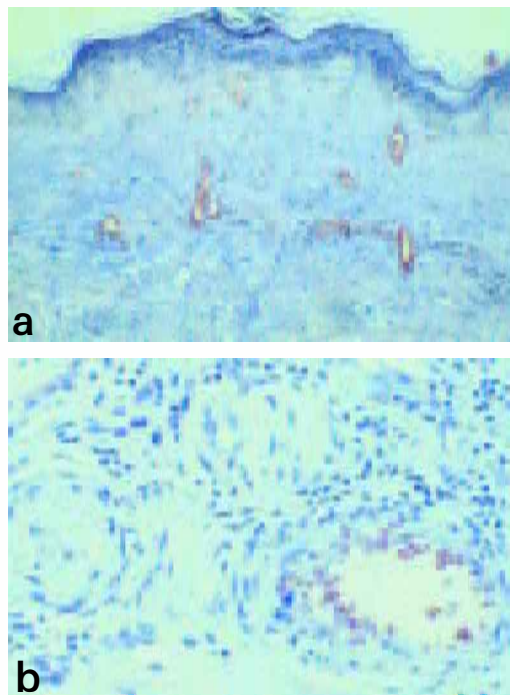


Fig. 2. (a) Almost complete necrosis of the epidermal basal layer (patient 1). The superficial vessels are dilated and filled with erythrocytes (\times 50). (b) Small arterioles in the deeper dermis are occluded while accompanying veins are widely dilated (patient 2) (\times 325); H&E staining.

PEG-modified interferon- α -2b could be continued without further complications. Laboratory examinations were within normal range.

Histological examination showed a superficial erosion of the epidermis and a subepidermal necrosis of the collagenous soft tissue. The blood vessels were dilated and filled with erythrocytes. The adnexal structures were surrounded by a few lymphocytes, histiocytes and neutrophils. In the deeper dermis, small arterioles were completely occluded, while accompanying venules were widely dilated (Fig. 2b). A major vein in the deep dermis showed an almost complete occlusion by thrombotic material. There were no signs of vasculitis.

DISCUSSION

Cutaneous necroses after accidental intra-arterial injections were first described 80 years ago and seen as side effects in treating syphilis with bismuth (3, 4). Later, the term "embolia cutis medicamentosa" or Nicolau syndrome (5) became widely accepted, referring to painful erythematous, irregular but well-marked swellings after intramuscular injection of drugs into the gluteal area. Apart from bismuth, drugs such as benzathine penicillin, other antibiotics, anti-rheumatic drugs, phenobarbital, lidocaine, steroids, chlorpromazine and mercury can cause this syndrome (6).

So far, embolia cutis medicamentosa after subcutaneous injection has only been described for heparin and interferon- α . While in the case of heparin a true immunologic or allergic reaction can be found (7), interferon- α apparently did not lead to an allergic reaction. The cases of embolia cutis medicamentosa after interferon- α injection reported elsewhere (8–10) and our cases are characterized by pain as the main symptom and development of cutaneous ulcerating necrosis after subcutaneous injection of interferon- α . A watery solution of the peptide interferon- α induced the changes. In our patients we utilized the newly developed polyethylene-glycol modified ("pegylated") interferon- α -2b (PegIntron[®]). PegIntron has a molecular weight of approximately 12 kD, is resorbed more slowly and therefore remains in the circulation longer than conventional interferon- α . Small nodules and pustules have frequently been reported after injection of PEG-modified interferon. There has been one report of repeatedly occurring cutaneous ulcerations after the injection of "pegylated" interferon. However, in that case, erythematous macules and nodules developed after each injection, suggesting a different pathomechanism, e.g. an "arthus reaction" (11). It is conceivable that embolization of small arteries, which is the most likely mechanism for the development of embolia cutis medicamentosa, is induced by crystals of undissolved interferon. The other possibilities are vascular occlusion caused by local persisting vasospasms or vascular occlusion due to endothelial damage by periarterial-, transarterial- or intramural injections leading to local activation of the coagulation system and subsequent thrombosis (10, 12).

Microscopically, necrotizing vasculitis with lymph-

ocytic infiltrates and karyorrhexis has been described. Vessel walls showed fibrinoid necrosis and thrombotic occlusion of the vessel lumina with progression of vascular and perivascular necrosis (6). In our patients, we did not detect any signs of vasculitis. In patient 2, we were able to examine deeper dermal and subcutaneous vessels because the affected skin tissue had been removed. Occlusion of bigger veins and small arterioles by thrombotic material could be demonstrated. In animal studies, embolia cutis medicamentosa could only be reproduced by direct intra-arterial injection of different drugs, but not via periarterial or intramuscular injections (14).

While polyethylene glycol might lead to unspecific inflammatory reactions, the most likely mechanism for the development of the reported skin necrosis is the occlusion of an artery, i.e. ischemia. This is in concordance with the pain that was observed during the development of the necrosis.

In treating embolia cutis medicamentosa, we were able to compare three different modalities. In patient 1 the first necrosis was removed and the wound was left to secondary healing. This resulted in prolonged morbidity. The second necrosis in patient 1 was treated topically with heparin ointment and oral NSAIDs, which did not prevent further demarcation and the cutaneous necrosis had to be removed surgically. In patient 2, the painful infiltrate was removed before complete necrosis had occurred, resulting in immediate pain relief and primary wound healing, without complications. We conclude, therefore, that surgical treatment with primary wound healing is the treatment of first choice in embolia cutis medicamentosa.

REFERENCES

1. Zein NN. Experimental and emerging therapies for chronic hepatitis C virus infection. *Expert Opin Invest Drugs* 2000; 10: 1457–1469.
2. Eggermont AM, Keilholz U, Testori A, Cook M, Lienard D, Ruiter DJ. The EORTC melanoma group translational research program on prognostic factors and ultrastaging in association with the adjuvant therapy trials in stage II and stage III melanoma. European Organization for Research and Treatment of Cancer. *Ann Surg Oncol* 2001; 8 Suppl 9: 38S–40S.
3. Freudenthal W. Lokales embolisches Bismogenol-Exanthem. *Arch Dermatol Syph* 1924; 147: 155–160.
4. Juliusberg F. Nebenwirkungen der Wismuthbehandlung. In: Jadassohn J (Hrsg) *Handbuch der Haut- und Geschlechtskrankheiten*, Bd XIII. Berlin: Springer, 1928: 479–482.
5. Nicolau S. Dermite livédoïde et gangréneuse de la consécutive aux injections intra-musculaires dans la syphilis. A propos d'un cas d'embolie artérielle bismuthique. *Ann Mal Vénér* 1925; 321–329.
6. Köhler LD, Worret WI, Hofmann H. Atypische zosteriforme segmentale Embolia cutis medicamentosa. *Hautarzt* 1997; 48: 492–495.
7. Shelley WB, Sayen JJ. Heparin necrosis: an anticoagulant-

- induced cutaneous infarct. *J Am Acad Dermatol* 1982; 7: 674–677.
8. Rasokat H, Bendick C, Wemmer U, Steigleder GK. Aseptische Hautnekrose nach subkutaner Injektion von Interferon- α . *Dtsch med Wschr* 1989; 114: 458–560.
 9. Sickler JB, Simmons RA, Cobb DK, Sherman KE. Cutaneous necrosis associated with interferon alpha-2b. *Am J Gastroenterol* 1998; 93: 463–464.
 10. Christian B, Derrienic X, Aymard JP. Nécrose cutanée locale après injection d'interféron alpha. *La Presse médicale*. 1–8 Mai 1993; 22: 783.
 11. Heinzerling L, Dummer R, Wildberger H, Burg G. Cutaneous ulceration after injection of polyethylene-glycol-modified interferon-alpha associated with visual disturbances in a melanoma patient. *Dermatol* 2000; 201: 154–157.
 12. Müller-Vahl H. Aseptische Gewebsnekrose: eine schwerwiegende Komplikation nach intramuskulärer Injektion. *Dtsch Med Wochenschr* 1984; 109: 786–792.
 13. Bork K. Cutaneous side effects of drugs. Philadelphia: WB Saunders, 1988: 364–369.
 14. Albrecht KH, Littmann K, Richter HJ, Eigler FW. Animal experiment studies of embolia cutis medicamentosa. *Langenbecks Arch Chir* 1984; 362: 17–23.

CD8-Positive Primary Cutaneous Anaplastic Large Cell Lymphoma with a Fair Prognosis

Mizuho Fukunaga, Taro Masaki, Masamitsu Ichihashi and Masato Ueda

Division of Dermatology, Clinical Molecular Medicine, Faculty of Medicine, Kobe University Graduate School of Medicine, 7-5-1 Kusunoki-cho, Chuo-ku, Kobe 650-0017, Japan. E-mail: mueda@med.kobe-u.ac.jp

Accepted April 19, 2002.

Sir,

Anaplastic large cell lymphoma (ALCL), also called Ki-1 lymphoma, is characterized by the proliferation of predominantly large neoplastic lymphoid cells with strong expression of the cytokine receptor CD30 and a characteristic growth pattern (1). A previous study reported that primary cutaneous CD30-positive (CD30+) cases of ALCL, regardless of their morphologic classification (anaplastic or non-anaplastic), can be considered as distinct types of cutaneous T-cell lymphoma (2). Most cases of ALCL have been reported to be CD4 positive (CD4+). We present here a case of a primary cutaneous ALCL with a CD8-positive (CD8+) phenotype, showing fairly good prognosis.

CASE REPORT

In February 2001 a 68-year-old man presented with a 1-month history of skin tumor on his right forearm (Fig. 1). The tumor had developed rapidly and presented as a solid, reddish-violet, circumscribed, 4.3 × 3.9 cm mass. In the center of the tumor there was a 1.4 × 1.9 cm ulcer. There was no lymphadenopathy.

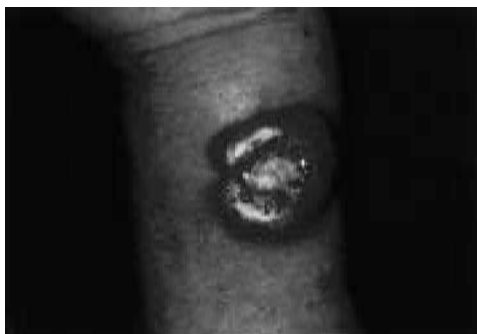

Fig. 1. Clinical appearance of the tumor on the patient's right wrist.

Laboratory investigations were almost normal, except for a mild renal dysfunction (creatinine clearance = 40 ml/min/1.73 m²). No antibodies were detected against the human T-cell leukemia virus-1 (HTLV-1) or human immunodeficiency virus (HIV). The bone marrow did not show tumor cell involvement. A ⁶⁷Ga whole body scan showed a hot spot corresponding to the mass on the patient's right forearm. No evidence of lymphadenopathy or tumor mass was found by computerized tomography of his chest and abdomen and magnetic resonance imaging of his head and neck.

An incisional biopsy was performed. Histologically, the epidermis was slightly infiltrated by mononuclear cells. Irregularly shaped large cells with large atypical (often chromatin-poor, horseshoe-shaped) nuclei, prominent nucleoli and ample cytoplasm comprised the infiltrate, which extended from the papillary dermis to the subcutaneous fat (Fig. 2a). Medium-sized lymphoid cells with occasional atypical nuclei mingled with large cells were also observed. Adjacent areas showed a predominance of inflammatory cells consisting of normal lymphocytes and histiocytes. The tumor cells from the specimen were studied using a panel of monoclonal antibodies and they expressed leukocyte common antigen, CD2, CD3, CD5, CD7, CD8 (Fig. 2b), CD30, CD45RO, CD68 and T-cell restricted intracellular antigen-1 (TIA-1). The cells tested negative for CD1a, CD4, CD16, CD20, CD56, CD57, anaplastic lymphoma kinase and TdT.

DNA hybridization analysis was performed using the T-cell antigen receptor gene (C β) probe, as described elsewhere (3), and rearranged bands were detected, indicating the proliferation of clonal T lymphocytes.

After the biopsy, a partial spontaneous resolution of the tumor was observed. The patient was treated for 20 days with local radiation therapy at 2 Gy per day for a total dose of 40 Gy, after which the tumor disappeared