

LETTERS TO THE EDITOR

Efficacy and Tolerability of Montelukast as a Therapeutic Agent for Severe Atopic Dermatitis in Adults

Nettis Eustachio¹, Pannofino Alessandro¹, Fanelli Margherita², Ferrannini Antonio¹ and Alfredo Tursi¹¹Department of Allergy and Clinical Immunology, Padiglione Chini – Policlinico, Piazza Giulio Cesare, IT-70124 Bari and²Section of Statistics, University of Bari, Italy. E-mail: e.nettis@allergy.uniba.it

Accepted April 2, 2002.

Sir,

The pathogenesis of atopic dermatitis (AD) is only partly understood. Evidence supports the potential role of soluble mediators as leukotrienes (LTs) (1). Drugs that selectively inhibit the formation or action of LTs have been introduced as a new form of anti-inflammatory therapy in asthma. Montelukast is an antileukotriene agent known as CysLT1 receptor antagonist. Cysteinyl LTs (LTC₄, LTD₄, LTE₄) are potent smooth muscle constrictors, and contribute to the onset of inflammation by their ability to cause plasma extravasation and eosinophil recruitment (2). The objective of our study was to evaluate the efficacy and tolerability of montelukast as a therapeutic agent for severe AD in adults.

MATERIAL AND METHODS

We enrolled 20 adult male patients with severe AD according to the SCORAD index (severe AD: mean objective score > 40) (3). Their ages ranged from 18 to 28 years (mean age 22 ± 3.7). One month before treatment, the patients were asked to discontinue all medication except emollients. The study was approved by the ethics committee and subjects signed an informed consent form to participate in the study. Exclusion criteria were: pregnancy, pregnancy potential and current lactation; a history of liver disease; allergy to montelukast or cross-reacting medication; use of phenobarbital, phenytoin or rifampicin.

Subjects were randomized into two groups of 10 to receive montelukast 10 mg or placebo for 6 weeks in a double-blind study. Furthermore, during the study, all subjects were not allowed other treatment for AD. Efficacy was assessed by SCORAD index and subjective symptoms were evaluated separately at baseline, and after 3 and 6 weeks. The SCORAD index combines objective signs (extent and intensity of lesions) and subjective (daytime pruritus and sleep loss) criteria. Evaluations were made at each visit by the same investigator for each patient. Blood tests were performed for total blood cell count and blood chemistry (aspartate transaminase, total bilirubin, creatinine and urea). Baseline mean values were compared using Student's t-test for unpaired samples. The efficacy of the two treatments at different times was evaluated using a split-plot analysis of variance (ANOVA). Comparison between t₀ and t₂ (time of treatment at baseline and end of the study) was evaluated with Student's t-test for unpaired samples.

RESULTS

All patients completed the study. There was a significant decrease in disease activity in the montelukast group

(20% reduction) compared to the placebo group measured by SCORAD index, as shown in Fig. 1. The combined score of daytime pruritus and sleep loss remained similar throughout the study and was not statistically significant between the two treatments ($F = 0.08$ $p = 0.92$) and the different times of observation ($F = 1.95$ $p = 0.18$). The blood-chemistry tests conducted at the end of treatment revealed no changes in any of the studied patients and no adverse effects were observed by the investigator or reported by the patient, thereby confirming the tolerability of montelukast.

DISCUSSION

Montelukast is generally a safe drug during long-term treatment; side effects are minimal (4). Indeed, in our study montelukast was well tolerated, confirming observations by other authors of the safety of this drug (4–6). This could be particularly relevant for patients affected with AD who may need treatment for long periods of time. The anti-inflammatory potential of anti-LTs in asthma has been confirmed in a number of studies (7, 8). The role of the LTs in AD remains unclear. A prolonged elevation of the urinary levels of LTE₄ has

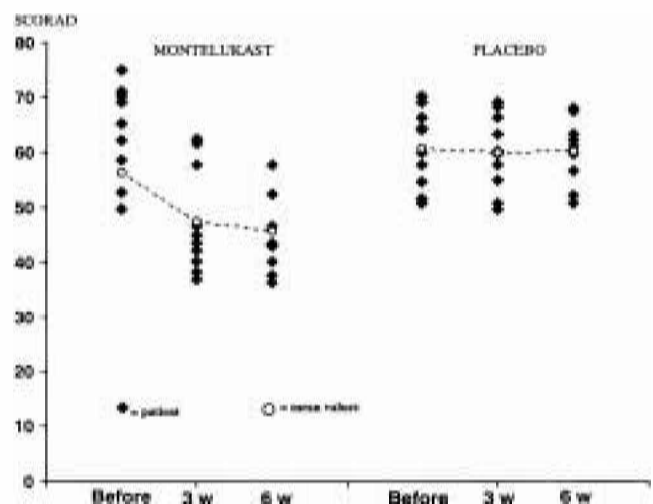


Fig. 1. Analysis of variance (ANOVA) before and after 3 and 6 weeks of treatment shows a significant difference in SCORAD reduction between times of observation ($F = 54.94$ $p = 0.0001$) and between the two treatments ($F = 6.41$ $p = 0.021$), significant interaction between treatment and time of observation: $F = 46.79$ $p = 0.0001$.

been documented in patients with AD compared with healthy individuals (9). Eosinophilic infiltration of AD lesions, as well as increasing eosinophil counts in the peripheral blood, are frequently seen in patients with AD (10). In other studies, patients with AD have shown improvement with LT inhibitors (11, 12). The present results basing on SCORAD index show a modest but significant improvement of AD in adult patients treated with montelukast therapy as compared with placebo, demonstrating that montelukast can be considered a safe and effective treatment in patients with severe AD. This is in agreement with Yanase & David-Bajar, who found a significant reduction of symptoms in subjects with the diagnosis of mild to moderate AD and treated with montelukast therapy (11). Indeed, the favourable response to montelukast may reflect the involvement of LTs in the pathogenesis of AD. It could also suggest that leukotriene antagonists have a potential role in the treatment of inflammatory skin diseases. Additional larger studies are needed to evaluate the role of leukotriene antagonists in the treatment of AD.

ACKNOWLEDGEMENT

We thank Dr. Giovanni Strippoli for his collaboration.

REFERENCES

1. Fauler J, Neumann C, Tsikas D, Frolich JC. Enhanced synthesis of cysteinyl leukotrienes in atopic dermatitis. *Br J Dermatol* 1993; 128: 627–630.

2. Drazen JM, Austen KF. Leukotrienes and airway responses. *Am Rev Resp Dis* 1987; 136: 985–998.
3. Kunz B, Oranje AP, Labreze L, Stalder JF, Ring J, Taieb A. Clinical validation and guidelines for the SCORAD Index: Consensus report of the European Task Force on Atopic Dermatitis. *Dermatology* 1997; 195: 10–19.
4. Storms W, Michele MT, Knorr B, Noonan G, Shapiro G, Zhang J, et al. Clinical safety and tolerability of montelukast, a leukotriene receptor antagonist, in controlled clinical trials in patients aged ≥ 6 years. *Clin Exp Allergy* 2001; 31: 77–87.
5. Schoors DF, De Smet M, Reiss T, Margolskee D, Cheng H, Larson P, et al. Single dose pharmacokinetics, safety and tolerability of MK-0476, a new leukotriene D₄-receptor antagonist, in healthy volunteers. *Br J Clin Pharmacol* 1995; 40: 277–280.
6. Nettis E, Dambra P, D'Oronzio L, Loria MP, Ferrannini A, Tursi A. Comparison of montelukast and fexofenadine for chronic idiopathic urticaria. *Arch Dermatol* 2001; 137: 99–100.
7. Calhoun WJ, Williams KL, Simonson SG, Lavins BJ. Effect of zafirlukast on airway inflammation after segmental allergen challenge in patients with mild asthma. *Am J Respir Critic Care Med* 1997; 155: 662.
8. Pizzichini E, Leff JA, Reiss TF, Hendeles L, Boulet LP, Wei LX, et al. Montelukast reduces airway eosinophilic inflammation in asthma: a randomized, controlled trial. *Eur Respir J* 1999; 14: 12–18.
9. Sansom JE, Taylor GW, Dollery CT, Archer CB. Urinary leukotriene E₄ levels in patients with atopic dermatitis. *Br J Dermatol* 1997; 136: 790–791.
10. Hanifin JM. Atopic dermatitis. *J Allergy Clin Immunol* 1984; 73: 211–222.
11. Yanase DJ, David-Bajar K. The leukotriene antagonist montelukast as a therapeutic agent for atopic dermatitis. *J Am Acad Dermatol* 2001; 44: 89–93.
12. Carucci JA, Washenik K, Weinstein A, Shupack J, Cohen D. The leukotriene antagonist zafirlukast as a therapeutic agent for atopic dermatitis. *Arch Dermatol* 1998; 134: 785–786.