

## CLINICAL REPORT

# Benign Degos' Disease Developing During Pregnancy and Followed for 10 Years

THOMAS BOGENRIEDER, MARION KUSKE, MICHAEL LANDTHALER and WILHELM STOLZ

*Department of Dermatology, University of Regensburg, Regensburg, Germany*

Degos' disease, or malignant atrophic papulosis, is a rare and often fatal multisystem vasculopathy of unknown etiology. The cutaneous manifestations comprise erythematous papules, which heal to leave scars with a pathognomonic central porcelain-white atrophic area and a peripheral telangiectatic rim. Involvement of the gastrointestinal tract is observed in 50% of cases, with intestinal perforation being the most common cause of death. Other organ systems can also be affected; 20% of cases involve the central nervous system. Systemic manifestations usually develop from weeks to years after onset of skin lesions or, in rare instances, may precede skin lesions. In the patient with Degos' disease reported in this article, the characteristic skin lesions developed during pregnancy, a precipitating event not previously reported. She has survived an unusually long time (10 years) without visceral or neurological involvement, despite florid cutaneous lesions. Moreover, we could detect the presence of antiphospholipid antibodies, the significance of which are currently unclear. These observations therefore confirm that there may be a strictly cutaneous form of Degos' disease with a favourable prognosis. *Key words: antiphospholipid antibodies; Degos' disease; malignant atrophic papulosis; porcelain-white scars; pregnancy.*

(Accepted March 25, 2002.)

Acta Derm Venereol 2002; 82: 284–287

Thomas Bogenrieder, The Wistar Institute, 3601 Spruce St., Philadelphia, PA 19104, USA. E-mail: bogenrieder@wistar.upenn.edu

Degos' disease, or malignant atrophic papulosis (MAP), is a rare and frequently fatal disseminated occlusive vasculopathy of unknown etiology. Köhlmeier (1) reported the first case in 1941 (hence also the name Köhlmeier-Degos disease), which he believed was related to Buerger's disease (thrombangiitis obliterans), but Degos *et al.* (2) reported another case as a distinctive entity a year later. The clinical hallmark of this disease is a cutaneous eruption on the trunk and extremities. The lesions begin as umbilicated papules and then quickly evolve into characteristic "porcelain-white" atrophic scars surrounded by an erythematous telangiectatic border (3). The atrophic scars represent infarction

due to progressive occlusion of middle- and small-sized arteries and veins (4).

Fifty percent of cases involve the gastrointestinal tract, making this the most frequent systemic complication. Intestinal perforation is the most common cause of death from Degos' disease (5, 6). Nervous system involvement, which occurs in 20% of cases, may include multiple cerebral infarcts, venous sinus thromboses and subdural hematomas (6, 7).

We describe a patient with onset of the pathognomonic skin lesions during pregnancy. To our knowledge, this is the first report of this association. The patient with Degos' disease reported here is also of special interest because she has been free of visceral, neurologic, or any other systemic involvement for 10 years despite the presence of florid skin lesions.

## CASE REPORT

In January 1997, a 26-year-old woman presented with approximately 30 atrophic porcelain-white scars surrounded by a rim of hemorrhagic erythema disseminated on her trunk and extremities (Fig. 1). The lesions had initially appeared during her first pregnancy 5 years earlier. She had shown small erythematous papules of 2–5 mm, which began to umbilicate over the next several days and did not hurt or itch. The appearance of the skin lesions upon admittance in our department can be seen in Fig. 2. Physical examination was otherwise without pathological findings and the mucous membranes were not involved. The patient had no significant past medical or family history, and otherwise enjoyed good health. In particular, she did not complain about gastrointestinal or neurological symptoms. There were no pathologic findings on ophthalmologic examination: Visual acuity was 20/20 in both eyes. Intraocular pressures were 16 and 17 mmHg, respectively. Slitlamp and fundus examination revealed no abnormality in either eye. Neurologic examination was also without pathologic findings: There was normal sensation with no signs of paresis. Cranial nerve examination and tendon reflexes were normal with negative Babinski signs.

A biopsy specimen from a characteristic lesion on the thigh revealed an atrophic epidermis with slight parakeratosis. The underlying dermis contained a typical wedge-shaped area of necrosis, relatively acellular with considerable mucin between collagen fibers. The vessels

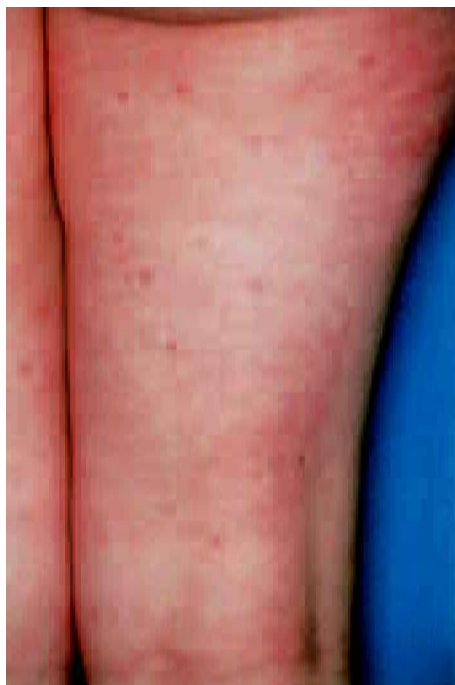

Fig. 1. Typical "porcelain-white" skin lesions occurring in large numbers on the calves of the patient at varying stages of development.

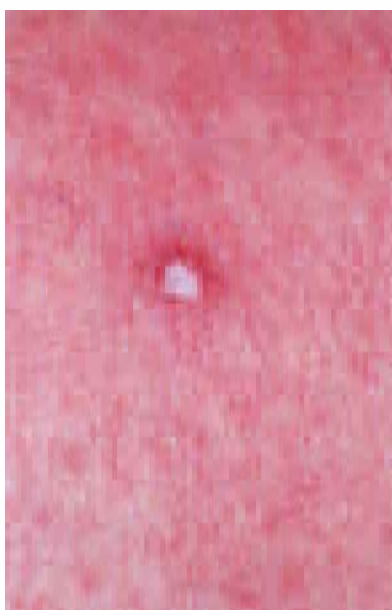


Fig. 2. Typical skin lesion of Degos' disease: umbilicated papule with the characteristic glistening porcelain-white center and a rim of erythema.

adjacent and deep to the infarct showed a dense perivascular infiltrate. Arterioles deep to the apex of the lesion demonstrated endothelial hyperplasia and occlusion (Fig. 3). Alcian blue stain confirmed abundant dermal mucin deposition. Direct immunofluorescent testing demonstrated deposits of immunoglobulins and complement around the dermal vessels.

Initial laboratory data showed an increase in phos-

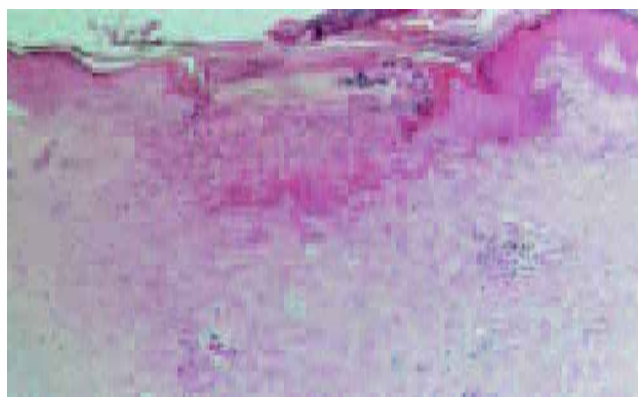


Fig. 3. Skin histologic specimen revealing typical wedge-shaped area of dermal necrosis. Vessels adjacent and deep to the infarct show a dense perivascular infiltrate. A small arteriole deep to the apex of the wedge demonstrates endothelial hyperplasia and occlusion (hematoxylin and eosin; original magnification  $\times 100$ ).

phatidylserin-IgM antibodies (27.7 U/ml; normal range  $< 15$  U/ml) but not phosphatidylserin-IgG antibodies or anticardiolipin antibodies. The following laboratory studies showed normal or negative findings: full blood count including platelet number, erythrocyte sedimentation rate, electrolytes, blood glucose, serum protein electrophoresis, serum immunoglobulins, Venereal Disease Research Laboratories (VDRL) test and fluorescent treponemal antibody absorption test (FTA-ABS), rheumatoid factor, antinuclear antibodies (ANAs, SSA/Ro, SSB/La, cANCA, pANCA), cryoglobulins, coagulation factors and complement components (C3, C4). Results of liver and renal function tests were also within normal limits.

Doppler/Duplex sonography showed no signs of occlusion or pathologic wall processes in extra- and intracranial blood vessels. Magnetic resonance imaging (MRI) was normal, with no evidence of intracranial hemorrhages or focal areas of abnormal signal. Gastroduodenoscopy as well as colonoscopy revealed no abnormalities. As the patient has since not experienced gastrointestinal or neurological symptoms, we have refrained from repeated imaging analyses or endoscopic examinations.

## DISCUSSION

Both the clinical and histopathological findings of cutaneous lesions in this patient are consistent with Köhlmeier-Degos' disease. This disease, or MAP, has been reported in the literature under a myriad of different names, including progressive arterial occlusive disease, fatal cutaneo-intestinal syndrome (8), and thrombangiitis cutaneointestinalis disseminata. Degos' disease is a rare and frequently lethal cutaneous systemic vasculopathy of unknown origin.

A marked male dominance in this disorder was evident in earlier reports (8), but more recent data suggest that

women are affected nearly as often as men (3, 9). Infants and elderly are exceptionally affected; onset is typically in the second through fourth decades with a median age of 35 years (8, 9). Eight cases of Degos' disease occurring in a familial setting have been reported (reviewed in (10)): amongst others, a woman and her son, two mothers and their respective daughters, and a mother with her five children. No other compelling evidence to suggest a genetic predisposition has been uncovered as yet. The distribution of cases has been worldwide (8, 9).

The pathognomonic skin lesions are constant and usually the first signs of Degos' disease (11). However, similar lesions that mimic Degos' disease have been described in patients with systemic lupus erythematosus (SLE) (12), progressive systemic sclerosis (13), dermatomyositis (14) and Crohn's disease (15). The exclusion of autoimmune disorders must therefore be especially rigorous. The earliest lesions are small (2–5 mm), slightly erythematous papules which begin to umbilicate over the next several days (8, 11). The lesions occur in crops of a few to several dozen, and papules at varying stages of development are characteristic. The primary lesions do not itch or hurt (11). Over the following weeks, the centers of the lesions become progressively depressed and gain a pale, glistening, porcelain-white cast (9, 11). A thin, detachable flake of overlying scale may be present, and there is often a rim of erythema or telangiectasia (8, 11). As lesions wane, the scaling and erythema gradually diminish and a varicelliform scar remains. The oral and genital surfaces are generally spared, although mucosal papules or scars resembling cutaneous lesions can be seen in rare instances (8).

Ocular involvement is present in 13%, occurring mainly on the conjunctiva but also on the sclera, episclera, retina, choroid and the optic nerve (16, 17). Systemic manifestations usually develop from weeks to years after the onset of the pathognomonic skin lesions or, in rare instances, may precede skin lesions (18). The outcome of Degos' disease is frequently fatal (11). Causes of death in this disease include sepsis from peritonitis (61%), CNS bleeding (18%) and pleural/pericardial involvement (16%) (9).

A chronic variety limited to the skin that runs a benign course has also been described (3, 19, 20). The frequency of this strictly cutaneous form, based on a review of 120 cases in the literature, has been estimated at 4% (20). However, this number is now thought to be an underestimate due to under-reporting and the failure of patients with cutaneous symptoms alone to seek medical advice (19).

The histological features have been described in great detail by other authors (11), and recently reviewed by Harvell and colleagues with special regard to the different evolutionary stages of the papules (21). Typically, there is a wedge-like zone of dermal acellular necrosis with hyperkeratosis beneath an atrophic epidermis (11).

Below the necrotic dermal zone, the lumen of one or more blood vessels is reduced by endothelial proliferation and often obstructed by a thrombus (11). Degos recognized that a lack of histological inflammation is characteristic of this condition and differentiates it from allergic vasculitides, periarteritis nodosa and various types of thrombangiitis (11).

Different therapeutic measures aimed at influencing immunosuppression and the clotting system of the patient have been suggested, but there is still no effective treatment for Degos' disease. Treatments including the use of antiplatelet drugs (22, 23), fibrinolytics (24), corticosteroids (22, 23, 25), azathioprine (22, 23, 25) and stanazolol (23) have not proved beneficial. Plasma exchange (6) has also been tried unsuccessfully.

Our patient is of particular interest for two unusual features: Firstly, she has survived an unusually long time, 10 years, without visceral or neurological involvement, despite florid cutaneous lesions. Some patients have previously been recognized with isolated skin lesions (3, 19, 20). Our findings thus support the existence of a strictly cutaneous form of Degos' disease associated with a benign course. Secondly, our observation identified a possible precipitating event for Degos' disease: This patient first developed characteristic skin lesions during pregnancy. Other precipitating events have only rarely been described in patients with Degos' disease. Reported events include a patient with AIDS (26) and another one with iatrogenic immunosuppression (27). Furthermore, antiphospholipid antibodies, which have been found in our patient as well as in a couple of more recent cases (19), could provide a link between this disorder and pregnancy as they have also been associated with recurrent fetal loss due to thrombosis (28). However, they were not detected in another case when looked for (23), and other studies looking for underlying immunological abnormalities (circulating immune complexes, autoantibodies and complement, immunofluorescence and lymphocyte transformation) have found none (29). Thus, their biological significance remains unclear.

We first considered the use of oral anticoagulants or aspirin in our patient in view of the presence of antiphospholipid antibodies. However, because of the absence of previous thromboembolic events and the absence of gastrointestinal or neurologic symptoms, it was decided not to treat. Our patient remained well despite no treatment during one of the longest reported follow-up periods hitherto reported.

## REFERENCES

1. Köhlmeier W. Multiple Hautnekrosen bei Thrombangiitis obliterans. *Arch Dermatol Syphilol* 1941; 181: 783–792.
2. Degos R, Delort J, Tricot R. Dermatite papulosquameuse atrophiante. *Bull Soc Fr Dermatol Syphiligr* 1942; 49: 148–150.

3. Su WP, Schroeter AL, Lee DA, Hsu T, Muller SA. Clinical and histologic findings in Degos' syndrome (malignant atrophic papulosis). *Cutis* 1985; 35: 131–138.
4. Molenaar WM, Rosman JB, Donker AJ, Houthoff HJ. The pathology and pathogenesis of malignant atrophic papulosis (Degos' disease). A case study with reference to other vascular disorders. *Pathol Res Pract* 1987; 182: 98–106.
5. Casparie MK, Meyer JW, van Huystee BE, Kneppelhout J, Mulder CJ. Endoscopic and histopathologic features of Degos' disease. *Endoscopy* 1991; 23: 231–233.
6. Burrow JN, Blumberg PC, Iyer PV, Hallpike JF. Kohlmeier-Degos disease: a multisystem vasculopathy with progressive cerebral infarction. *Aust NZ J Med* 1991; 21: 49–51.
7. McFarland HR, Wood WG, Drowns, BV, Meneses AC. Papulosis atrophicans maligna (Kohlmeier-Degos disease): a disseminated occlusive vasculopathy. *Ann Neurol* 1978; 3: 388–392.
8. Degos R, Delort J, Tricot R. Papulose atrophiante maligne (syndrome cutané-intestinal mortel). *Bull Mém Soc Méd Hôp Paris* 1948; 64: 803–806.
9. Magrinat G, Kerwin KS, Gabriel DA. The clinical manifestations of Degos' syndrome. *Arch Pathol Lab Med* 1989; 113: 354–362.
10. Katz SK, Mudd LJ, Roenigk HH, Jr. Malignant atrophic papulosis (Degos' disease) involving three generations of a family. *J Am Acad Dermatol* 1997; 37: 480–484.
11. Degos R. Malignant atrophic papulosis. *Br J Dermatol* 1979; 100: 21–35.
12. Dubin HV, Stawiski MA, Arbor A. Systemic lupus erythematosus resembling malignant atrophic papulosis. *Arch Intern Med* 1974; 134: 321–323.
13. Durie BGM, Stroud JD, Kahn JA. Progressive systemic sclerosis with malignant atrophic papulosis. *Arch Dermatol* 1969; 100: 575–581.
14. Tsao H, Busam K, Barnhill RL, Haynes HA. Lesions resembling malignant atrophic papulosis in a patient with dermatomyositis. *J Am Acad Dermatol* 1997; 36: 317–319.
15. Castanet J, Lacour JP, Perrin C, Rodot S, Ortonne JP. Cutaneous vasculitis with lesions mimicking Degos' disease and revealing Crohn's disease. *Acta Derm Venereol* 1995; 75: 408–409.
16. Henkind P, Clark WE 2nd. Ocular pathology in malignant atrophic papulosis. Degos' disease. *Am J Ophthalmol* 1968; 65: 164–169.
17. Sibillat M, Avril MF, Charpentier P, Offret H, Bloch-Michel E. Papulose atrophiante maligne (maladie de Degos): revue clinique. A propos d'un cas. *J Fr Ophtalmol* 1986; 9: 299–304.
18. Snow JL, Muller SA. Degos syndrome: malignant atrophic papulosis. *Semin Dermatol* 1995; 14: 99–105.
19. Farrell AM, Moss J, Costello C, Fearfield LA, Woodrow D, Bunker CB. Benign cutaneous Degos' disease. *Br J Dermatol* 1998; 139: 708–712.
20. Plantin P, Labouche F, Sassolas B, Delaire P, Guillet G. Degos' disease: a 10-year follow-up of a patient without visceral involvement. *J Am Acad Dermatol* 1989; 21: 136–137.
21. Harvell JD, Williford PL, White WL. Benign cutaneous Degos' disease: a case report with emphasis on histopathology as papules chronologically evolve. *Am J Dermatopathol* 2001; 23: 116–123.
22. Subbiah P, Wijdicks E, Muentner M, Carter J, Connolly S. Skin lesion with a fatal neurologic outcome (Degos' disease). *Neurology* 1996; 46: 636–640.
23. Leslie TA, Goldsmith PC, Thompson AJ, Dowd PM. Degos disease and spastic paraplegia. *Clin Exp Dermatol* 1993; 18: 344–346.
24. Delaney TJ, Black MM. Effect of fibrinolytic treatment in malignant atrophic papulosis. *BMJ* 1975; 3: 415.
25. Metz J, Amschler A, Henke M. Morbus Degos (Maligne atrophe Papulose). *Hautarzt* 1980; 31: 108–110.
26. Requena L, Farina C, Barat A. Degos disease in a patient with acquired immunodeficiency syndrome. *J Am Acad Dermatol* 1998; 38: 852–856.
27. Powell J, Bordea C, Wojnarowska F, Farrell AM, Morris PJ. Benign familial Degos disease worsening during immunosuppression. *Br J Dermatol* 1999; 141: 524–527.
28. Eswaran K, Rosen SW. Recurrent abortions, thrombosis and a circulating anticoagulant. *Am J Obstet Gynecol* 1985; 151: 751–752.
29. Tribble K, Archer ME, Jorizzo JL, Sanchez R, Solomon AR Jr, Gardner FH, et al. Malignant atrophic papulosis: absence of circulating immune complexes or vasculitis. *J Am Acad Dermatol* 1986; 15: 365–369.